

V.N.KARAZIN

KHARKIV NATIONAL UNIVERSITY
DEPARTMENT OF INTERNAL MEDICINE

Late Complications after Therapy in Patient with Hodgkin's Disease



Speakers : Students of 4th Course

Monu

Head of the department : Prof . M.I. Iabluchanskyi

Teacher Advisor : O. Babiy &

N. Kumpan

GOAL

The purpose of this report is to pay attention to the problem of late cardiac complications, which develop in remote (distant) period after combined therapy (beam and chemotherapy) of Hodgkin's lymphoma on example of illustrative clinical case

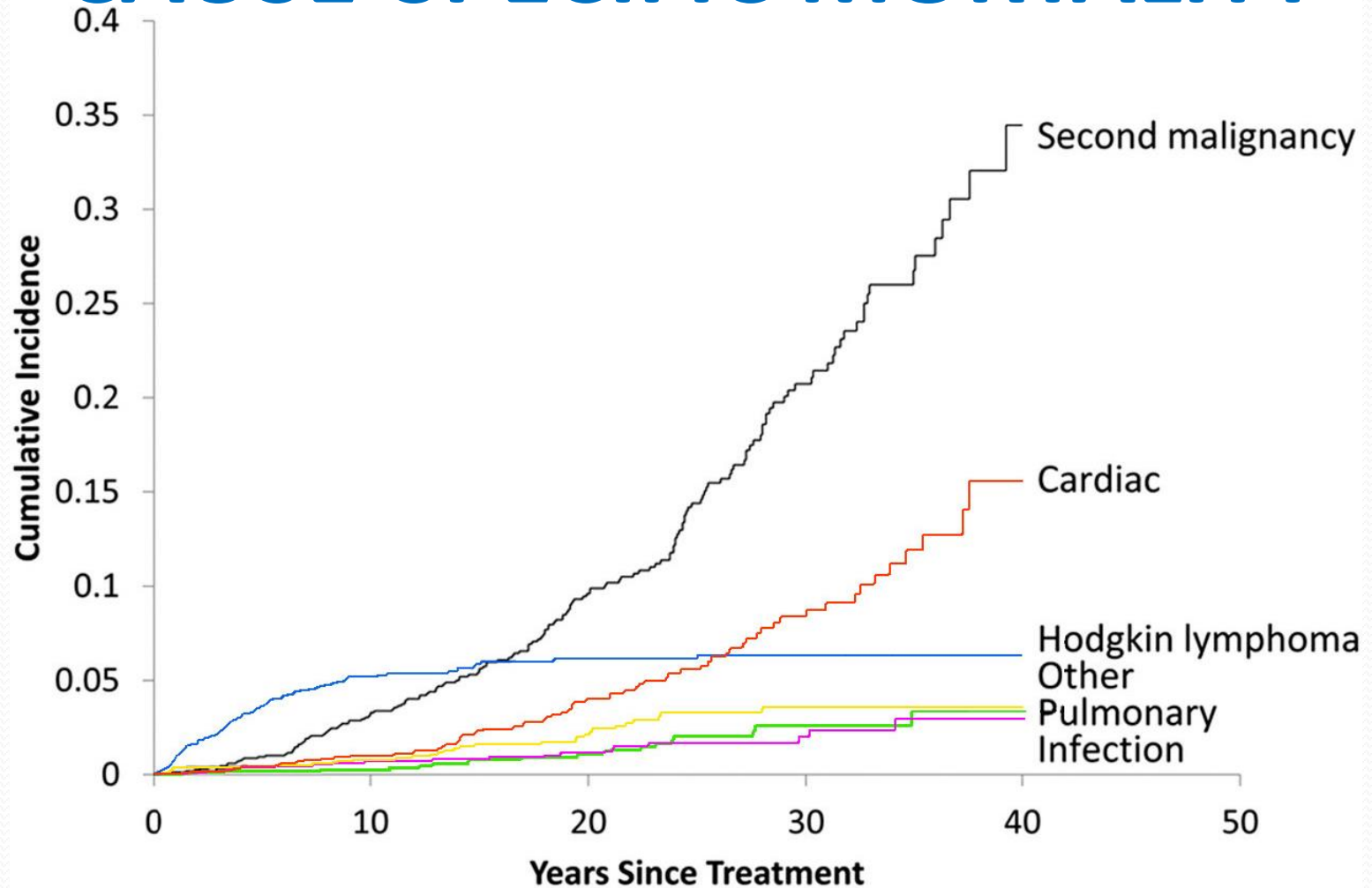
INTRODUCTION

- During the past five decades, dramatic progress has been made in the development of curative therapy for hematologic malignancies, including Hodgkin's Lymphoma
- The therapy responsible for this survival can also produce adverse long-term health-related outcomes, referred to as *late effects*, which manifest months to years after completion of cancer treatment

MOST SUBSTANTIAL LATE COMPLICATIONS AFTER TREATMENT FOR HODGKIN'S LYMPHOMA

- Second malignancies (leukemia, lung, stomach, breast, bone, colorectal cancers, etc.)
- Cardiac disease
- Pulmonary dysfunction
- Infections
- Endocrinopathy

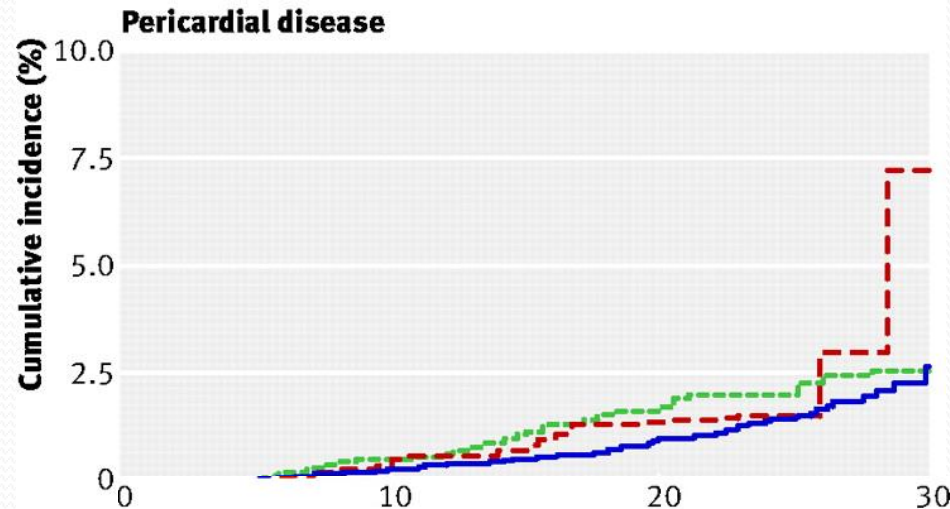
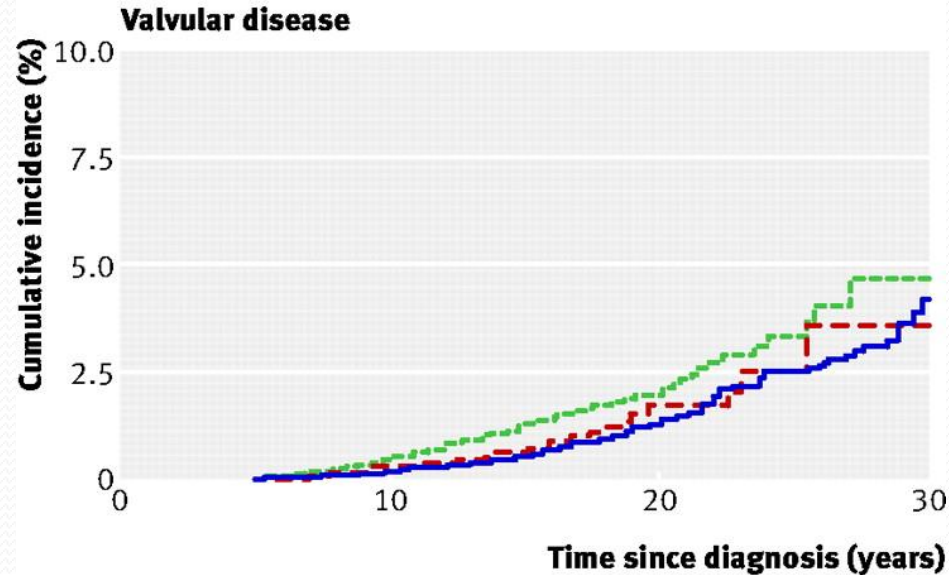
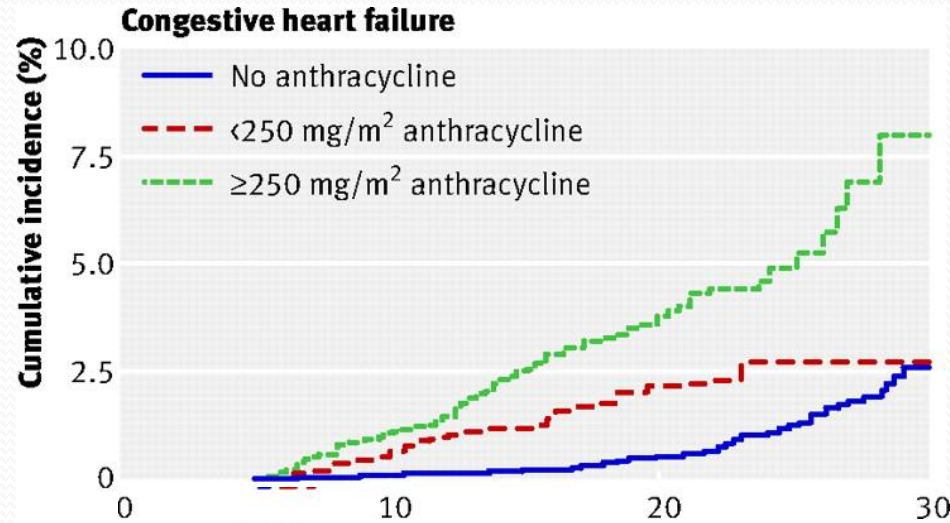
CUMULATIVE INCIDENCE OF CAUSE-SPECIFIC MORTALITY



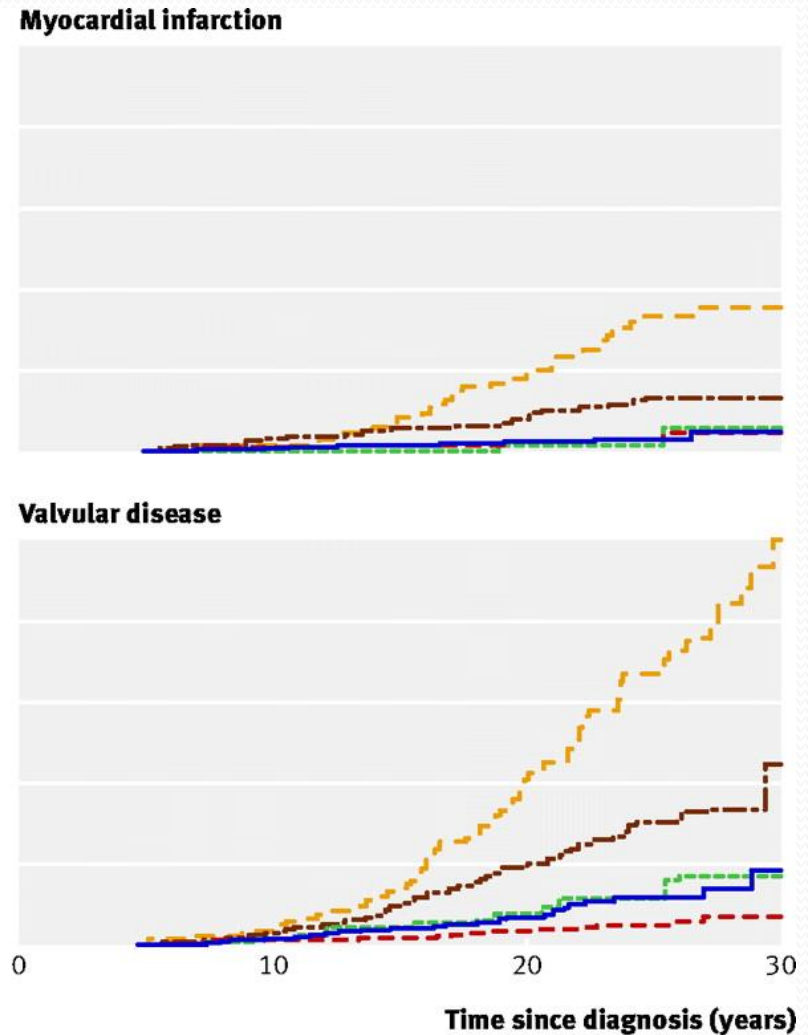
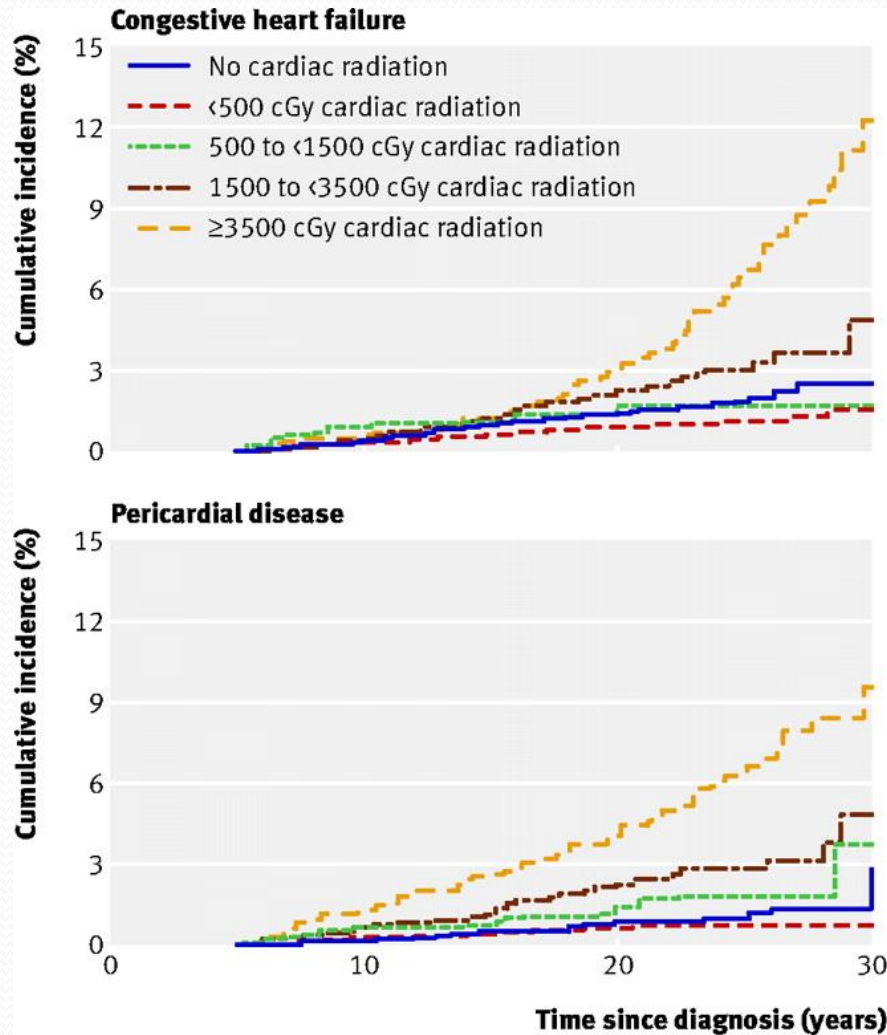
CLINICALLY SIGNIFICANT CARDIAC EVENTS

- Coronary artery disease
- Arrhythmias
- Valvular disease
- Pericardial disease

CUMULATIVE INCIDENCE OF CARDIAC DISORDERS AMONG CHILDHOOD SURVIVORS BY ANTHRACYCLINE DOSE



CUMULATIVE INCIDENCE OF CARDIAC DISORDERS AMONG CHILDHOOD SURVIVORS BY AVERAGE CARDIAC RADIATION DOSE



Bleomycine Induced Pneumofibrosis

- 0-40% patients develop pulmonary toxicity
- 11-30% patients have non-lethal pulmonary fibrosis
- 2-10% mortality

Adriamycine Induced Nephrotoxicity

30% of patients develop nephrotoxicity:
coagulation necrosis of proximal and distal
renal tubular epithelial cells and in the
collecting ducts



OUR PATIENT

37 Yr Female

COMPLAINTS

- Dyspnea during exertion (especially when going uphill or upstairs), ordinary physical activity cause breathlessness
- Edema of ankles in the evening
- Face and eyelid puffiness in the morning
- Palpitations
- Tendency to low blood pressure (85/55 mmHg)

HISTORY OF THE PRESENTING COMPLAINTS

- In 1993 *Hodgkin's Lymphoma* of mandibular, cervical, intrathoracic lymph nodes had been diagnosed
- The combination therapy had been carried out
- Chemotherapy: particular regimens and medicines patient currently do not remember
- Bilateral cervical, supra-, infraclavicular, axillar as well as mediastinal regions radiotherapy had been performed
- Since 1996 remission occurs, relapses did not observe

HISTORY OF THE PRESENTING COMPLAINTS

- Since 2013 dyspnea and ankle swelling bother the patient
- She was surveyed in cardiologic center and for the first time was established diagnosis of
“Mild pericardial effusion. Chronic congestive heart failure II FC NYHA”

It was prescribed:

SALT RESTRICTION in diet (< 3 g per day)

TORASEMIDE 5 mg in the morning and

IVABRADINE 7.5 bid

- Symptoms decreased (but not completely ceased), exercise tolerance slightly improved

HISTORY OF THE PRESENTING COMPLAINTS

- During the last month dyspnea and exercise intolerance were exacerbated, even ordinary physical activity and walking ground level less than 500m led to breathlessness
- Also palpitations had developed
- Due to symptoms deterioration, patient had been referred to cardiologic department

PAST MEDICAL HISTORY

- In 2001 when she was pregnant *heart murmurs* were discovered
- Mitral valve prolapse 1st degree was diagnosed
- Correction was not required at that moment

DRUG HISTORY

- TORASEMIDE 5 mg qd in the morning
- IVABRADINE 7.5 bid

ALLERGIES AND REACTIONS

- Patient has not any allergies
- Patient has not any reactions to drugs and medication

ALCOHOL AND SMOKING

- Patient does not consume alcohol
- Patient does not smoke

SOCIAL HISTORY

- Patient is married and has 2 children , first one was born in 2001 and second child was born in 2003
- She lives in a separate apartment with her family
- All household chores carries out herself, she does not require any social help
- Patient works as an accountant and she is not stressed working for this job

EXAMINATION

VITAL SIGNS :

- Height of the patient – 160 cm
- Weight of the patient – 52 kg
- Temperature – 36.7°C
- Blood pressure – 80/60 mmHg
- Pulse – 110 bpm
- Respiratory rate – 30 pm

Hypotension and tachycardia occurs

EXAMINATION

GENERAL CONDITION

- Well groomed and good mood female
- The general condition of the patient is satisfactory, she is not in distress
- The consciousness is clear, she is well oriented in time and surroundings, speaking in full sentences

EXAMINATION

SKIN AND MUCOUS MEMBRANES

- **Skin** is pale pink and clear, skin turgor and elasticity are preserved, on the lower part of the neck to the left present small scar due to lymph node biopsy in 1995
- **Subcutaneous fat tissue** is well developed
- **Nails'** examination is unremarkable
- **Mucous membranes** are pink and wet
- **Tongue** is clear and wet
- **Edema** is absent at the time of inspection
- All groups of **lymph nodes** are not palpable, in the axillar region to the right palpated dense scar tissue (painless, possibly post beam therapy)

EXAMINATION

JOINTS, HEAD & NECK

- **Joints** are without any abnormalities
- **The head** examination is unremarkable
- The **neck** has normal shape and size, no visible enlargement of thyroid gland
- **Thyroid gland** is palpated, size is slightly increased, painless, has smooth surface, homogeneous structure, nodules are not detected
- **JVP** 4.7 cm above the sternal angle

EXAMINATION

RESPIRATORY & CARDIOVASCULAR SYSTEMS

- **The chest** has normal shape and size
- **Pulmonary percussion:** during comparative and topographic percussion, sound was resonant, lung borders are not changed
- **Lung auscultation:** vesicular breath sound, additional sounds are not present
- **Apex beat** localized in the 5th intercostal space, distance from midsternum is 8.5 cm in the recumbent posture, diffuse and diminished force
- **Auscultation of the heart:** S₁ and S₂ are soft, systolic murmur heard over mitral valve, pericardial friction rub along the left sternal border

EXAMINATION

GIT & URINARY SYSTEMS

- **Abdomen** is soft and nontender, no rebound
- **Liver percussion:** 13/12/9 cm
- **Liver** is palpated 4 cm lower than right costal arch, nontender and soft, and has smooth surface
- **Spleen percussion:** 10/15 cm
- **Spleen** is palpated 6 cm lower than left costal arch, tenderless, and elastic consistency
- **The kidneys** are not palpable
- **Urine** is pale yellow in color , daily diuresis is about 1200 ml/day
- **Stool** is dark brown in color, formed

Hepatosplenomegaly

INVESTIGATION METHODS

1. Complete blood count
2. General urine test
3. Biochemical blood tests (ALT, AST levels, bilirubin levels, creatinine, BNP)
4. Thyroid function tests
5. ECG
6. 24 hour monitoring ECG
7. US of heart
8. Chest X-ray
9. CT scan of chest
10. US abdomen
11. US of thyroid gland

CLINICAL DATA

Complete blood count on the day of admission

ESR 10 mm/h

RBC (N 3,9-5,0 $10^{*12}/L$)	4.28 $10^{*12}/L$	
Hb (N 120-160 g/L)	119 g/L	
WBC (N 4,0-9,0 $10^{*9}/L$)	5.5 $10^{*9}/L$	
NE (N 1,7-7,7 $10^{*9}/L$; 47,0-72%)	2.9 $10^{*9}/L$	53.1%
LY (N 0,4-4,4 $10^{*9}/L$; 19,0-37,0%)	2.0 $10^{*9}/L$	35.6%
MO (N 0,0-0,8 $10^{*9}/L$; 3,0-11,0%)	0.5 $10^{*9}/L$	9.2%
E (N 0,0-0,6 $10^{*9}/L$; 0,5-5,0%)	0.0 $10^{*9}/L$	0.7%
BA (N 0,0-0,2 $10^{*9}/L$; 0,0-1,0%)	0.1 $10^{*9}/L$	1.4%
PLT (N 180-320 $10^{*9}/L$)	245 $10^{*9}/L$	

All results falls under normal range

CLINICAL DATA

Urine analysis on the date of admission

Colour	Light yellow
Specific gravity (N 1,001-1,040)	1,015
pH (N 5,0-7,0)	5.0
Protein (N absent)	Absent
Glucose (N absent)	Absent
Eritrocytes (N single)	0-1/HPF
Leucocytes (N 6-8 in field)	3-4/HPF
Transitional epithelium (N single)	0-1/HPF
Casts: hyaline, granular, etc. (N single)	Absent
Crystals (N absent)	Absent

Urine analysis falls into normal range

CLINICAL DATA

Biochemical blood profile on the date of admission

Plasma glucose (3.9 - 6.4 venous blood) – 4.4 mmol/L

Bilirubin Total (N 17-21 mkmol/L)	5.2 mkmol/L
AST (N < 31 U/L)	16 U/L
ALT (N < 31 U/L)	26 U/L

Liver function tests fall in reference range

CLINICAL DATA

Biochemical blood profile on the date of admission

Creatinine (N 53-97 $\mu\text{mol/L}$)	97 $\mu\text{mol/L}$
Serum Na (N 135-145 mmol/L)	137 mmol/L
Serum K (N 3.5-5.1 mmol/L)	3.2 mmol/L

- **eGFR = The Cockcroft and Gault formula (1973)**
$$C_{Cr} = \left\{ \frac{(140 - \text{age}) \times \text{weight}}{72 \times S_{Cr}} \right\} \times 0.85 \text{ (if female)}$$
Units : C_{Cr} (creatinine clearance) = mL/minute , Age = years , Weight = kg , S_{Cr} (serum creatinine) = mg/dL
= 60 ml/min/1.73m²

Kidney function: there is decrease in GFR, iatrogenic hypokalemia

CLINICAL DATA

Biochemical blood profile on the date of admission

TSH (N 0.25-5 mkU/mL)	2.60 mkU/mL
--	--------------------

Thyroid hormones falls into normal range

CLINICAL DATA

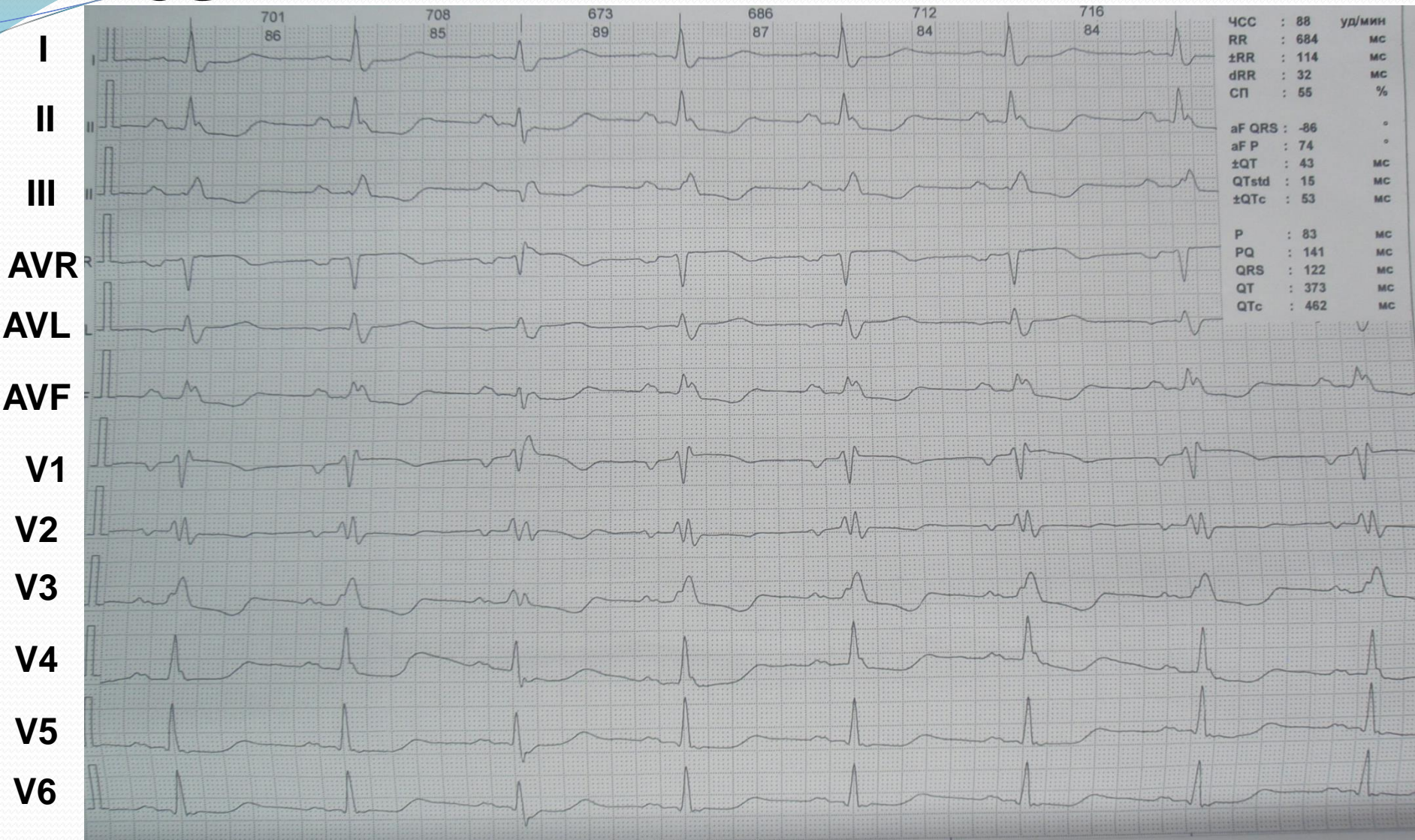
Biochemical blood profile on the date of admission

C-RP (N < 6 mg/L)	< 6 mg/L
Rheumatoid factor (N < 8 IU/mL)	< 8 IU/mL
ASL-O (N < 200 IU/mL)	< 200 IU/mL

All results fall into normal range; ESR, C-RP results shows absence of inflammation; rheumatoid factor shows normal autoantibodies; ASL-O represents absence of streptococcal infection

CLINICAL DATA

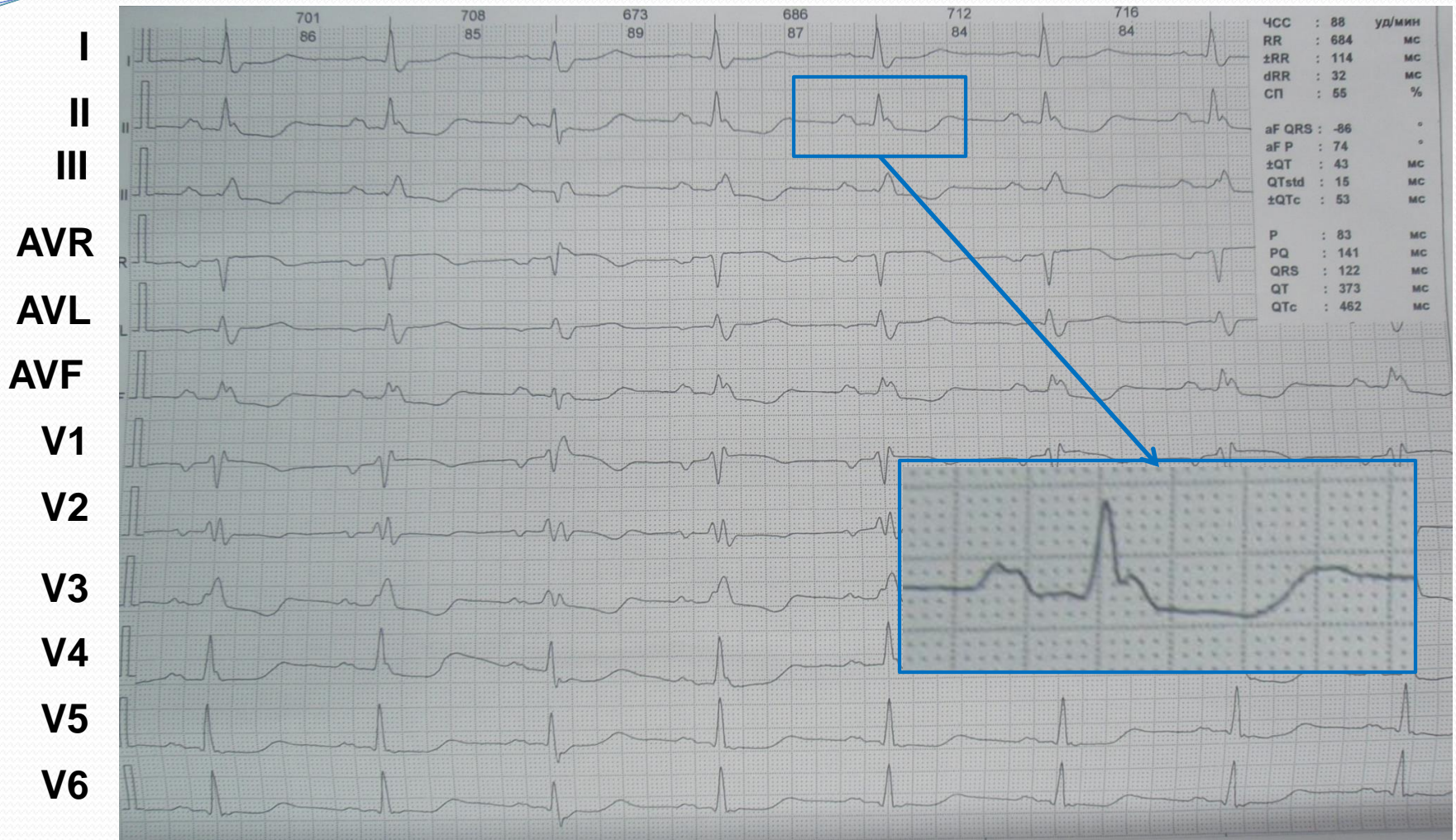
ECG



Sinus rhythm, 88 bpm, electrical alternans, vertical heart axis, complete RBBB, left ventricle overload, PR-segment depression in II, III, AVF, PR-segment elevation in AVR, ST-segment depression in I, II, III, AVF, V1-V6, ST-segment elevation in AVR, V1

CLINICAL DATA

ECG



*Sinus rhythm, 88 bpm, electrical alternans, vertical heart axis, **complete RBBB**, left ventricle overload, PR-segment depression in II, III, AVF, PR-segment elevation in AVR, ST-segment depression in I, II, III, AVF, V1-V6, ST-segment elevation in AVR, V1*

CLINICAL DATA

24 hour monitoring ECG

- 1) Sinus rhythm
- 2) Mean frequency 73 bpm (daytime 79 bpm, nighttime 63 bpm)
- 3) Min frequency 56 bpm
- 4) Max frequency 120 bpm
- 5) Single supraventricular premature beats (19 SPB)
- 6) Single ventricular premature beats (6 SPB)
- 7) Ischemic changes of ST-T were not observed

Significant abnormalities are not detected

CLINICAL DATA

Echocardiography

- Heart chambers: septal thickness 8 mm, LV posterior wall thickness 8 mm

Left ventricle

EDD 40 mm EDV 67 ml Stroke volume 47 ml

ESD 17 mm ESV 20 ML

Right ventricle diameter 24 mm

- Aortic valve fibrosis and regurgitation I degree
- Mitral valve prolapse I degree

• Pericardial effusion:

posterior wall 3,5 mm

anterior wall 7 mm

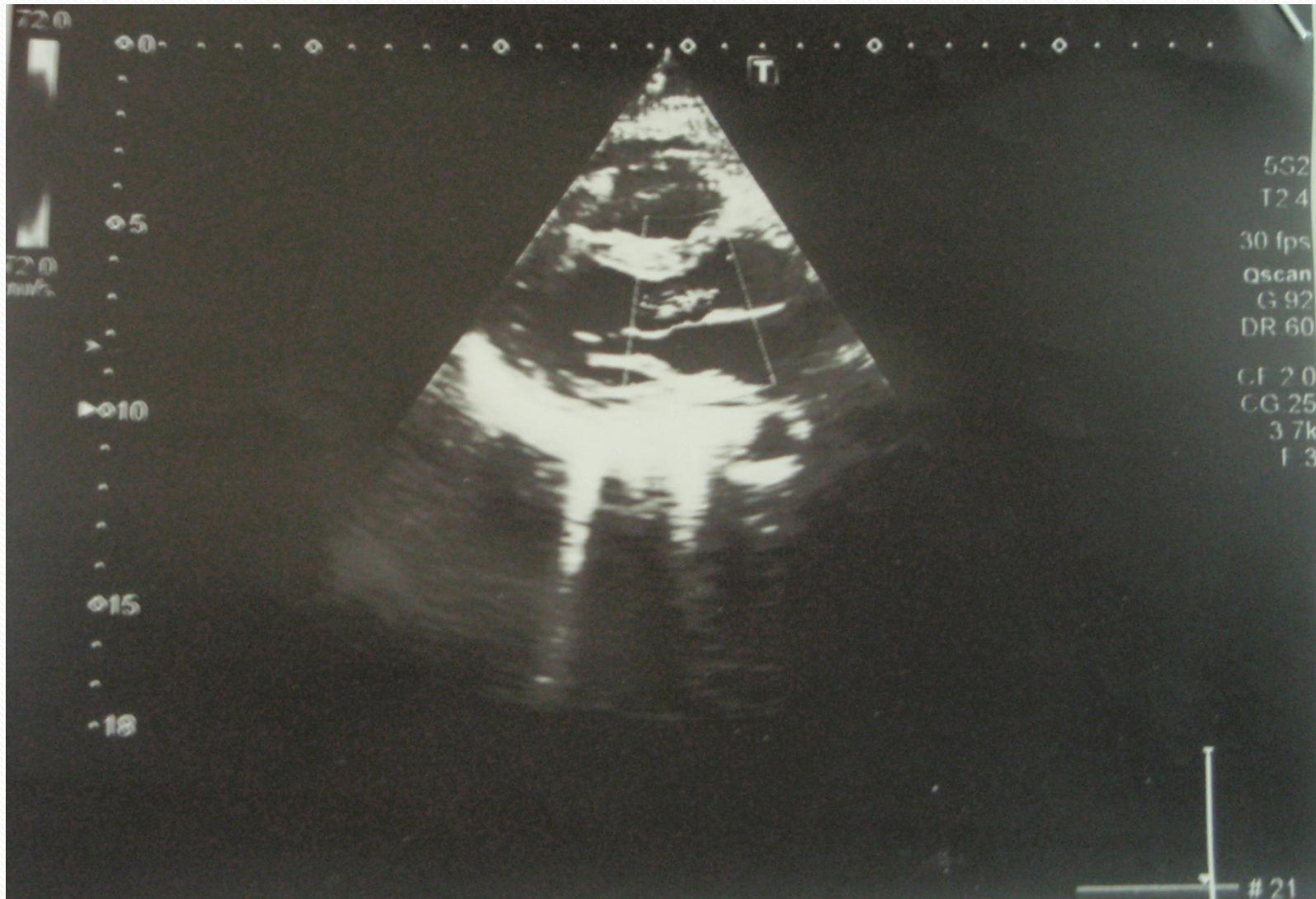
apex 2,5 mm

- Collapse of inferior vena cava on inspiration more than 50%
- Heart contractility is preserved (EF 75%)

Mild pericardial effusion is present, myocardial contractility is preserved, aortic fibrosis and regurgitation I degree, mitral valve prolapse I degree

CLINICAL DATA

Echocardiography



CLINICAL DATA

Echocardiography

By Comparision

IN 2016:

Pericardial effusion:

posterior wall 3,5 mm

anterior wall 7 mm

apex 2,5 mm

Ejection fraction is 75%

IN 2015:

Pericardial effusion:

posterior wall 5 mm

anterior wall 8 mm

apex 3 mm

Ejection fraction is 75%

The amount of fluid in pericardial sac decreased insighnificantly

CLINICAL DATA

Chest CT scan

- Signs of fibrosis of the lungs roots, likely beam therapy etiology
- Minimal upper mediastinal lymphadenopathy (paratracheal region); no reliable progression by comparison with 2008 year
- Cardiomegaly, mild hydropericardium (max fluid thickness 14 mm); occurrence of hydropericardium by comparison with 2008 year
- Diffuse changes in thyroid gland structure

Lung fibrosis and cardiomegaly with mild hydropericardium are detected

CLINICAL DATA

U.S of thyroid gland

- Thyroid gland is enlarged (goiter– 1st degree)
- Diffuse parenchyma changes: in both lobes occurs multiple cysts 2.5-4.0mm in diameter and hypoechogenic heterogenic inclusions with cystic component (right lobe 4.5*7.5mm in diameter and left lobe 9.5*7.5mm in diameter)

Goiter (1st degree) with diffuse nodular parenchyma changes is seen

CLINICAL DATA

U.S of Abdomen

- Liver : right lobe 15,5 cm, left lobe 8 cm; focal lesion of the 3rd segment of left lobe 10×12 mm in diameter
- Spleen: 7.5 cm/15 cm
- Left kidney: diminished in size (32×65 mm), lumbar displacement, diffuse hyperechogenicity of the parenchyma, thinning of the cortex, hypoechogenic inclusions (at least 2 inclusions) 6-14mm in diameter
- Right kidney has normal size (56×103 mm)
- Urolithiasis of both kidneys(2-4mm in diameter)

Hepatosplenomegaly, hemangioma of the left lobe of liver is seen; left kidney hypoplasia; urolithiasis

CONSULTATION

Cardiac surgeon consultation

Diagnosis:

*Chronic effusive pericarditis, not compressive.
Chronic heart failure I-II FC*

At the moment patient does not require surgical treatment of pericarditis, but only conservative treatment

CONSULTATION

Endocrinologist

Diagnosis:

Diffuse goiter I degree, euthyroidism

Condition does not require any correction at the present time

CLINICAL SYNDROMES

- Pericardial effusion
- Heart failure
- Cardiosclerosis
- Pneumofibrosis
- Chronic kidney disease
- Hepatosplenomegaly
- Goiter

Clinical Syndromes Classification

Pericardial effusion

Onset	Acute Subacute Chronic (>3 months)
Size	Mild <10 mm Moderate 10–20mm Large >20 mm
Distribution	Circumferential Loculated
Composition	Transudate Exudate

Clinical Syndromes Classification

Grading the size of an effusion by echocardiography measurements

- Physiologic/trivial

echo-free pericardial space < 5 mm \approx 50-100 ml of fluid

- Small

echo-free pericardial space 6-9 mm \approx 100-250 ml of fluid

- Moderate

echo-free pericardial space 10-19 mm \approx 250-500 ml of fluid

- Large

echo-free pericardial space >20 mm \approx >500 ml of fluid

Clinical Syndromes Classification

Pericardial effusion

According to the composition of the fluid

- Serous
- Purulent
- Fibrinous
- Caseous
- Hemorrhagic

Clinical Syndromes Classification

HEART FAILURE

Classification by time course

- Acute heart failure
- Chronic heart failure

Anatomical classification

- Left sided heart failure
- Right sided heart failure
- Total heart failure (Congestive HF)

Clinical Syndromes Classification

Heart Failure

The New York Heart Association (NYHA) Functional Classification

Class	Patient Symptoms
I	No limitation of physical activity. Ordinary physical activity does not cause undue fatigue, palpitation, dyspnea (shortness of breath).
II	Slight limitation of physical activity. Comfortable at rest. Ordinary physical activity results in fatigue, palpitation, dyspnea (shortness of breath).
III	Marked limitation of physical activity. Comfortable at rest. Less than ordinary activity causes fatigue, palpitation, or dyspnea.
IV	Unable to carry on any physical activity without discomfort. Symptoms of heart failure at rest. If any physical activity is undertaken, discomfort increases.

Clinical Syndromes Classification

Heart Failure

AHA/ACC Heart Failure Staging

Class	Objective Assessment
A	No objective evidence of cardiovascular disease. No symptoms and no limitation in ordinary physical activity.
B	Objective evidence of minimal cardiovascular disease. Mild symptoms and slight limitation during ordinary activity. Comfortable at rest.
C	Objective evidence of moderately severe cardiovascular disease. Marked limitation in activity due to symptoms, even during less-than-ordinary activity. Comfortable only at rest.
D	Objective evidence of severe cardiovascular disease. Severe limitations. Experiences symptoms even while at rest.

Clinical Syndromes Classification

Heart Failure

Table 3.1 Definition of heart failure with preserved (HFpEF), mid-range (HFmrEF) and reduced ejection fraction (HFrEF)

Type of HF	HFrEF	HFmrEF	HFpEF
CRITERIA	1	Symptoms ± Signs ^a	Symptoms ± Signs ^a
	2	LVEF <40%	LVEF 40–49%
	3	–	1. Elevated levels of natriuretic peptides ^b ; 2. At least one additional criterion: a. relevant structural heart disease (LVH and/or LAE), b. diastolic dysfunction (for details see Section 4.3.2).

BNP = B-type natriuretic peptide; HF = heart failure; HFmrEF = heart failure with mid-range ejection fraction; HFpEF = heart failure with preserved ejection fraction; HFrEF = heart failure with reduced ejection fraction; LAE = left atrial enlargement; LVEF = left ventricular ejection fraction; LVH = left ventricular hypertrophy; NT-proBNP = N-terminal pro-B type natriuretic peptide.

^aSigns may not be present in the early stages of HF (especially in HFpEF) and in patients treated with diuretics.

^bBNP > 35 pg/ml and/or NT-proBNP > 125 pg/mL.

Clinical Syndromes Classification

Cardiosclerosis

- Following myocarditis
- Atherosclerotic
- Postinfarction

- Focal

- Diffuse

Clinical Syndromes Classification

Interstitial Lung disease

- Idiopathic disorders
- Connective tissue and autoimmune disease
- Occupational and environmental
- Drug induced
 - ✓ Chemotherapeutic agent
 - ✓ Radiation therapy
 - ✓ Anthyarrhythmics
 - ✓ Antibiotics
 - ✓ Anticonvulsants
- Infections
- Genetic/inherited

Clinical Syndromes Classification

Types of Drug Induced Renal Injury in Patients with Oncologic Disease

Acute tubular necrosis, Interstitial nephritis	Cisplatin, carboplatin, methotrexate, mitomycin-C, cyclosporine, ifosfamide, zoledronate, gemcitabine, interferons, urea derivatives, antibiotics, radiopaque substances
Glomeruli	Interferons, VEGF inhibitors, adriamycin , mitomycin-C, methotrexate, gemcitabine, urea derivatives, pamidronate
Renal vascular lesions	VEGF inhibitors, mitomycin-C, gemcitabine, cisplatin, bleomycin

Clinical Syndromes Classification

Chronic Kidney Disease

K/DOQI classification of the stages of chronic kidney disease (2002)

Stage	Description	GFR (mL/min/1.73 m ²) Action	Plan
1	Kidney damage with normal or elevated GFR	≥90	Diagnosis, treatment of underlying condition and comorbidities, cardiovascular disease risk reduction
2	Kidney damage with mildly decreased GFR	60-89	Estimating progression
3	Moderately decreased GFR	30-59	Evaluating and treating complications
4	Severely decreased GFR	15-29	Preparation for renal replacement therapy
5	Kidney failure (ESRD)	<15 (or dialysis, transplantation)	Replacement therapy (dialysis or transplantation)

ESRD, end-stage renal disease; GFR, glomerular filtration rate.

Adapted from the National Kidney Foundation: K/DOQI Clinical practice guidelines for chronic kidney disease: Evaluation, classification, and stratification. Am J Kidney Dis 2002;39:S1-S26(1)

Clinical Syndromes Classification

Causes of Hepatomegaly with Splenomegaly

- **Chronic liver disease** with portal hypertension: any cause of liver disease
- **Hematological disease:** Myeloproliferative disease, Leukemia, Lymphoma, Sickle cell anemia, Thalassemia, etc.
- **Infections:** Acute viral hepatitis, CMV/EBV, Malaria, Leishmaniasis, etc.
- **Infiltration:** Amyloidosis, Sarcoidosis
- **Miscellaneous:** Drug abuse, Acromegaly, SLE, Multiple sulfatase deficiency, Osteopetrosis

Clinical Syndromes Classification

WHO goiter classification

Grade 0 – no goiter presence is found (the thyroid impalpable and invisible)

Grade 1 – neck thickening is present in result of enlarged thyroid, palpable, however, not visible in normal position of the neck; the thickened mass moves upwards during swallowing. Grade 1 includes also nodular goiter if thyroid enlargement remains invisible

Grade 2 – neck swelling, visible when neck is in normal position, corresponding to enlarged thyroid- found in palpation

Clinical Syndromes Classification

Goiter classification according to thyroid function

- Non-toxic goiter
- Toxic goiter
- Hypothyroid goiter

Clinical Syndromes Classification

Goiter classification according to the thyroid structure

- Diffuse
- Nodular

FINAL DIAGNOSIS

Main disease

Hodgkin's Lymphoma, remission

Complications

Late Hodgkin's lymphoma therapy complications:

Chronic mild pericardial effusion,

Diffuse cardiosclerosis following aseptic myocarditis,

Aortic valve sclerosis,

Sinus tachycardia, right bundle branch block

Chronic congestive heart failure with preserved EF (75%),

II FC NYHA,

Hypoplasia? (Druid induced atrophy?) of the left kidney,

CKD II stage,

Hepatomegaly with splenomegaly,

Diffuse nodular non-toxic goiter

MANAGEMENT

Heart Failure

- Diet: salt restriction, rich in potassium
- Rate control: IVABRADINE 7.5 mg bid
- Diuresis control: TORACEMIDE 5 mg qod
- Hypokalemia: POTASSIUM CHLORIDE 600 mg bid
(under control of serum potassium)
- ACE-inhibitors: RAMIPRIL 1.25 mg qd

MANAGEMENT

Pericardial Effusion

- NSAIDs

Aspirin 500 mg qd

Gastroprotection

Pantoprazole 40 mg qd

OUTCOME

- Despite of therapy, pericardial effusion persist by control echocardiography data

posterior echo-free 3 mm

anterior echo-free 6 mm

apex echo-free 3.5 mm

- Symptoms ceased insignificantly, physical tolerance slightly increased, but lower extremities edema and morning eyelid puffiness are observed

CONCLUSION

- Patients who have been treated for Hodgkin's disease, despite being cured of their malignancy, may develop iatrogenic complications that lead to premature mortality
- A substantial excess risk of mortality may be attributable to second cancers and cardiac diseases
- Multitude of patients have been treated with anthracyclines or chest radiation, both of which may cause cardiovascular and kidney damage

CONCLUSION

- The frequency of long-term complications in patients treated for Hodgkin's disease makes continued follow-up an important part of their care
- This follow-up should include efforts to prevent morbidity and mortality by early diagnosis and attention to risk factors
- Future treatment regimens for Hodgkin's disease should be designed attempting to minimize these complications

