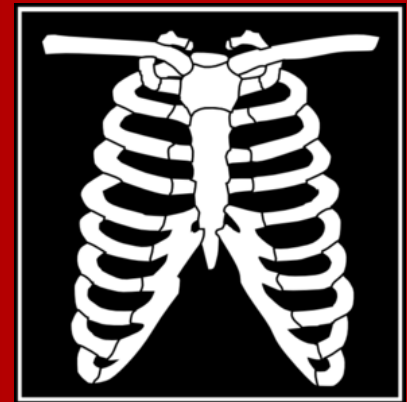

Basic chest X-ray interpretation

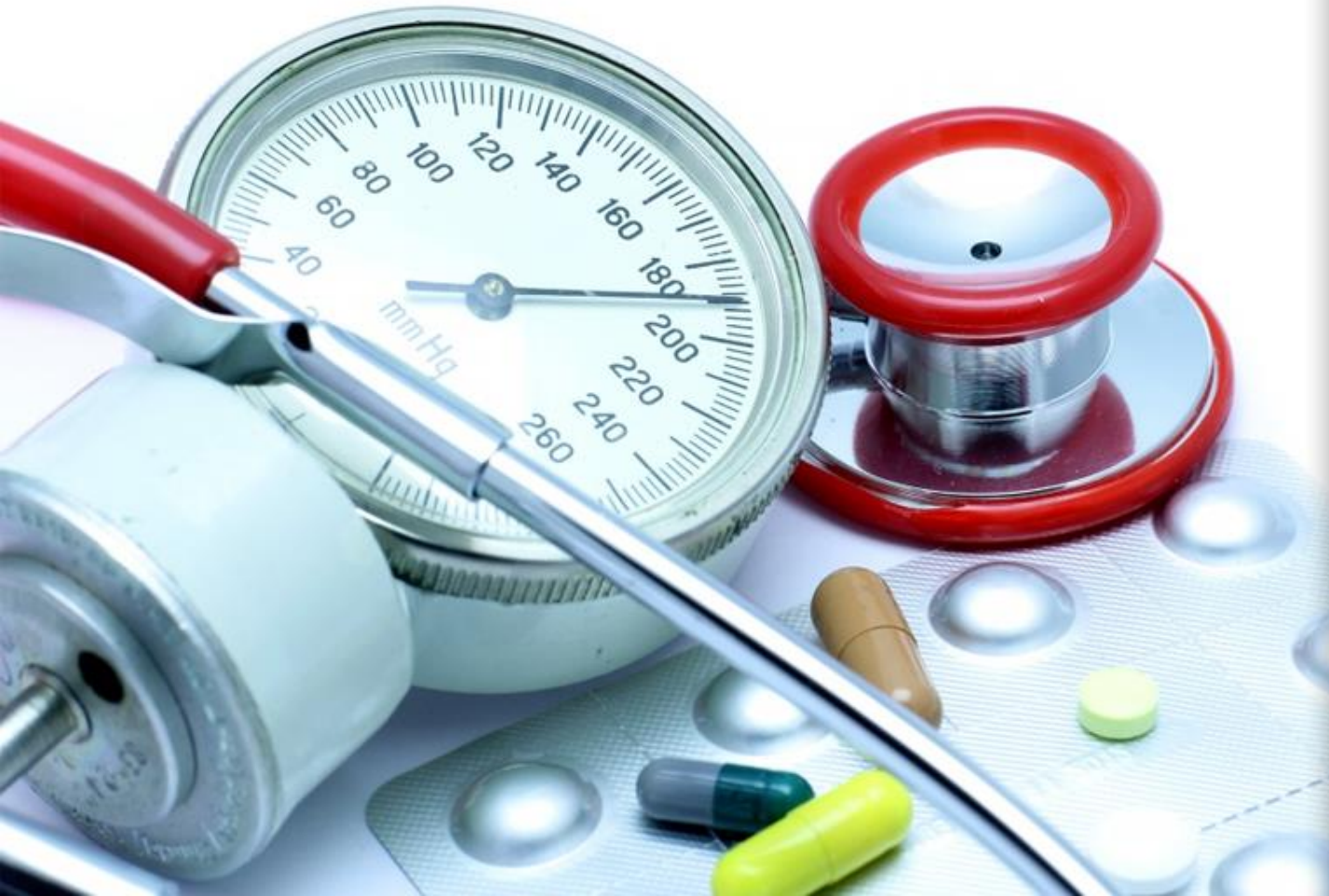- Anton Litvin, assistant of Internal Medicine Department
- Maryna Shevchuk, associate professor of Internal Medicine Department
- Elvira Aydinova, assistant of Propaedeutics of Internal Medicine and Physical Rehabilitation Department



V. N. Karazin Kharkiv
National University



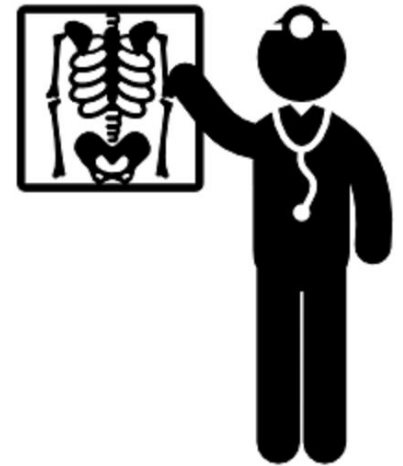
Part 1



Content



- **§1. Introduction**
- **§2. CXR quality**
- **§3. CXR anatomy**



§1. Introduction.



- **History**
- **Relevance**
- **Positive/negative picture**
- **Differential absorption**
- **Glass test tube**



History

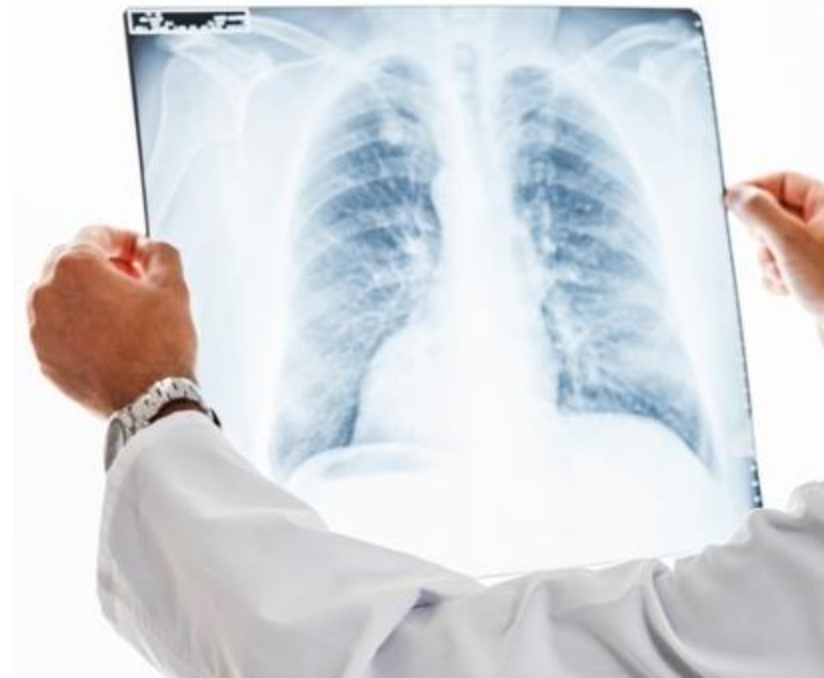

- X-rays were discovered in 1895 by **Wilhelm Conrad Röntgen (1845-1923)** who was a Professor at Würzburg University in Germany.
- This discovery was awarded with the first Nobel Prize in physics in 1901.
- Within a month after the announcement of the discovery, several medical radiographs had been made in Europe and the United States, which were used by surgeons to guide them in their work.

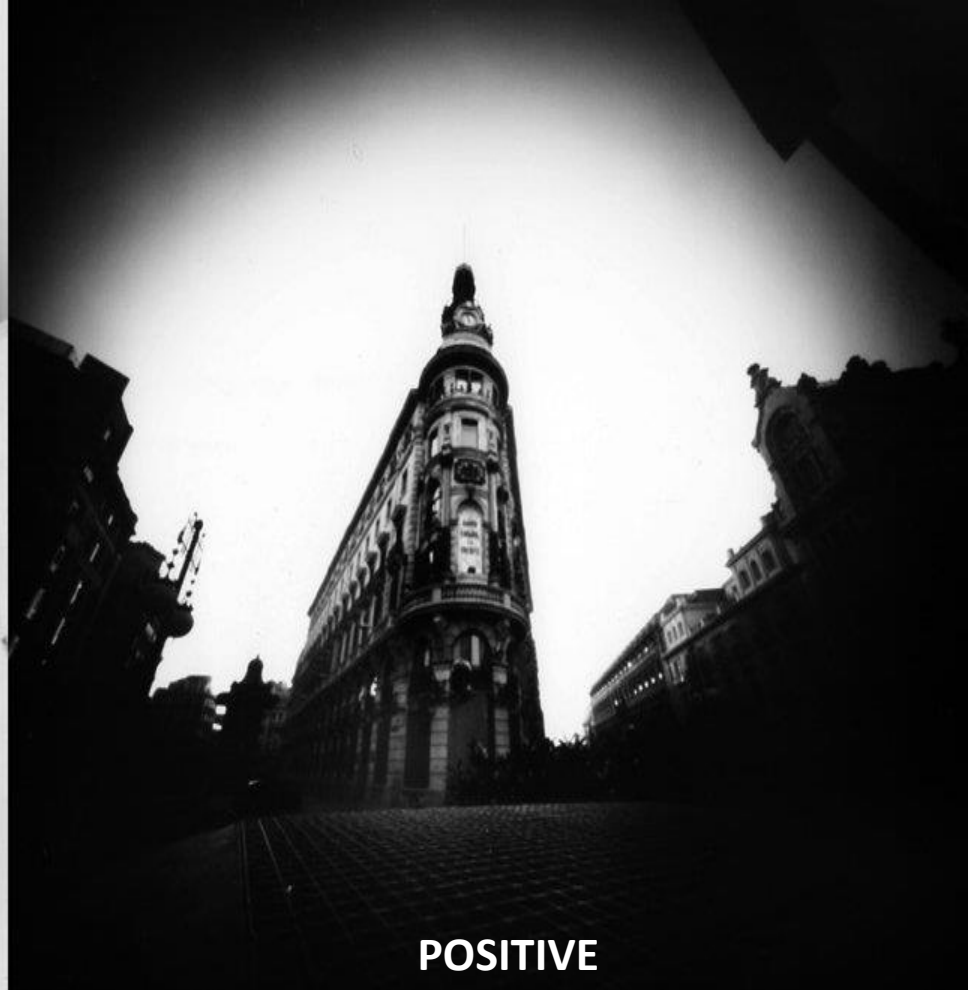
Relevance



- Chest X ray is a leading and prevailing method of chest cavity organs imaging.
- Allows to receive detailed and reliable data about the anatomic condition of cardiovascular, pulmonary and musculoskeletal systems.
- Along with CBC, urinalysis and ECG, chest radiography is one of the obligatory investigations provided to every in-patient who was admitted to healthcare units of various specializations.
- Cheap, accessible and still reliable and effective imaging method.



Positive/negative picture



The X-ray picture is a **negative** image.

Differential absorption



- Penetration of the X-ray beam depends on tissue density.
- **Denser object =**
Less beam striking the film
(more absorption) =
WHITE color = SHADOW (OPACITY)
- **Less dense object =**
More beam striking the film =
BLACK color = LUCENCY



Black

Dark-grey


Light-grey

Nearly white

White



Gas



Fat



Soft tissue
Fluid



Bone
Calcification



Metal

Glass test tube



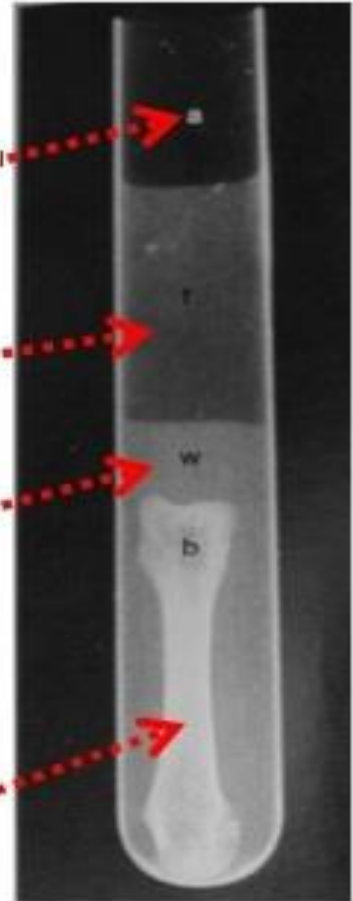
- **Glass test tube** is used for calibration of X-ray machines.

- **Black** Air (Lungs / Trachea)

- ↓ Fat (Fat & fascia)

- ↓ Water (Muscle / Organs)

- ↓ Bone (Bone / Atherosclerotic plaques)



- **White** Metal (Fillings / Markers / Ortho devices)

§2. CXR quality



- **CXR quality concepts**
- **Inclusion**
- **Projection**
 - *PA vs. AP*
 - *Posterior/anterior ribs*
 - *Cardiothoracic ratio*
- **Rotation**
- **Inspiration**
 - *Hyperexpansion*
- **Penetration (exposure)**
- **DRSABCDE approach**
- **Artifacts**



CXR quality concepts



- It is important to assess the **quality** of the image before interpreting a CXR.
- Do not immediately discard a CXR because it is not perfect: **even sub-optimal images demonstrate life-threatening abnormalities** which may require your immediate attention.
- If the **clinical question** can still be **answered** then acquiring another image is not necessary.

CXR quality concepts



1. Inclusion
2. Projection (PA or AP view)
3. Rotation
4. Inspiration (lung volume)
5. Penetration
6. Artifacts (extras)

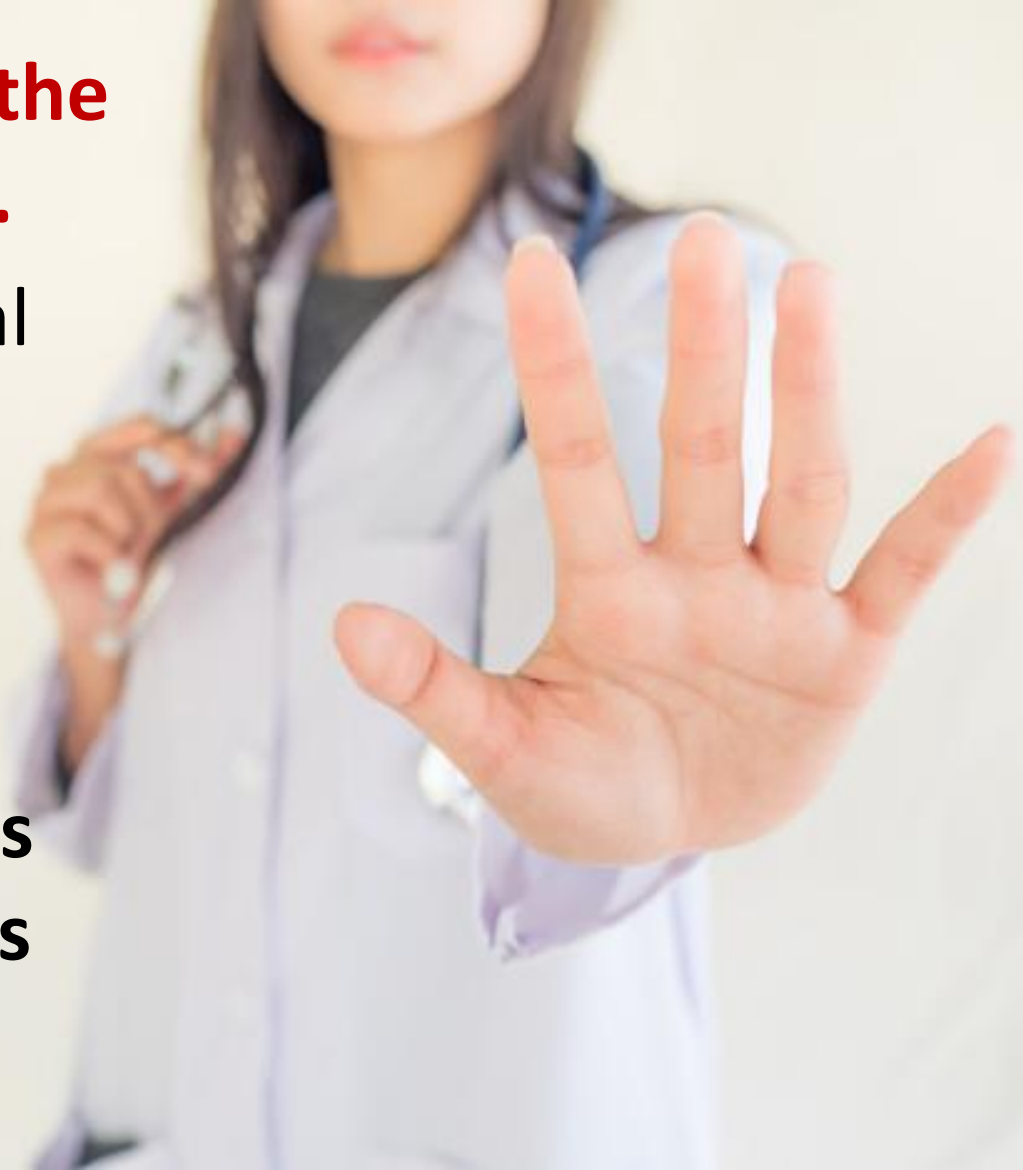NB! The chest X-ray should be obligatory checked for **rotation, inspiration and penetration** (**RIP**-Rest In Peace).



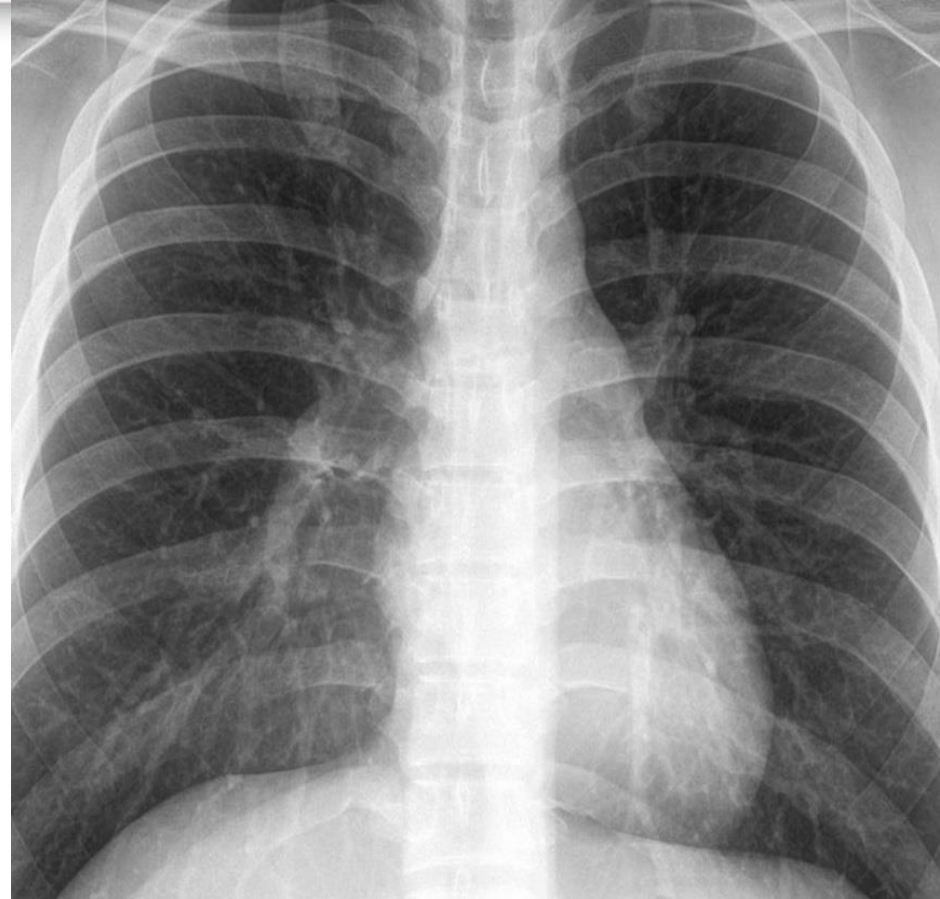
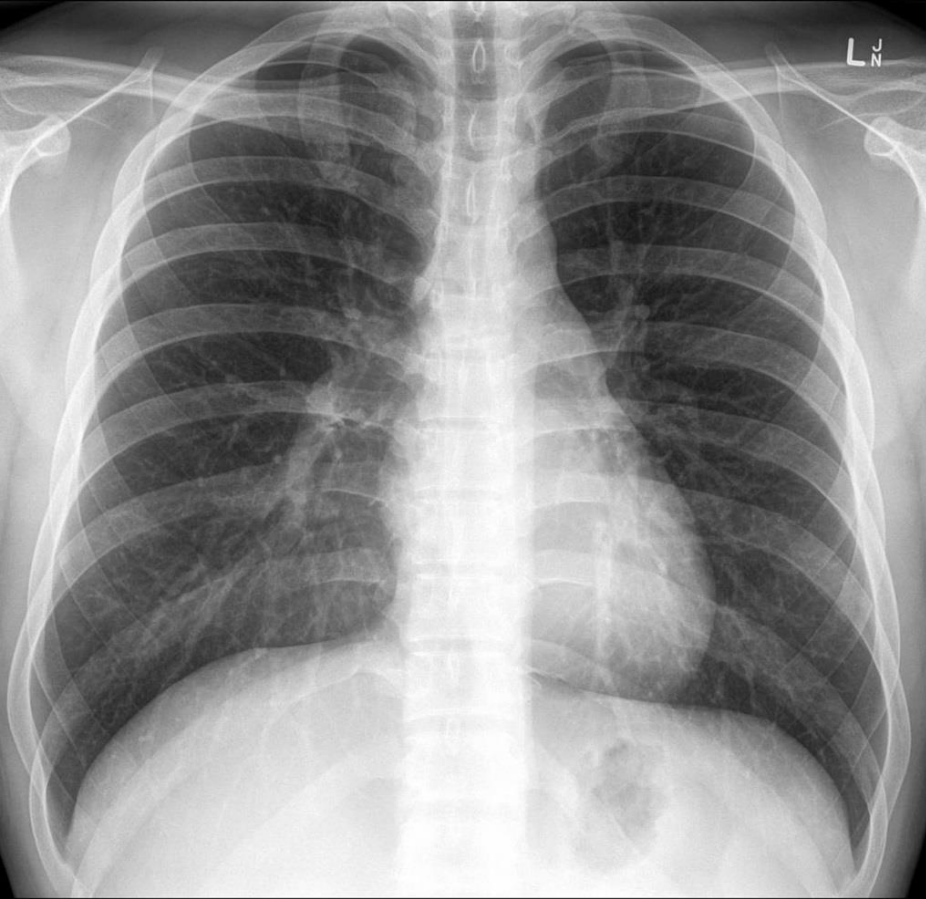
Inclusion



- **CXR should include the entire thoracic cage.**
- Important anatomical structures, which occasionally are not included:
 - **First ribs**
 - **Costophrenic angles**
 - **Lateral edges of ribs**



Inclusion



This CXR includes all of the required anatomical structures.

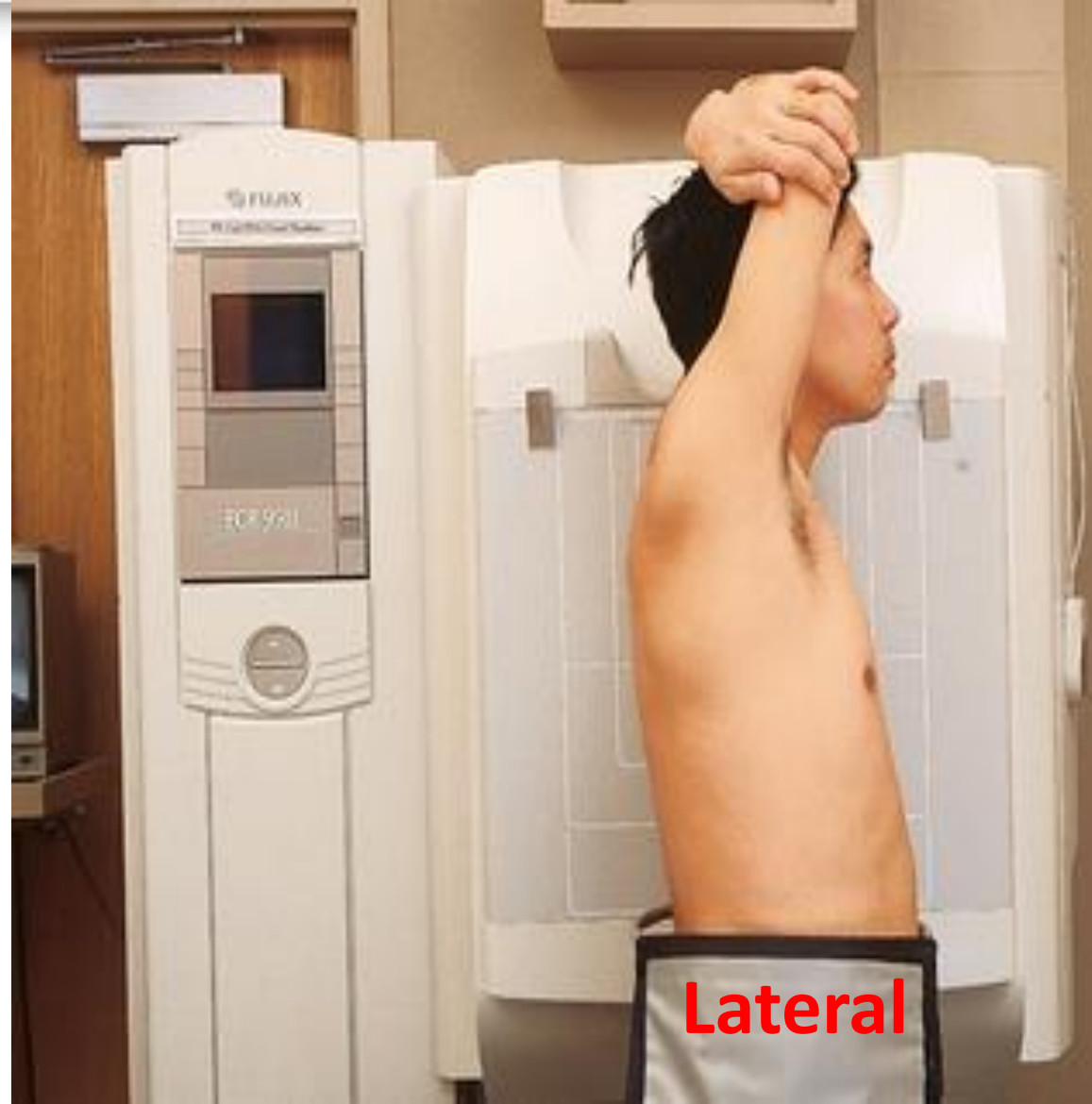

This CXR lacks some important anatomical structures.

Projections

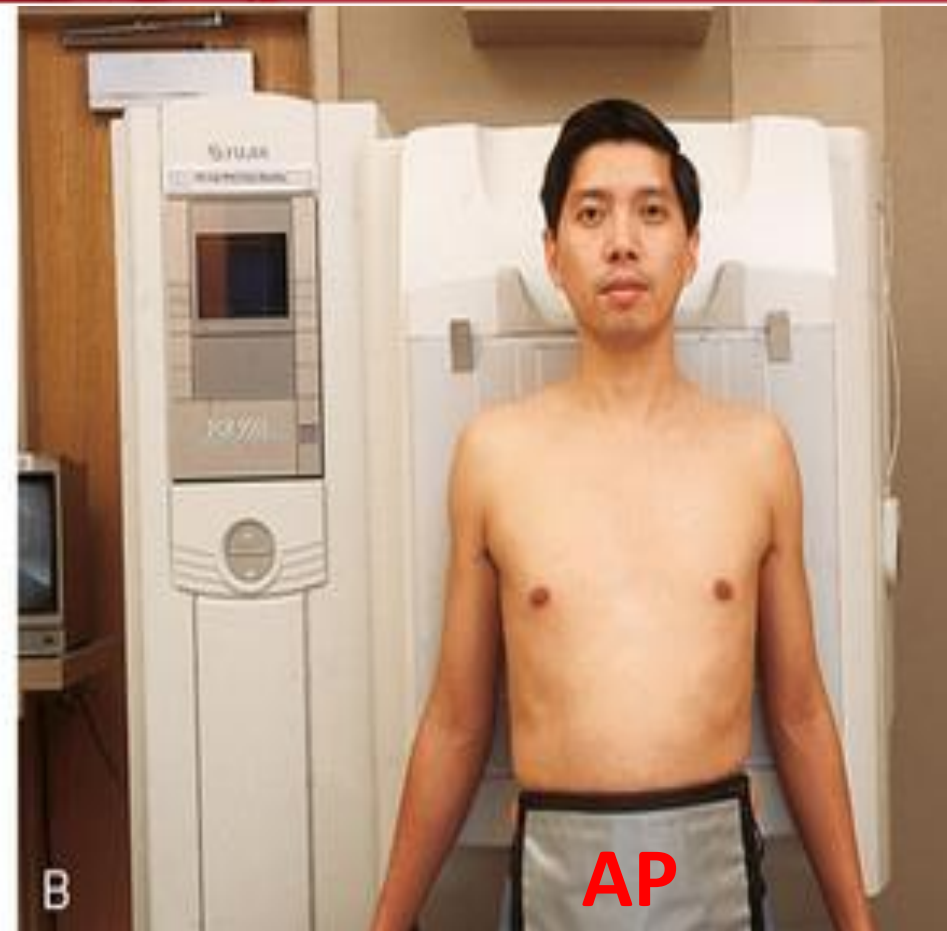
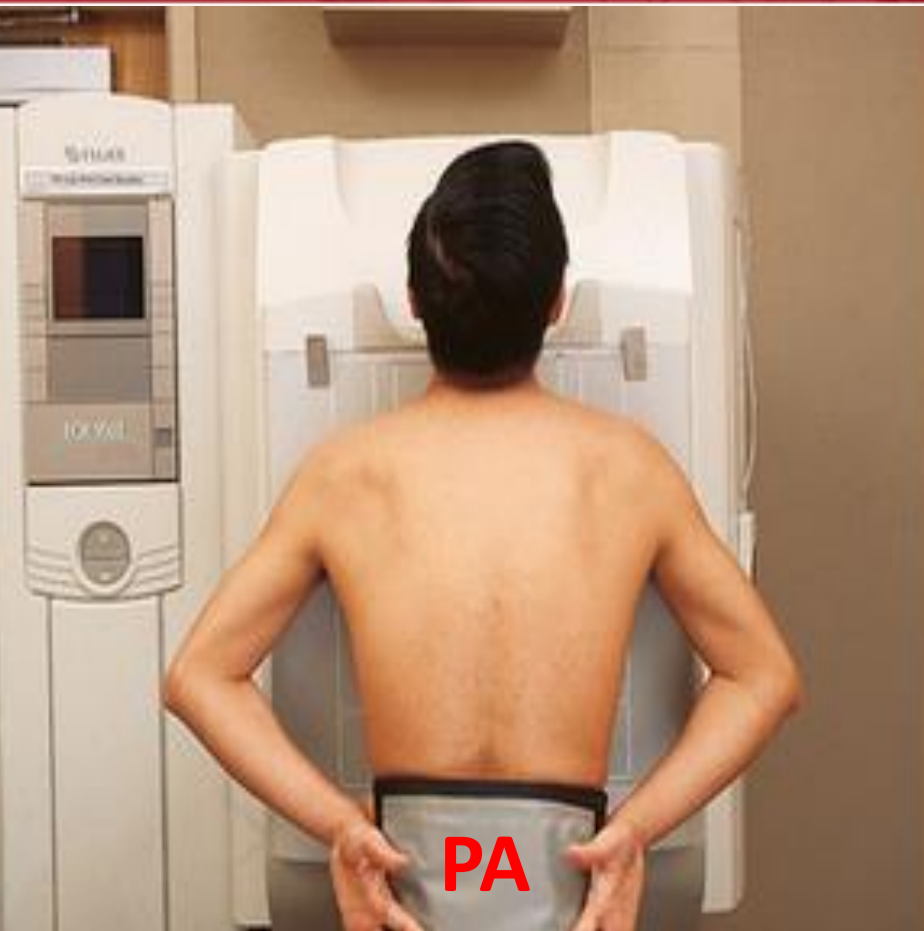

- **PA**
(Posteroanterior)
- **AP**
(Anteroposterior)
- **Lateral**



Lateral

Projections



- **PA chest view** is the most common radiological investigation.
- **AP views** are less useful and should be reserved for very ill patients who cannot stand erect.

Why radiologists want 2 views?



AP



Lateral

PA vs. AP



PA view

- Scapula is seen in periphery of thorax
- Clavicles project over lung fields
- Posterior ribs are more distinct

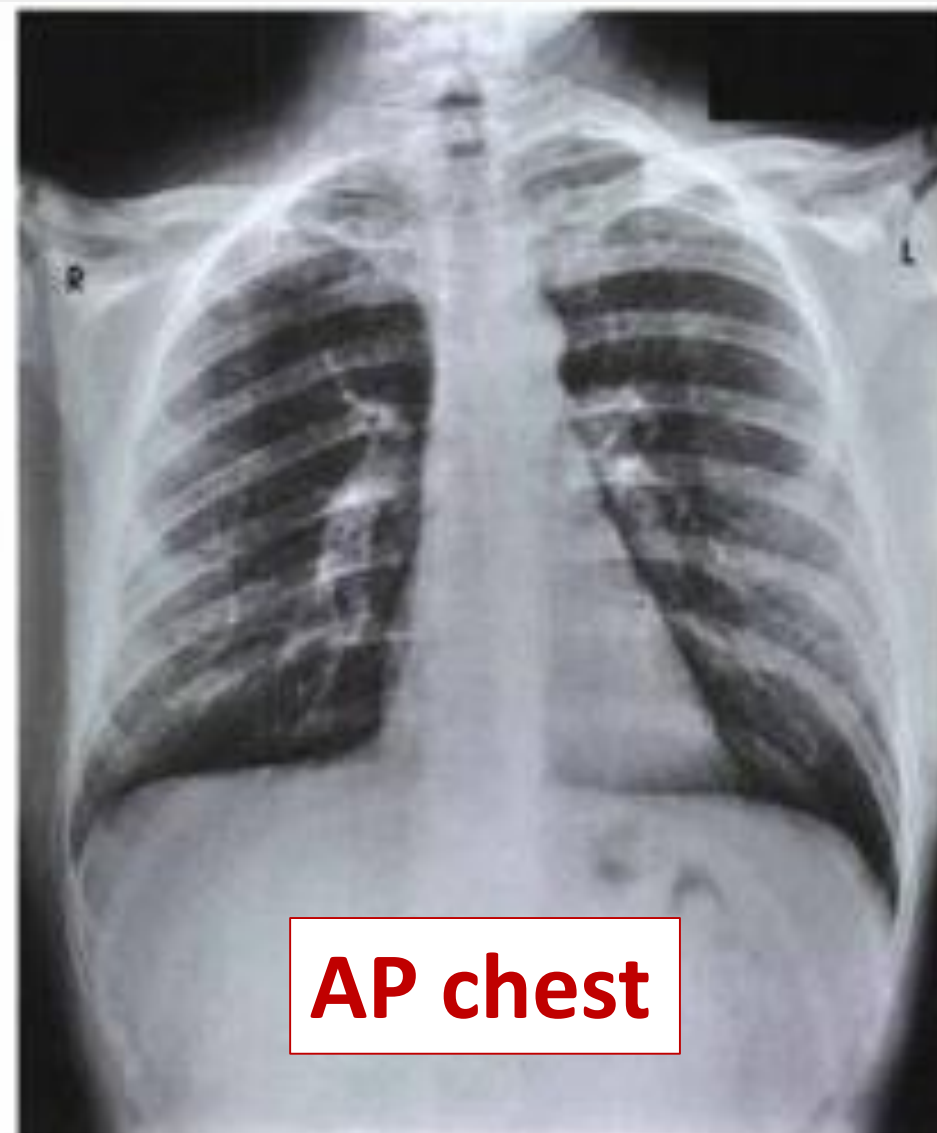
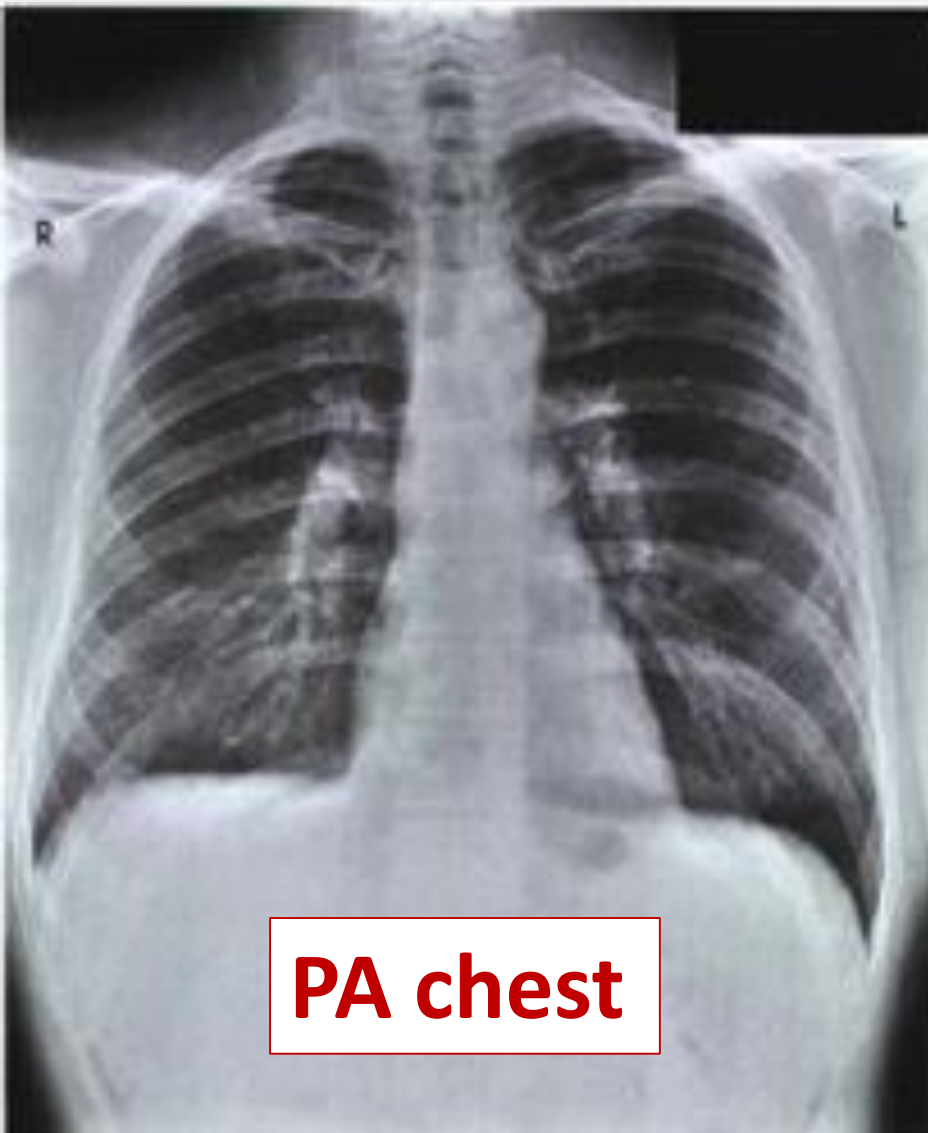
AP view

- Scapula is over the lung fields
- Clavicles are on/above the apex of lung fields
- Anterior ribs are more distinct

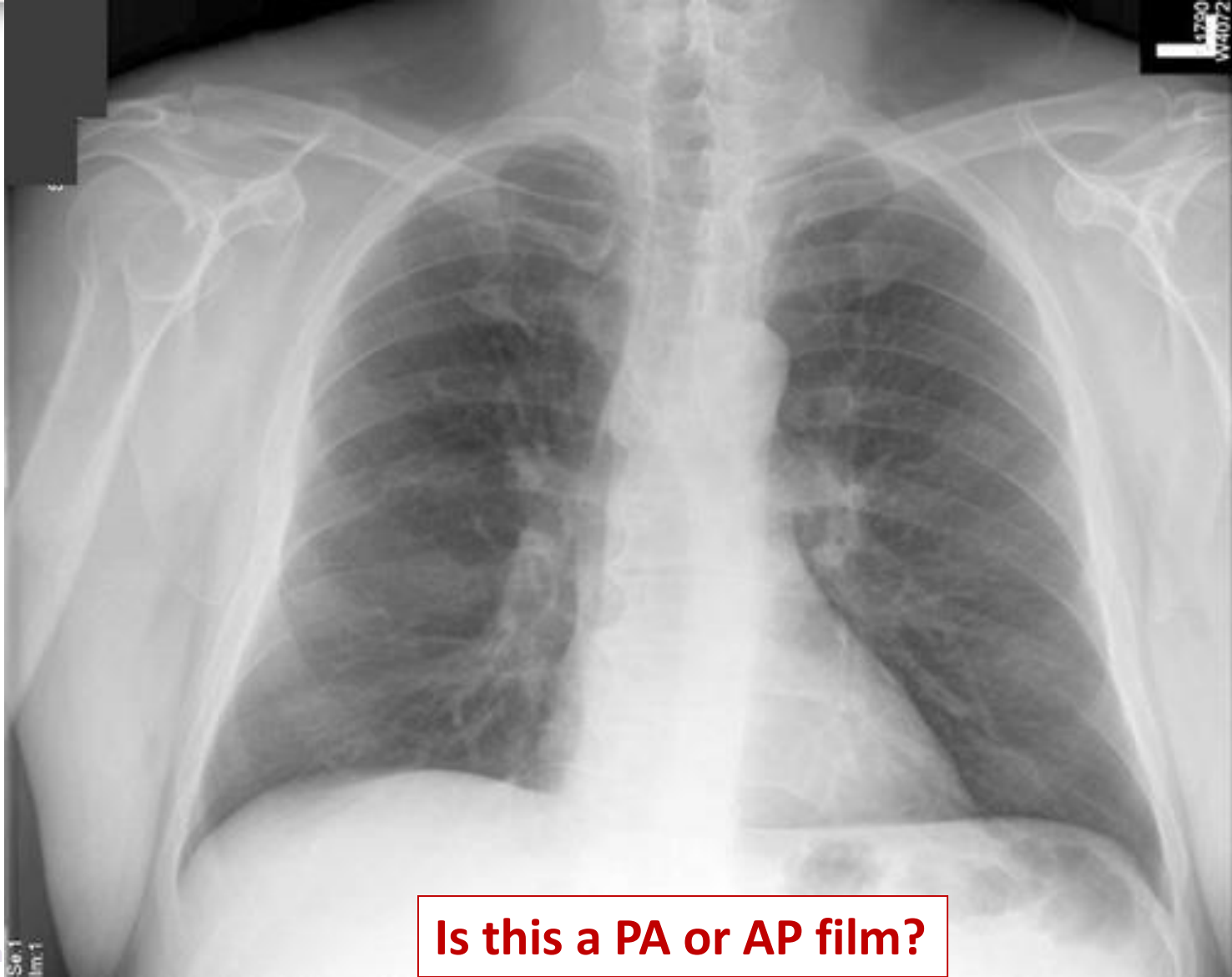


Pay attention to markers position (L/R).

PA vs. AP

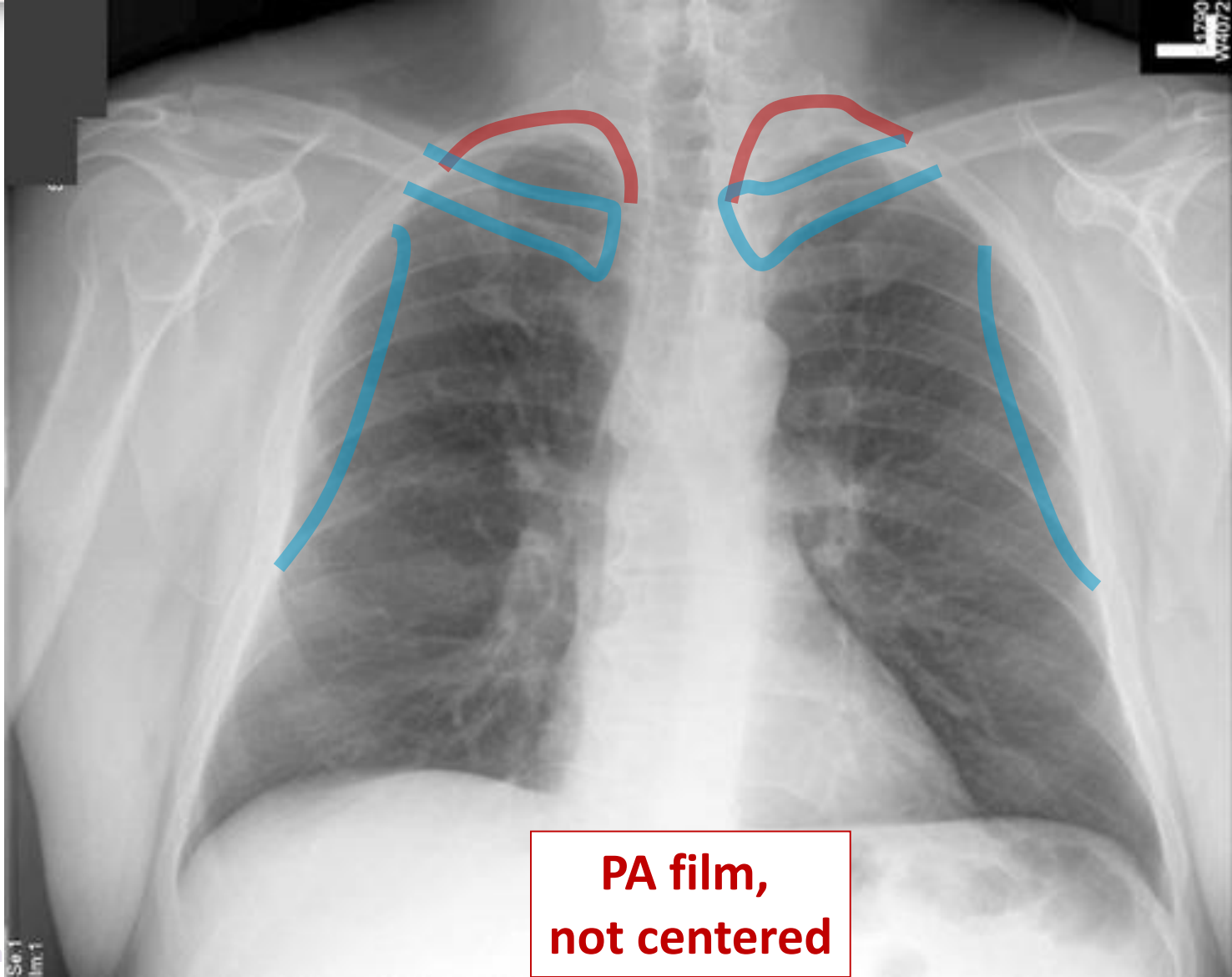


PA vs. AP



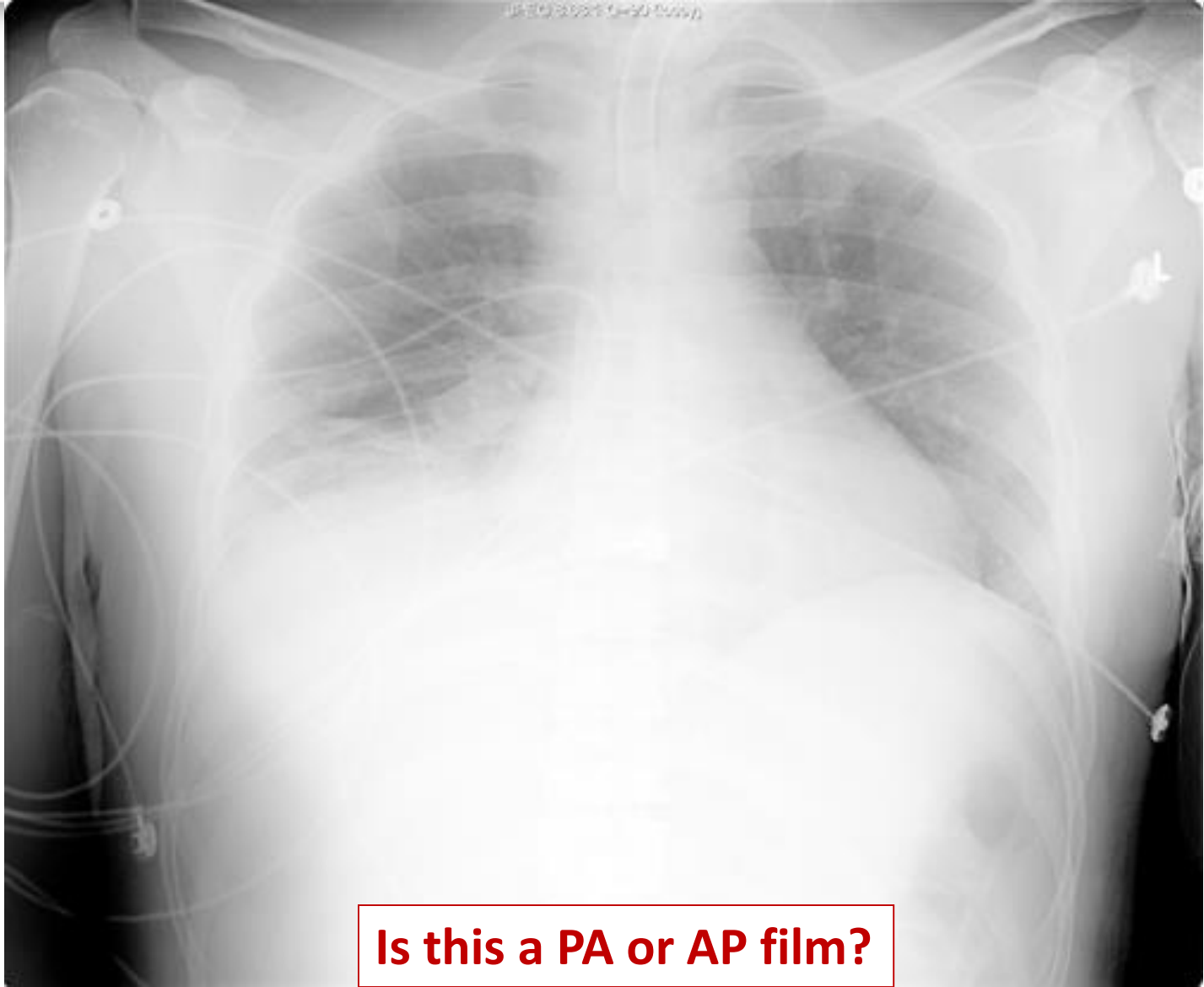
Is this a PA or AP film?

PA vs. AP



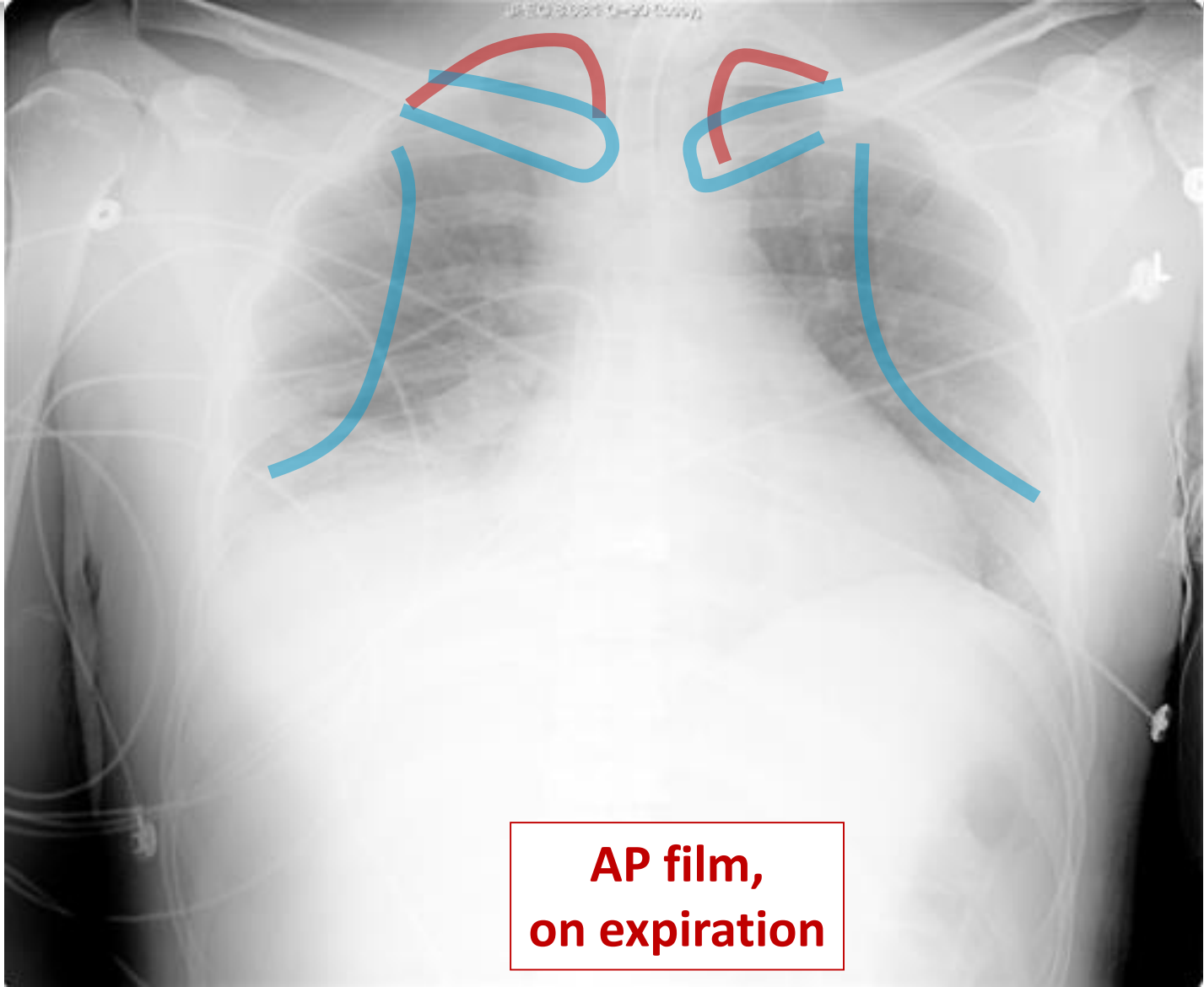
**PA film,
not centered**

PA vs. AP



Is this a PA or AP film?

PA vs. AP

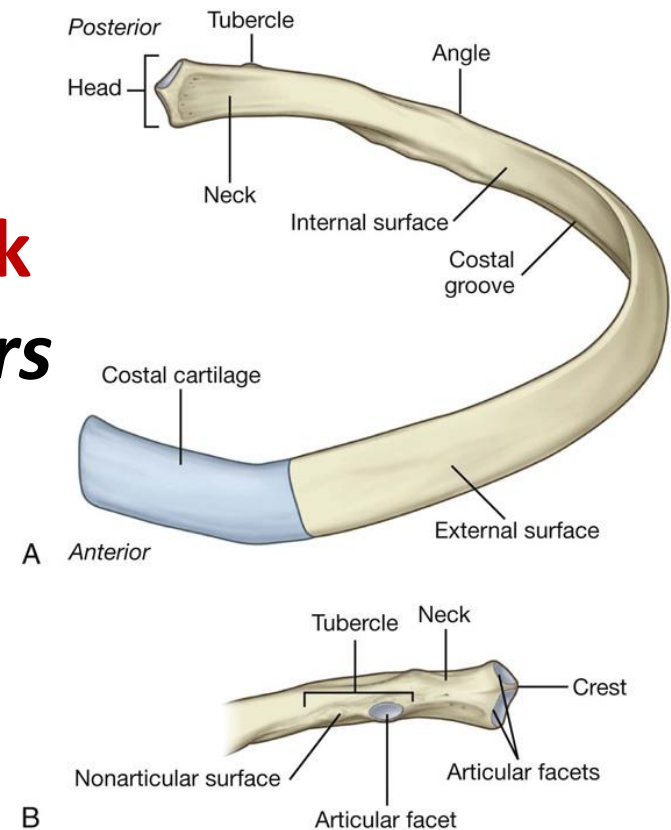


**AP film,
on expiration**

Posterior/anterior ribs



- Distinguishing the **posterior and anterior ribs** is crucial in CXR interpretation.
- **Anterior ribs are the landmark** in describing the *organ borders* and pathologic *abnormalities location*, distinguishing of *expiration/inspiration phase*, evaluating *hyperexpansion*, etc.



Posterior ribs vs. Anterior ribs



Posterior ribs

- Clearly visible on all AP and most of PA films
- Set horizontal
- Form an angle $\sim 90^\circ$ with the spine

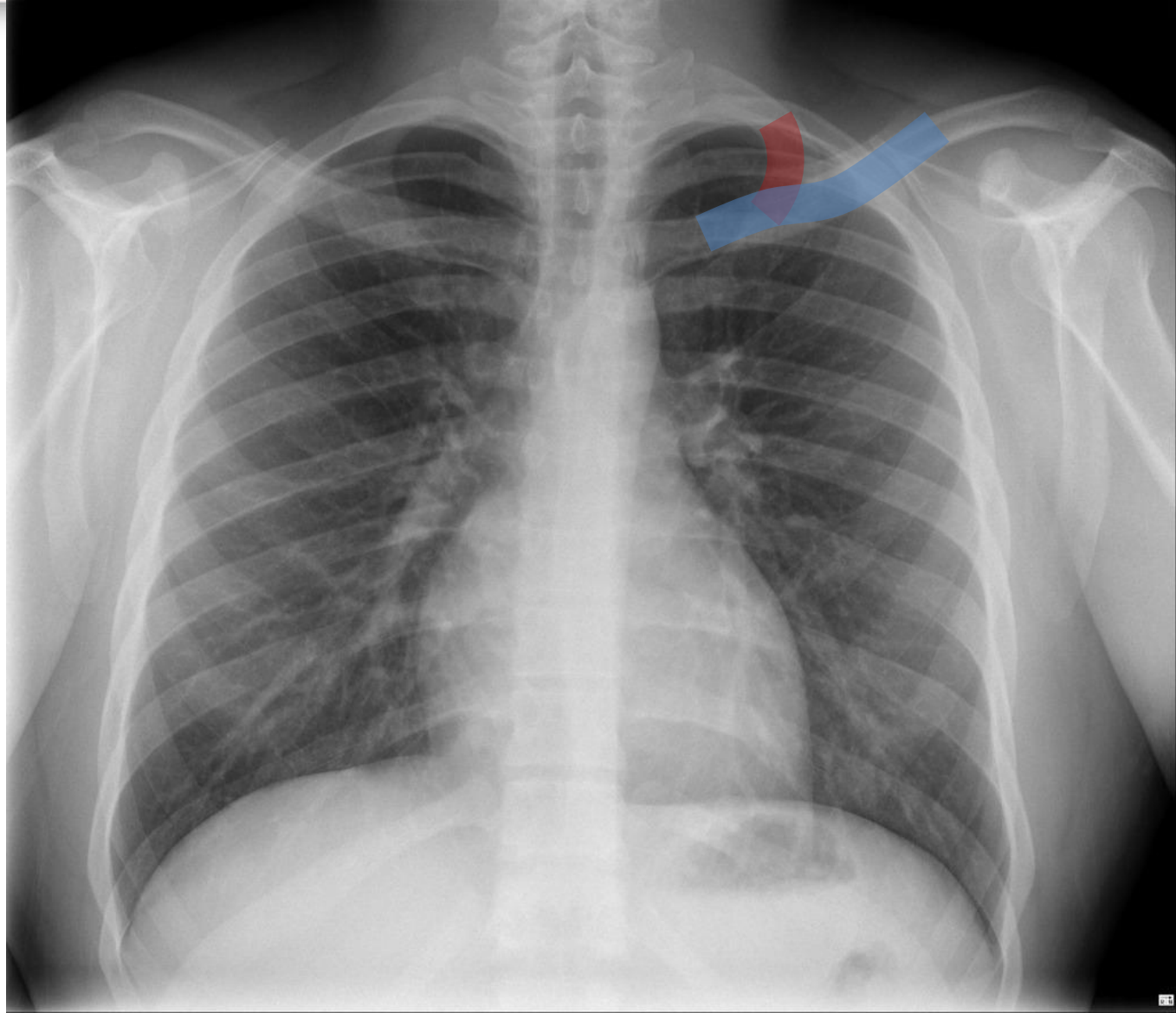
Anterior ribs

- Clearly visible on some AP films
- Set nearly vertical
- Directed downwards with the angle $\sim 45^\circ$
- “Disappear” on their way to sternum

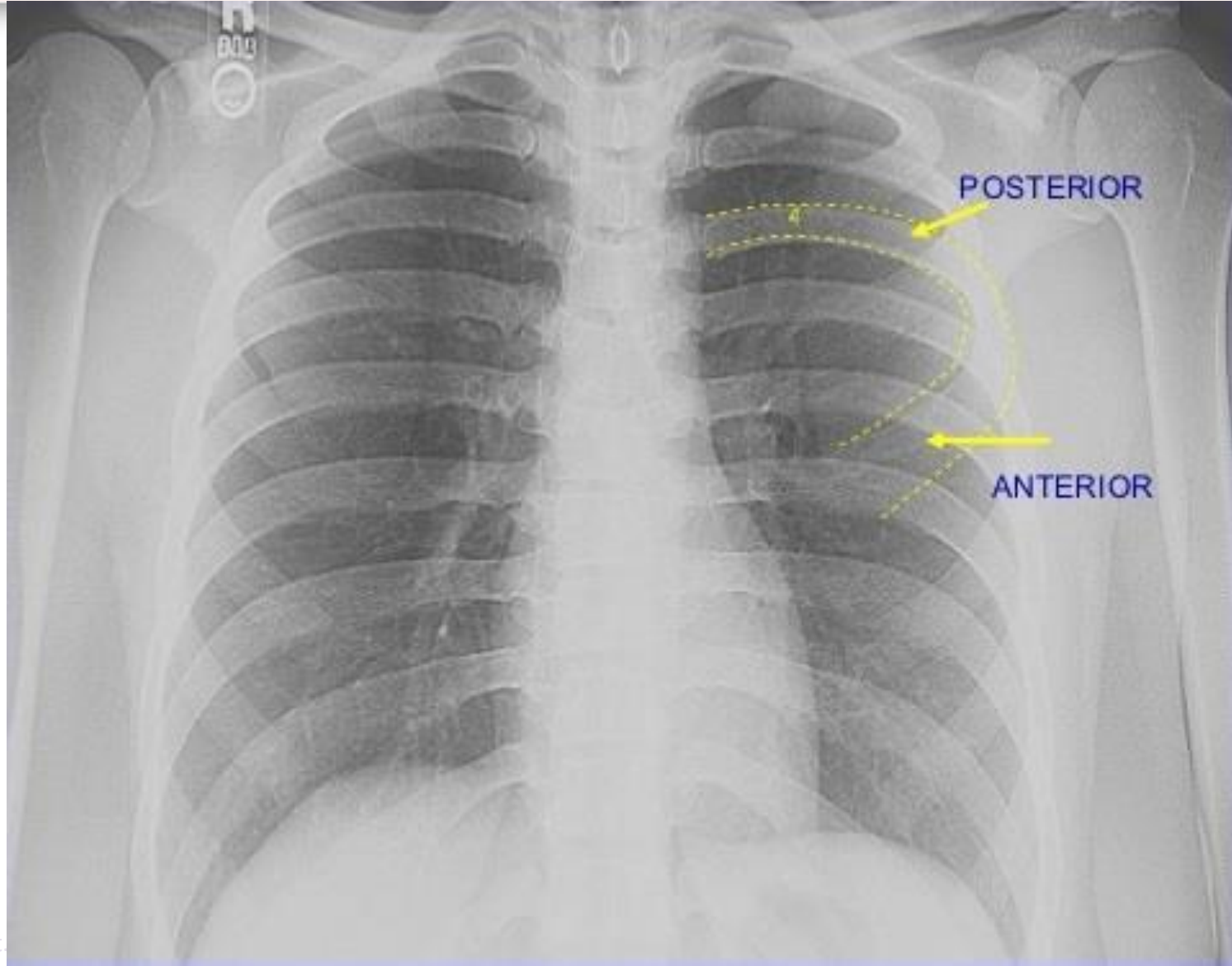
Posterior/anterior ribs



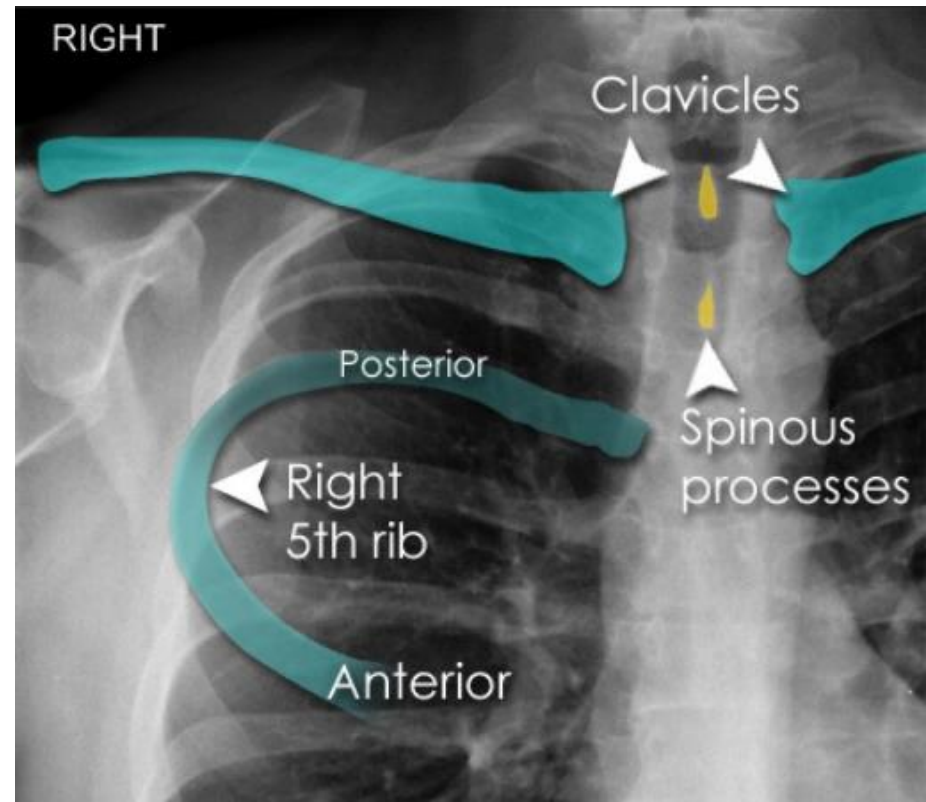
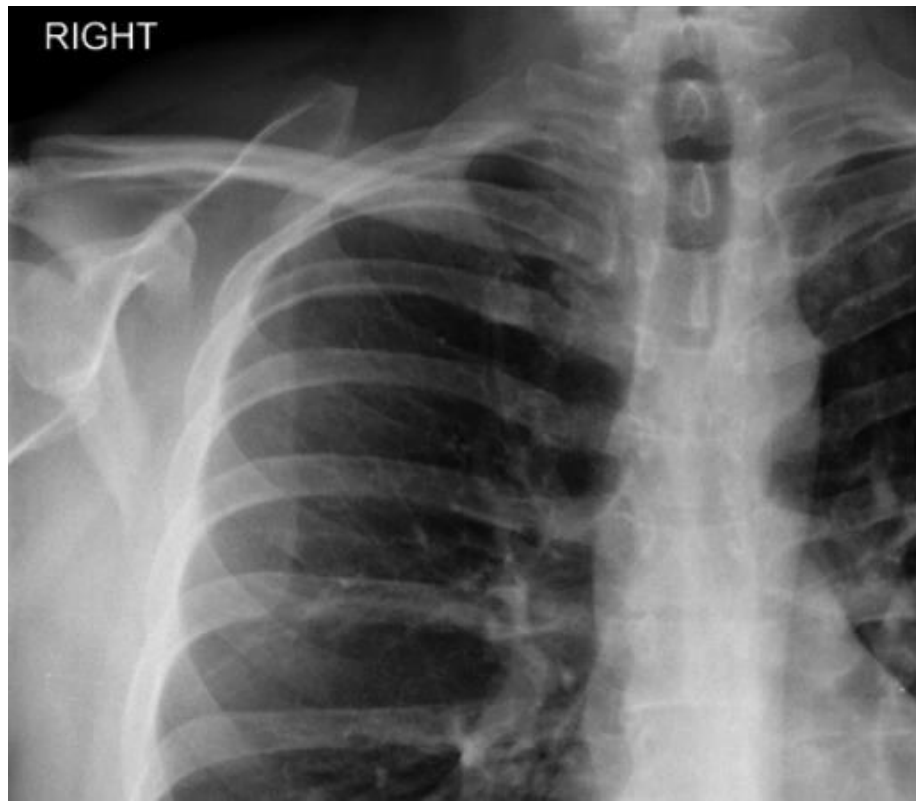
- **1st anterior rib** crosses the clavicle in the middle of its proximal half and usually is clearly visible on PA CXR.



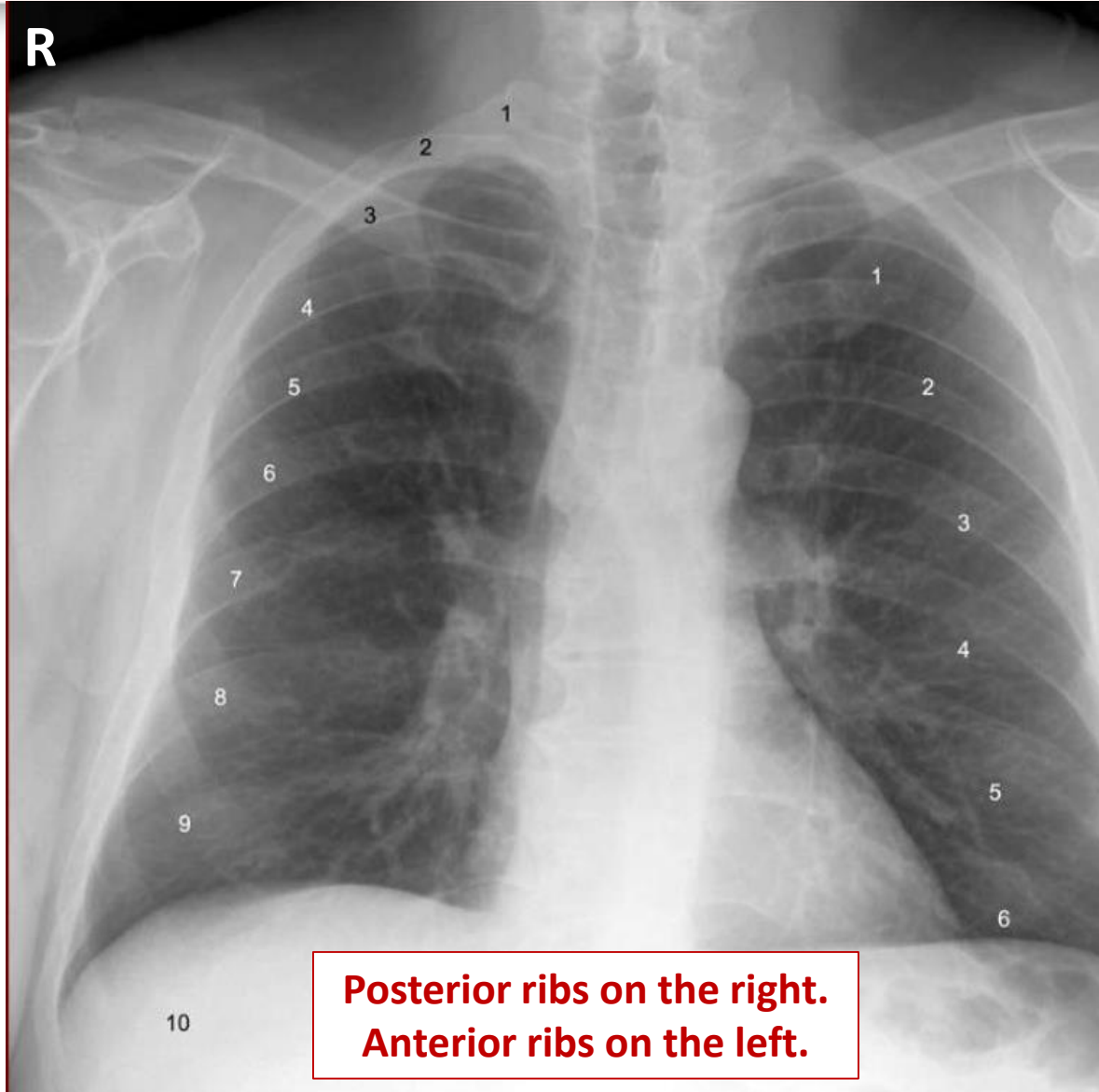
Posterior/anterior ribs



Posterior/anterior ribs



Posterior/anterior ribs



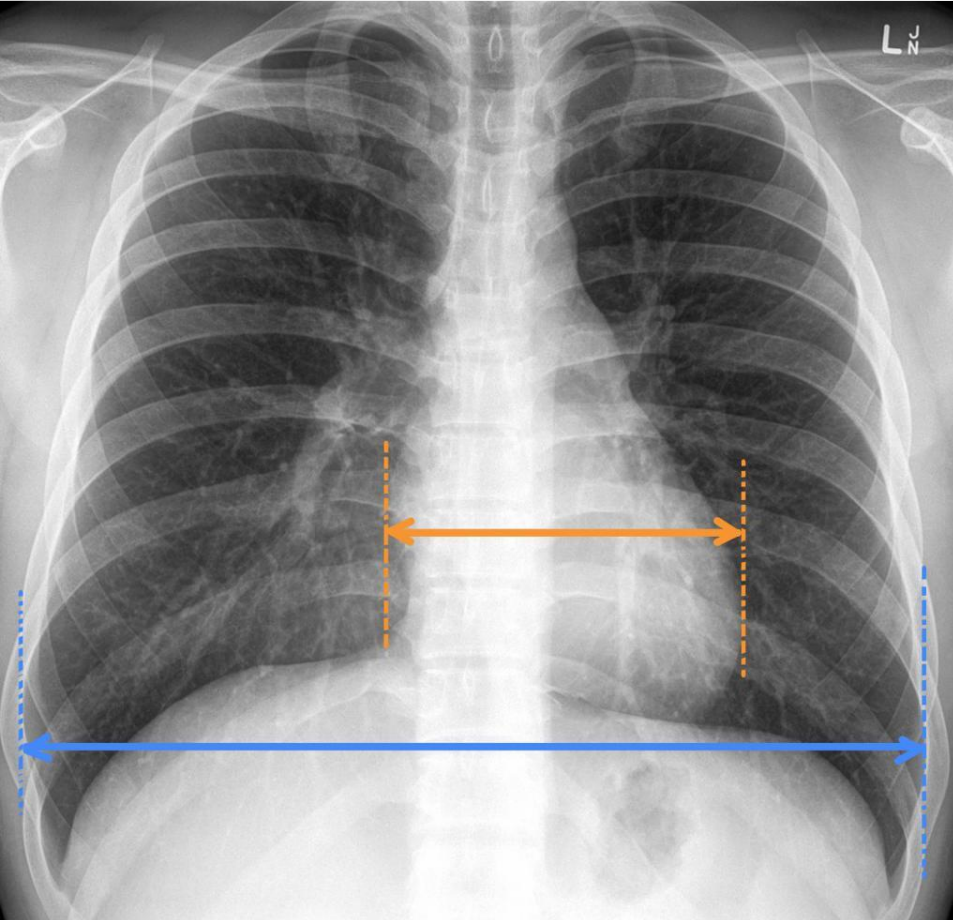
**Posterior ribs on the right.
Anterior ribs on the left.**

Cardiothoracic ratio

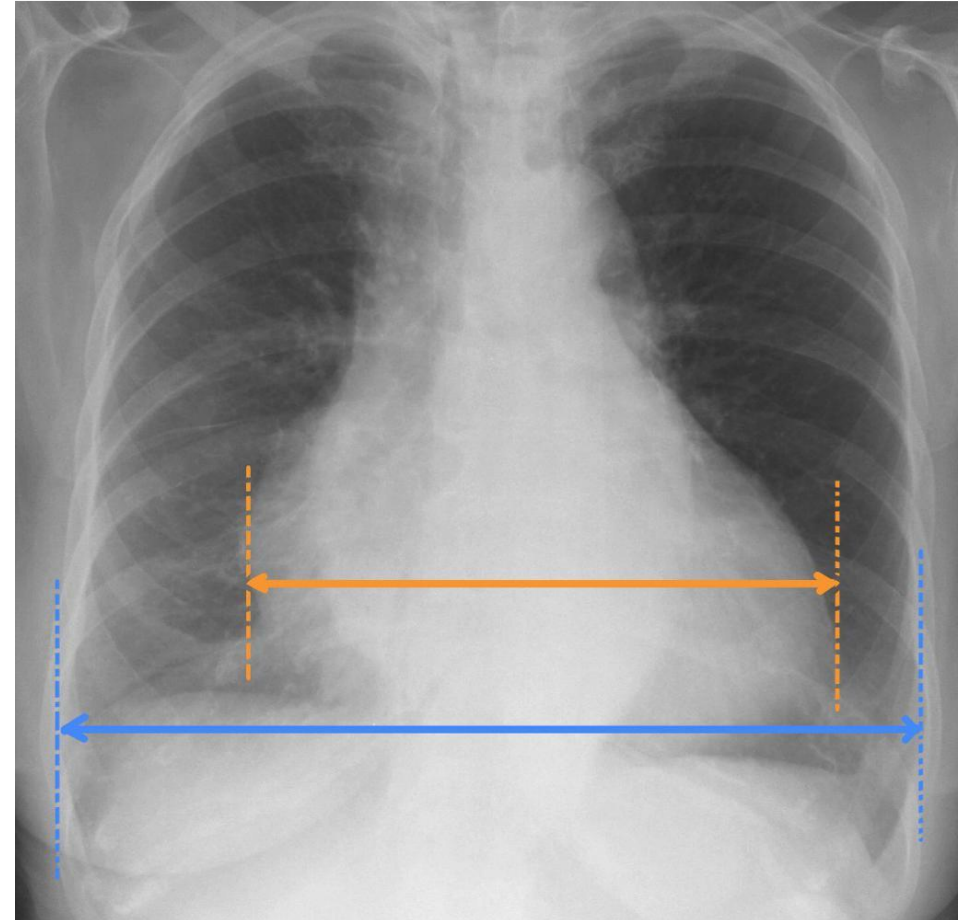


- **Cardiothoracic ratio (CTR)** helps to detect the enlargement of the cardiac silhouette, which is most commonly from *cardiomegaly*, *pericardial effusion (pericarditis/heart tamponade)*, *LV/RV hypertrophy*.
- The CTR is measured on a **PA chest X-ray**.
- It is the ratio of maximal horizontal cardiac diameter to maximal horizontal thoracic diameter (inner edge of ribs / edge of pleura).
A normal measurement should be <0.5.

Cardiothoracic ratio



Normal CTR (< 0.5)



Abnormal CTR (> 0.5)

Rotation

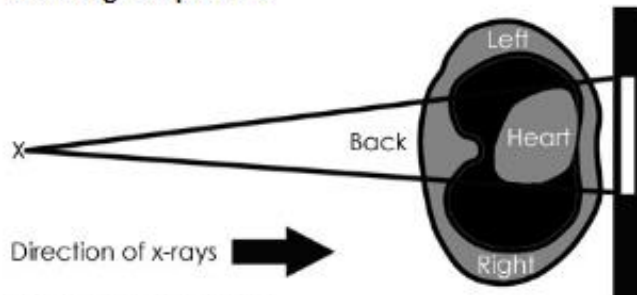


- If the patient is very rotated and you do not recognize this, certain appearances may become misleading.
- The **spinous processes** of the thoracic vertebrae are in the midline at the back of the chest form a vertical line that lies **equidistant from the medial ends of the clavicles**, which are at the front of the chest.
- Rotation of the patient will lead to off-setting of the spinous processes so they lie nearer one clavicle than the other.

Rotation



Well-aligned patient

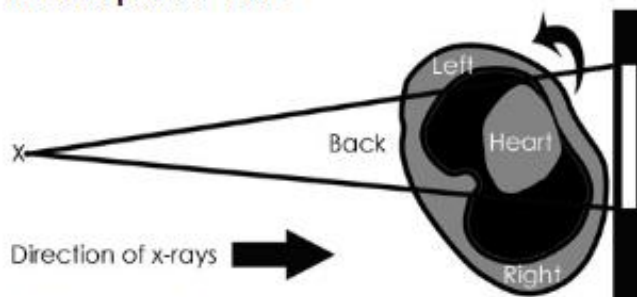


Click image to align with top of page

Well-aligned patient.

An accurate assessment can be made.

Rotated patient - Left

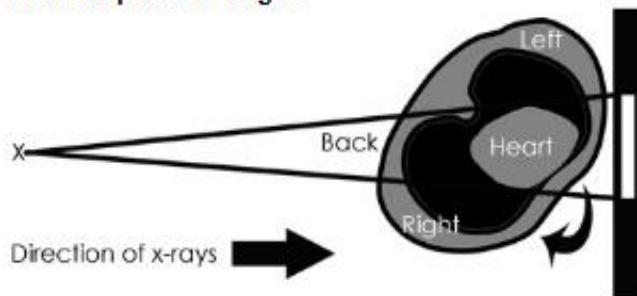


Click image to align with top of page

Rotated patient – Left.

Heart size is exaggerated.

Rotated patient - Right

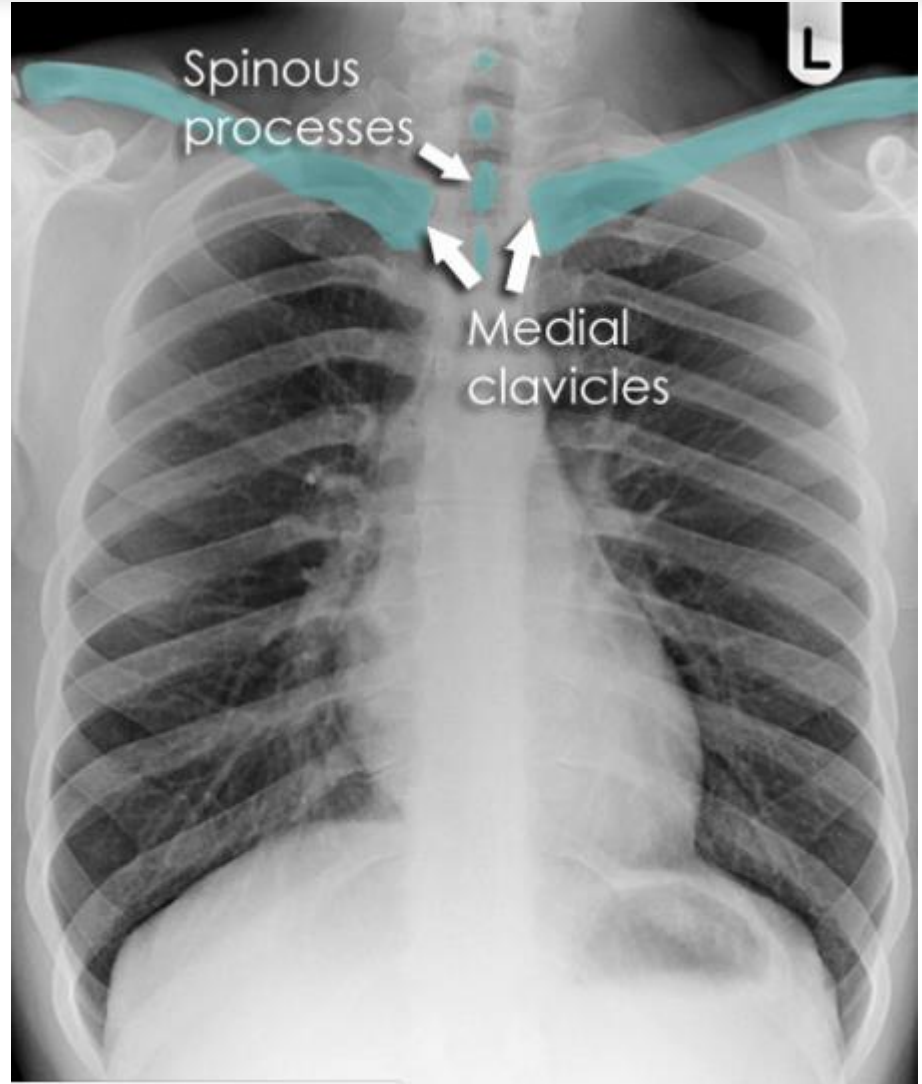
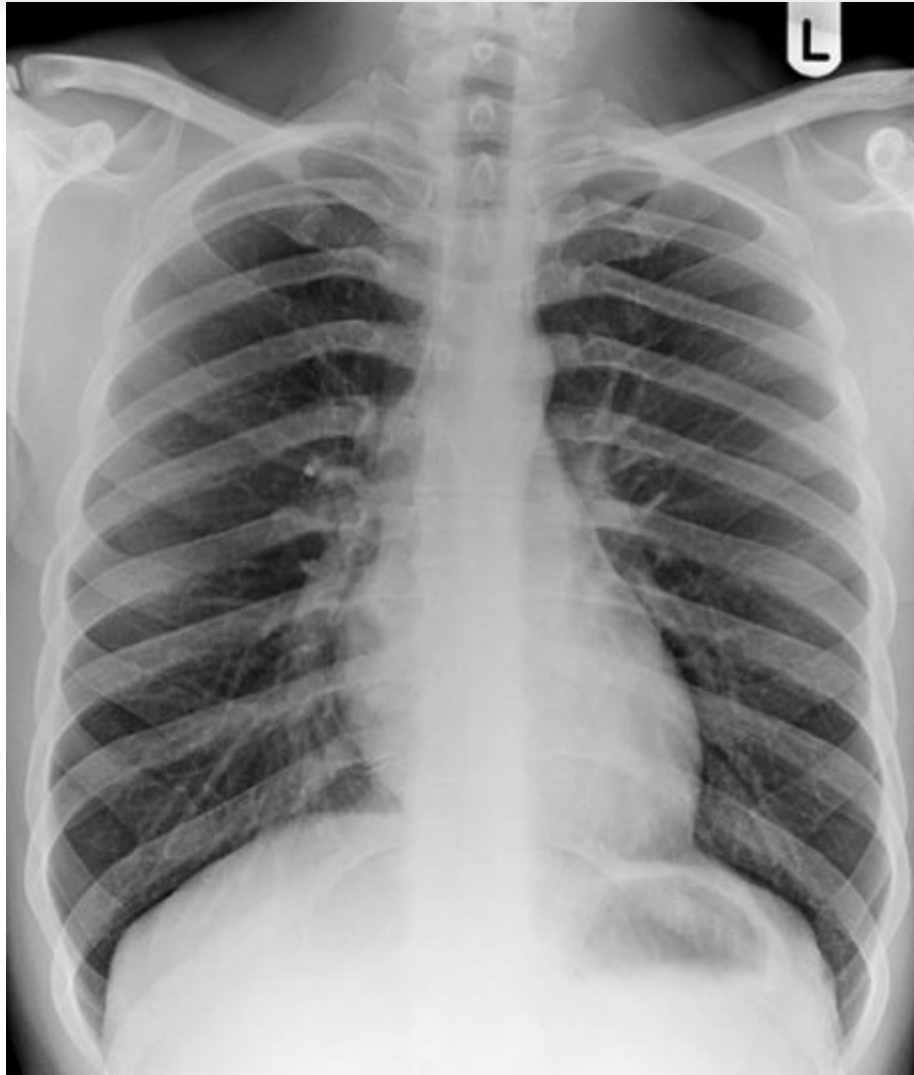

Direction of x-rays

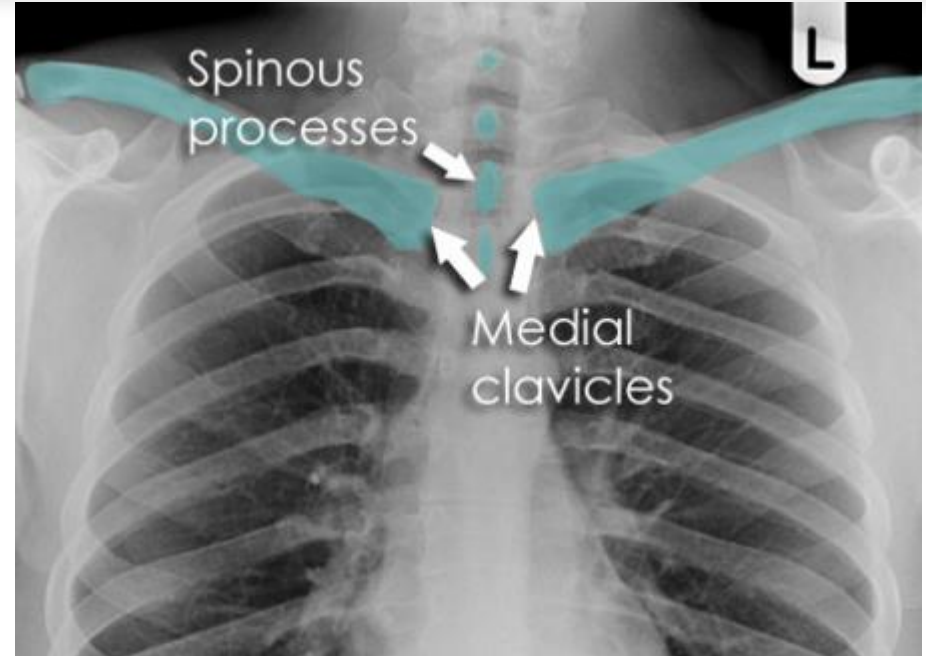
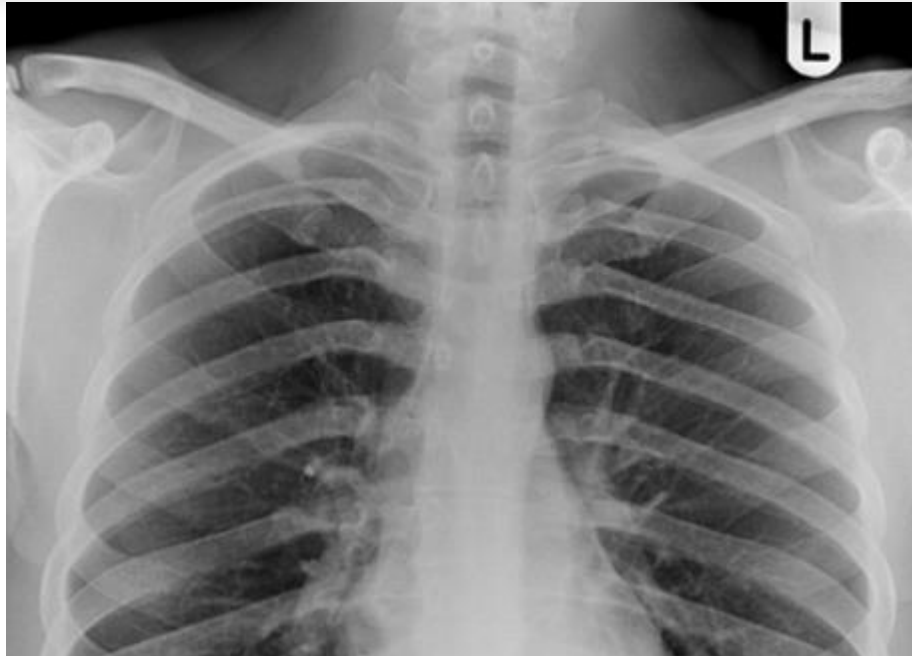Rotated patient – Right.

The true size of the heart may be underestimated.

Rotation



Rotation

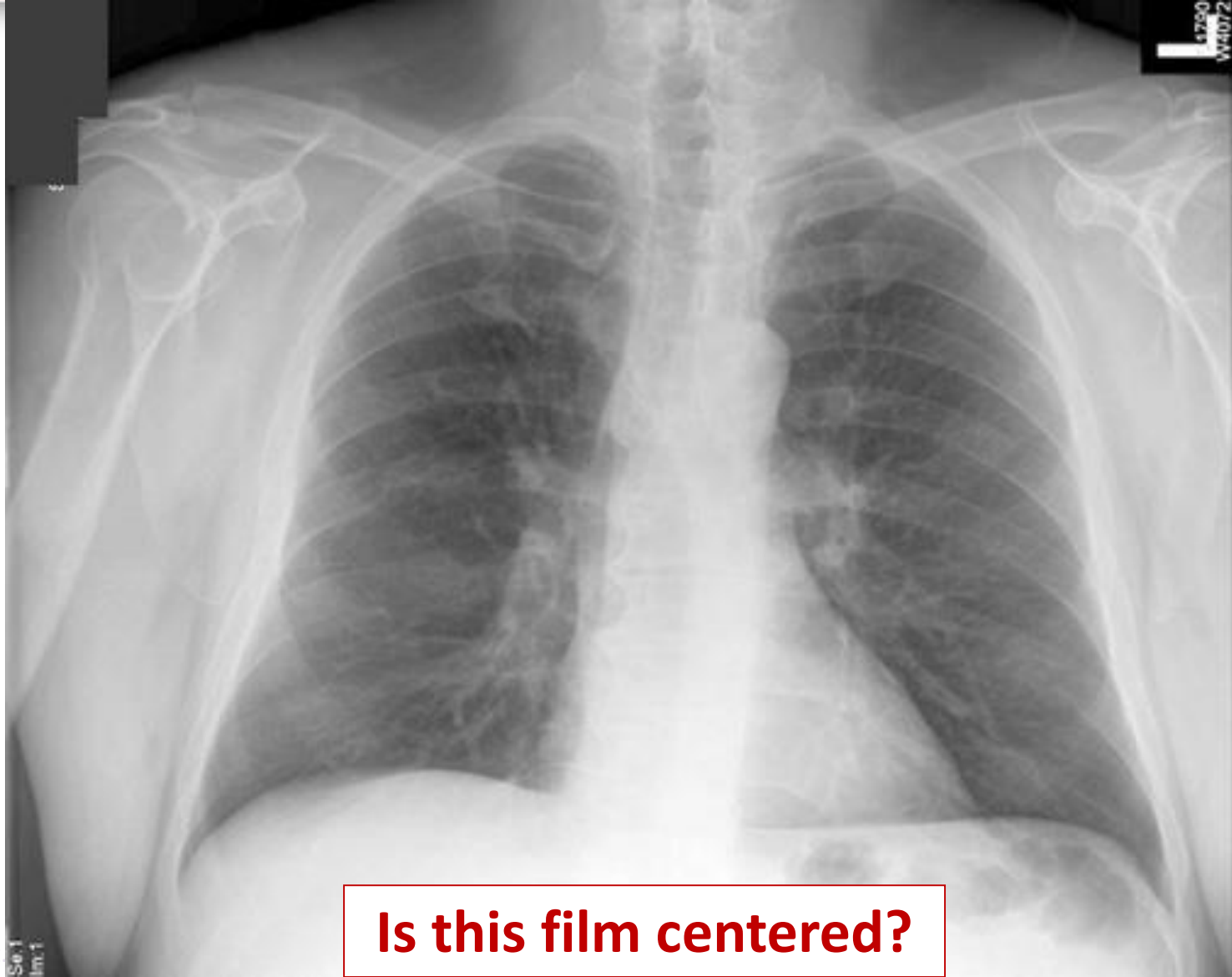


Well-aligned PA chest X-ray

1. Find the medial ends of the clavicles.
2. Find the vertebral spinous processes.
3. The spinous processes should lie half way between the medial ends of the clavicles.

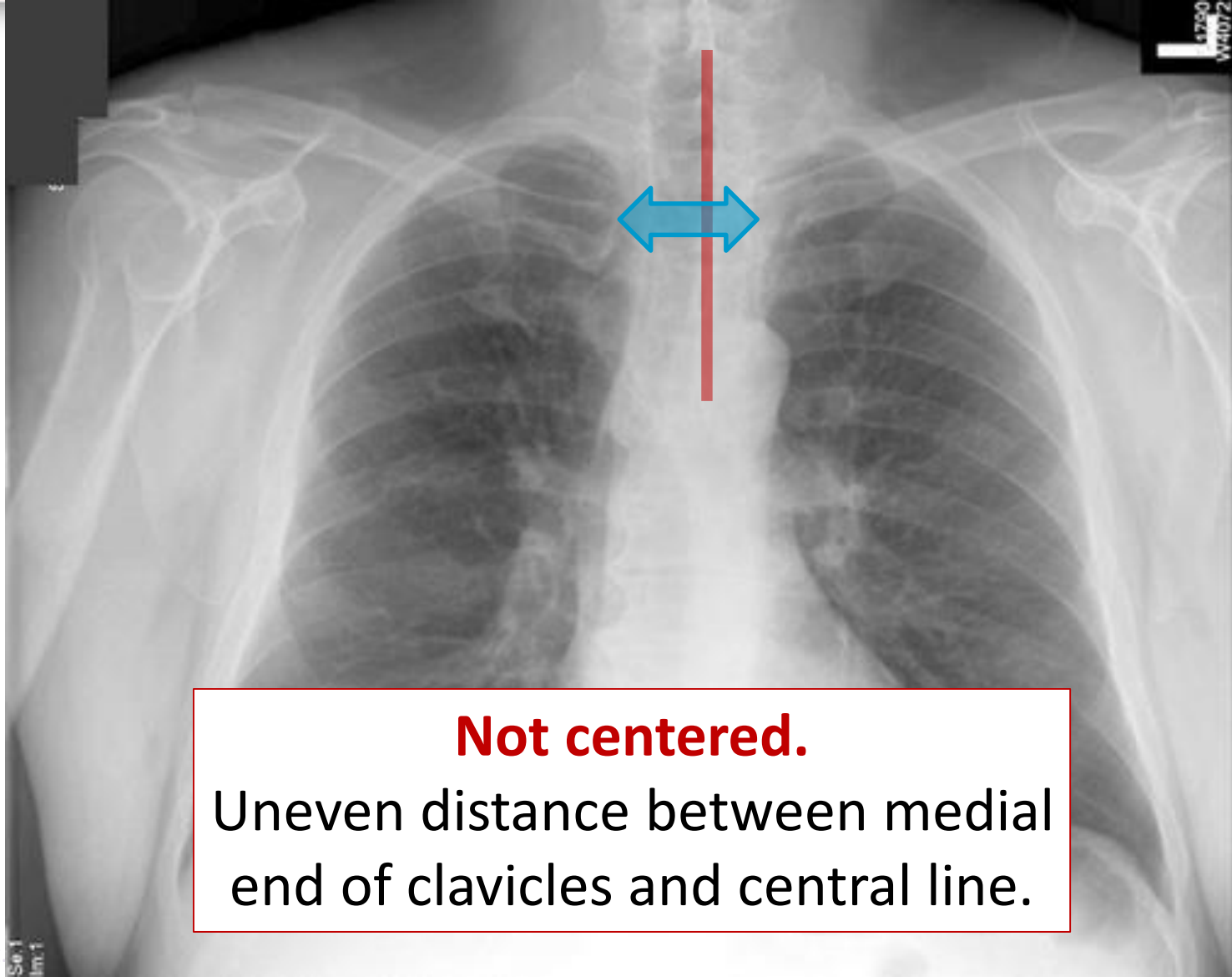


Rotation



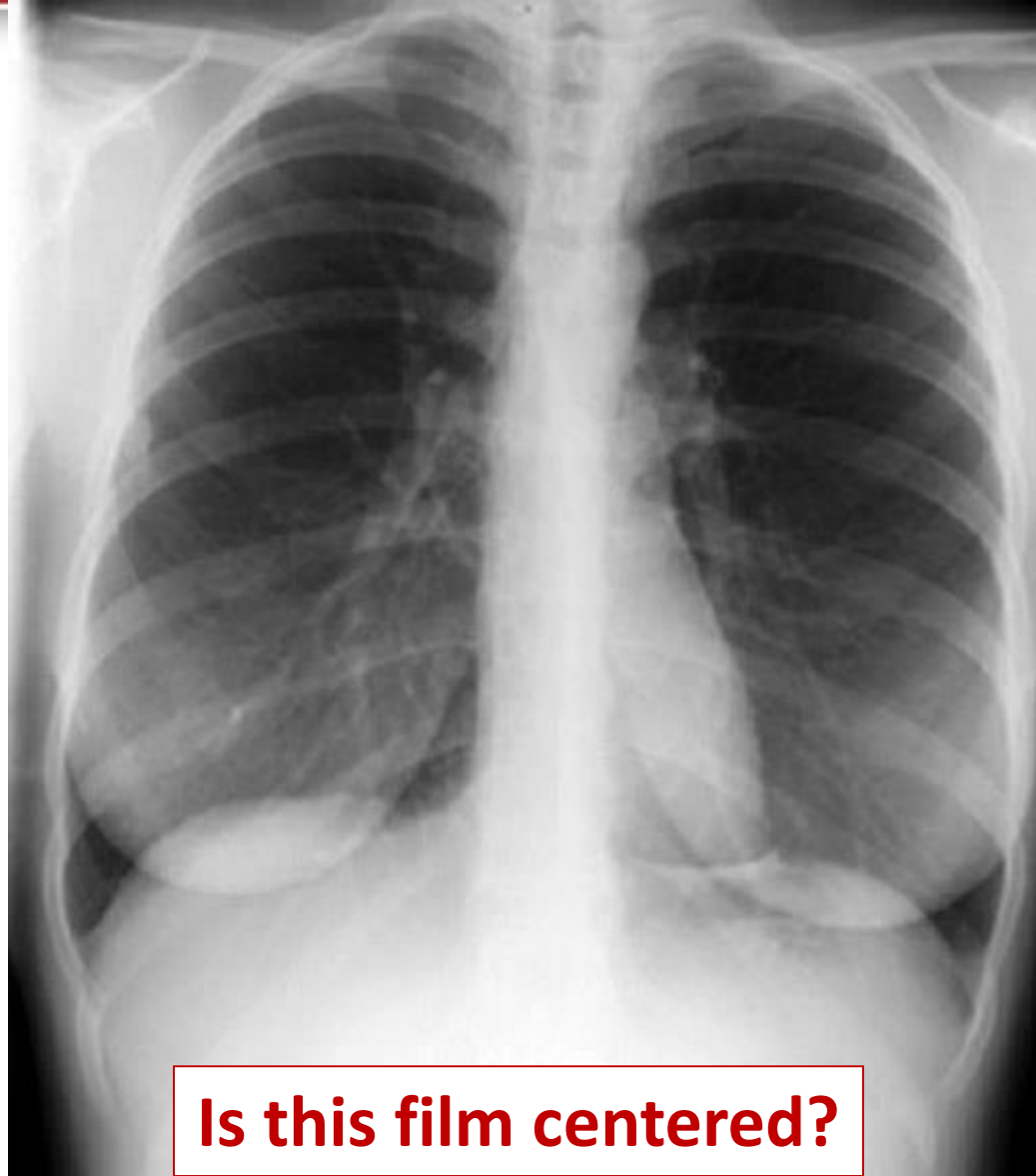
Is this film centered?

Rotation



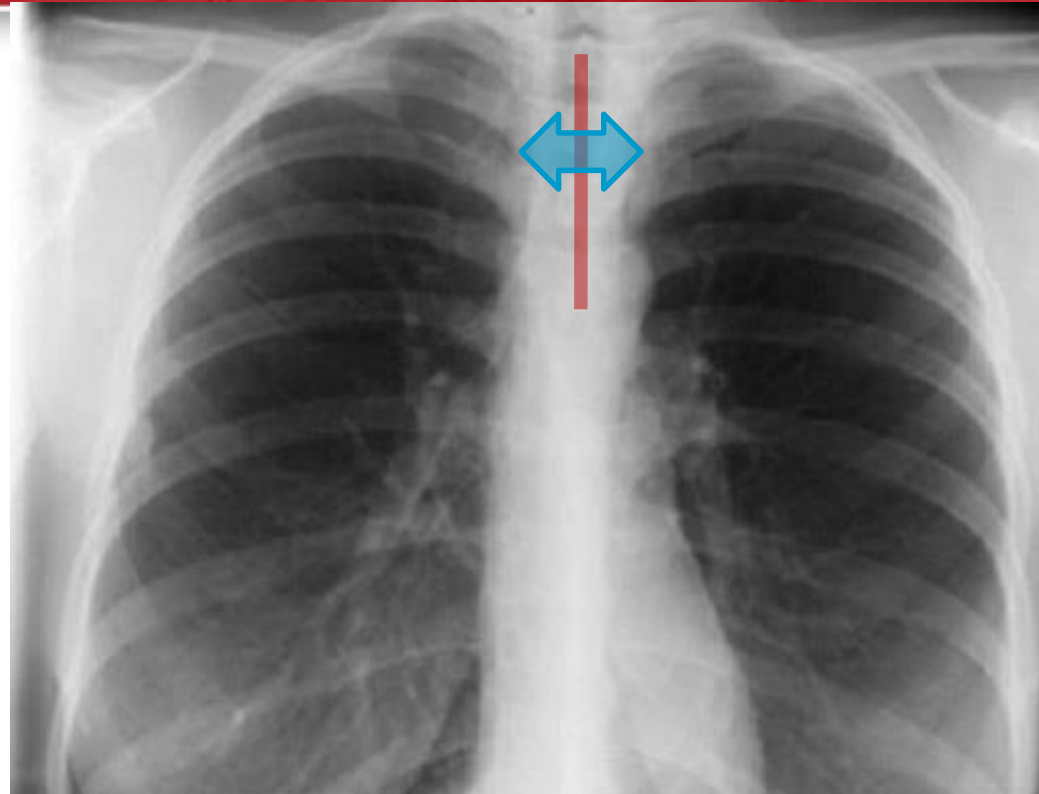
Not centered.
Uneven distance between medial end of clavicles and central line.

Rotation



Is this film centered?

Rotation

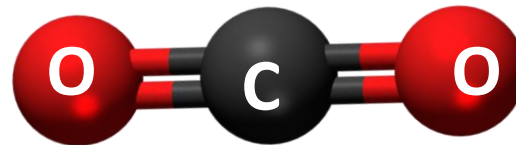
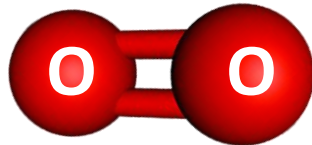


Centered.
Equal distance between
medial end of clavicles and
midline.

Inspiration



- Chest X-rays are conventionally acquired in the **inspiratory phase** of the respiratory cycle which allows to reach **maximal visualization of the lung fields**.
- If the image is acquired in the **expiratory phase**, the lungs are relatively airless and their density is increased. Also, the **raised position of the diaphragm** leads to **exaggeration of heart size**, and **obscuration of the lung bases**.



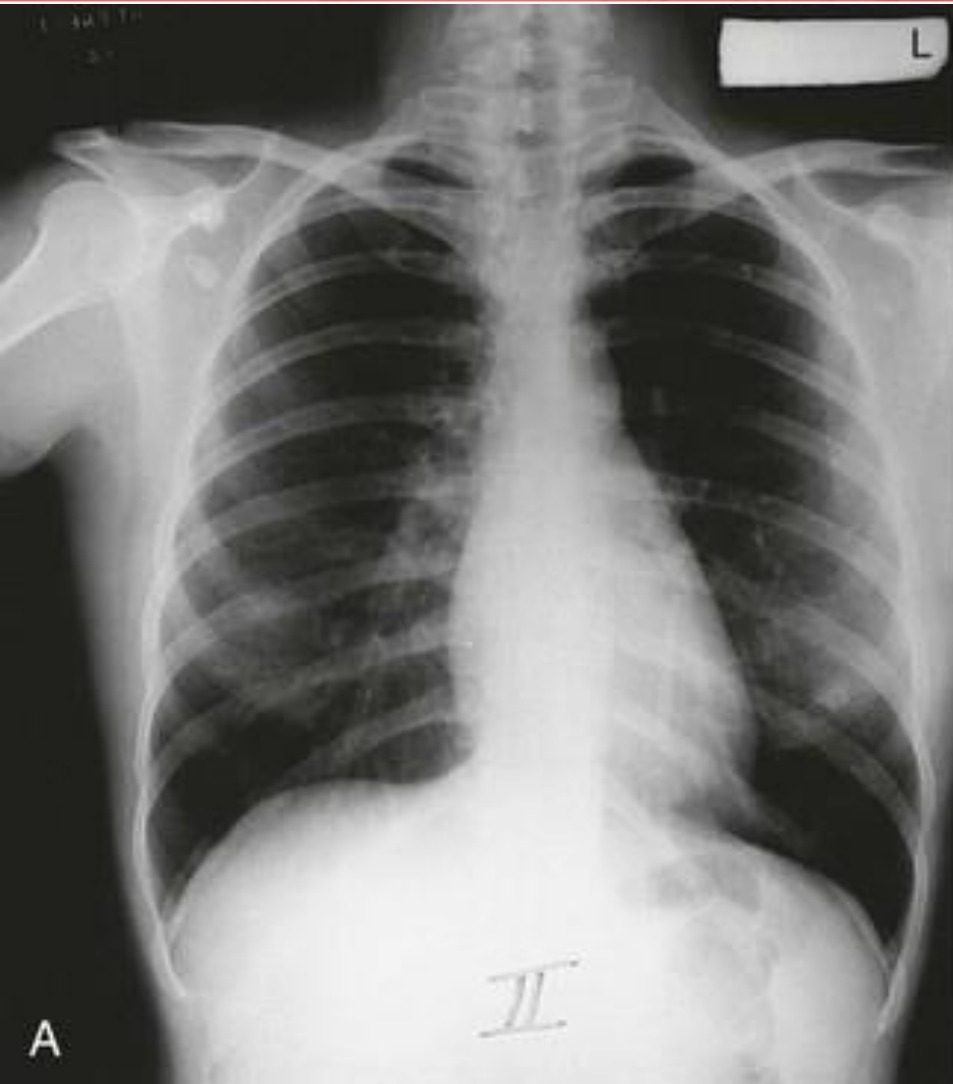Inspiration



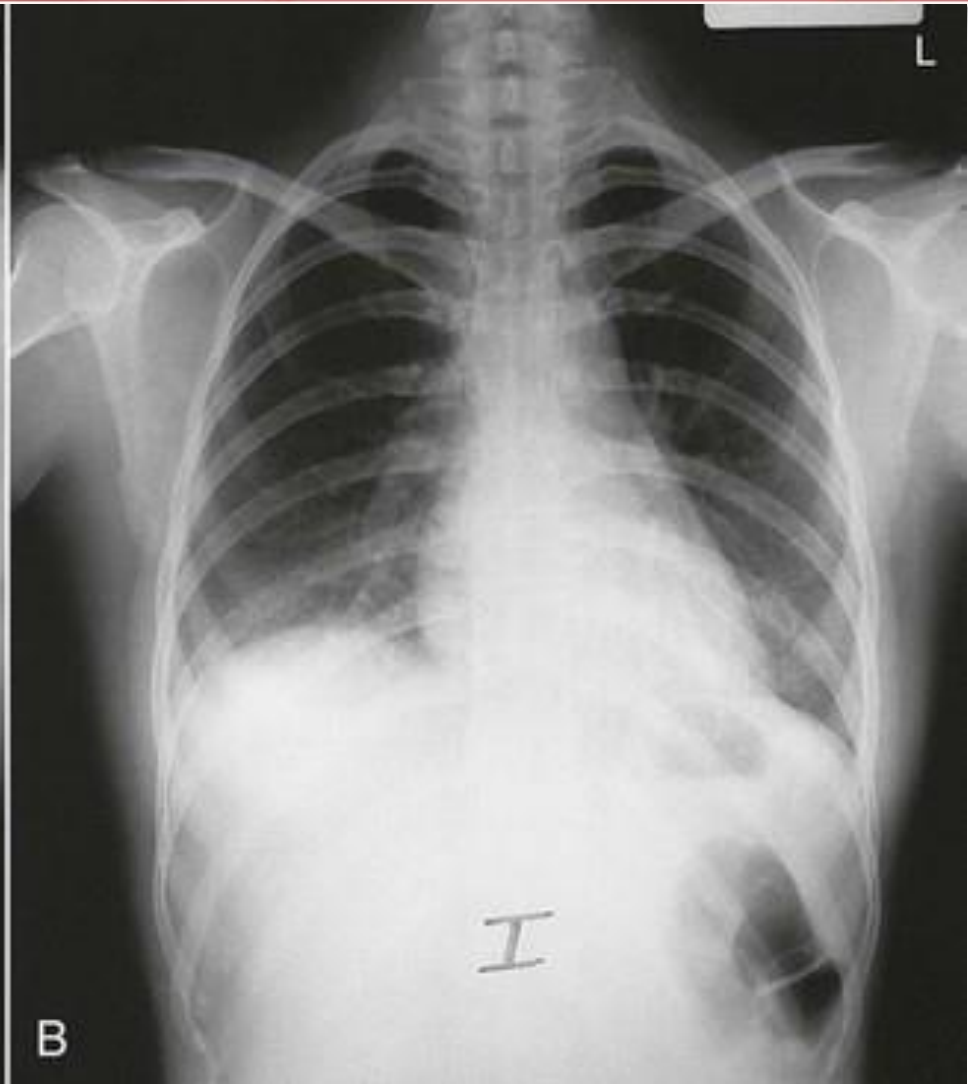- The diaphragm should be intersected by the 5th-7th anterior ribs (8th–10th posterior ribs) in the mid-clavicular line.
- Less is a sign of **incomplete inspiration**.
- More is a sign of **obstructive airways disease**.



Inspiration vs. expiration

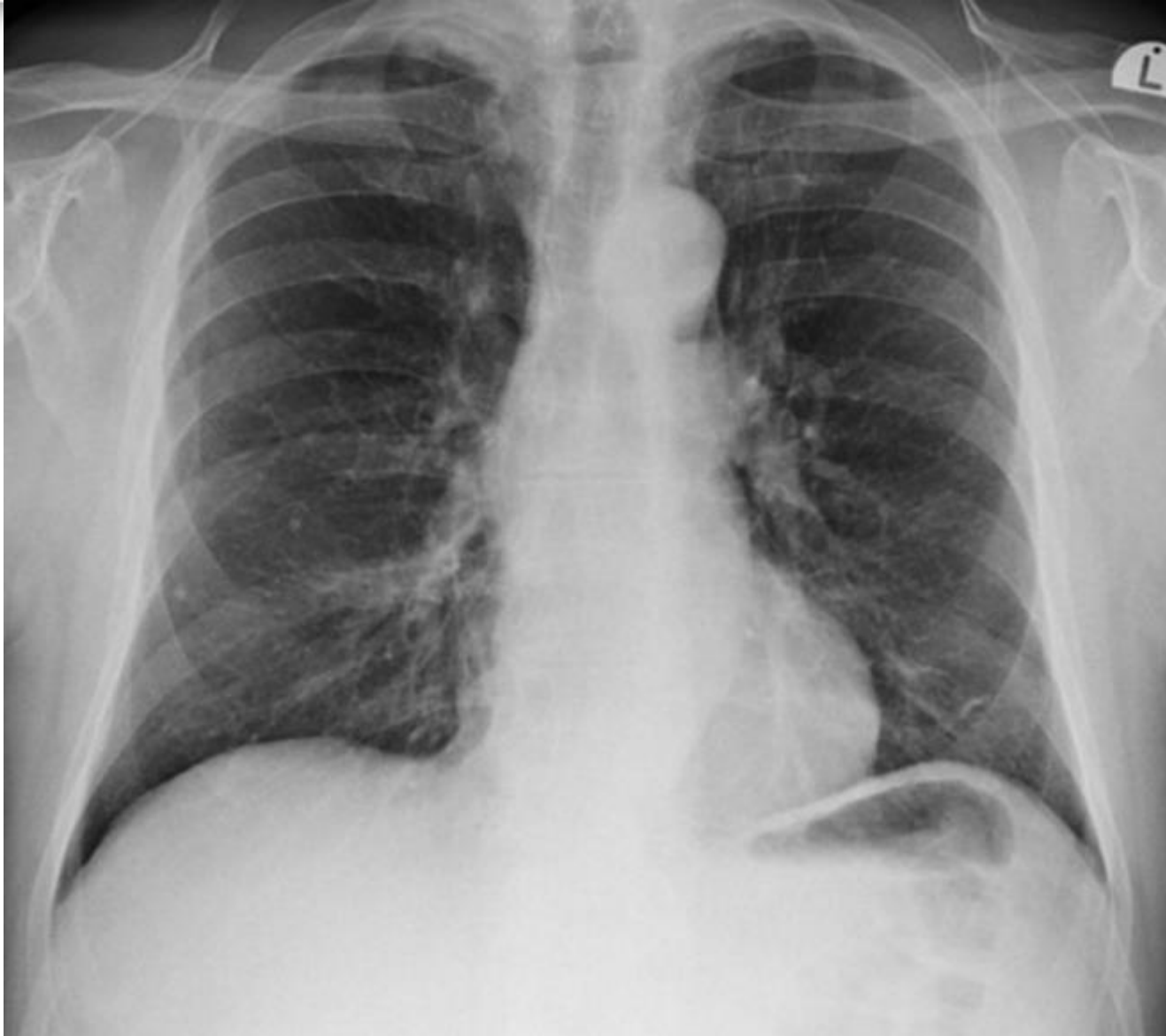

Inspiratory phase

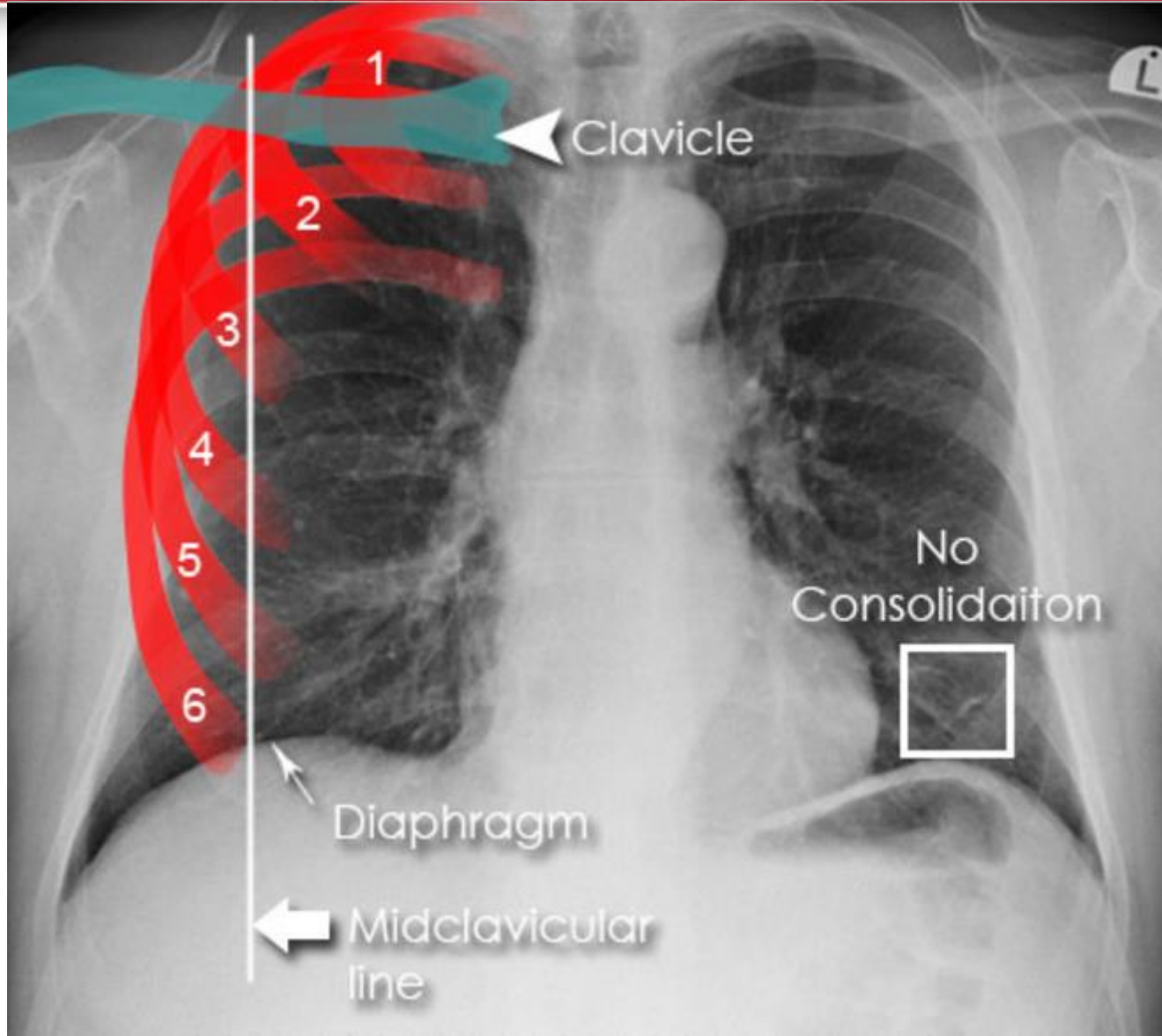


Expiratory phase

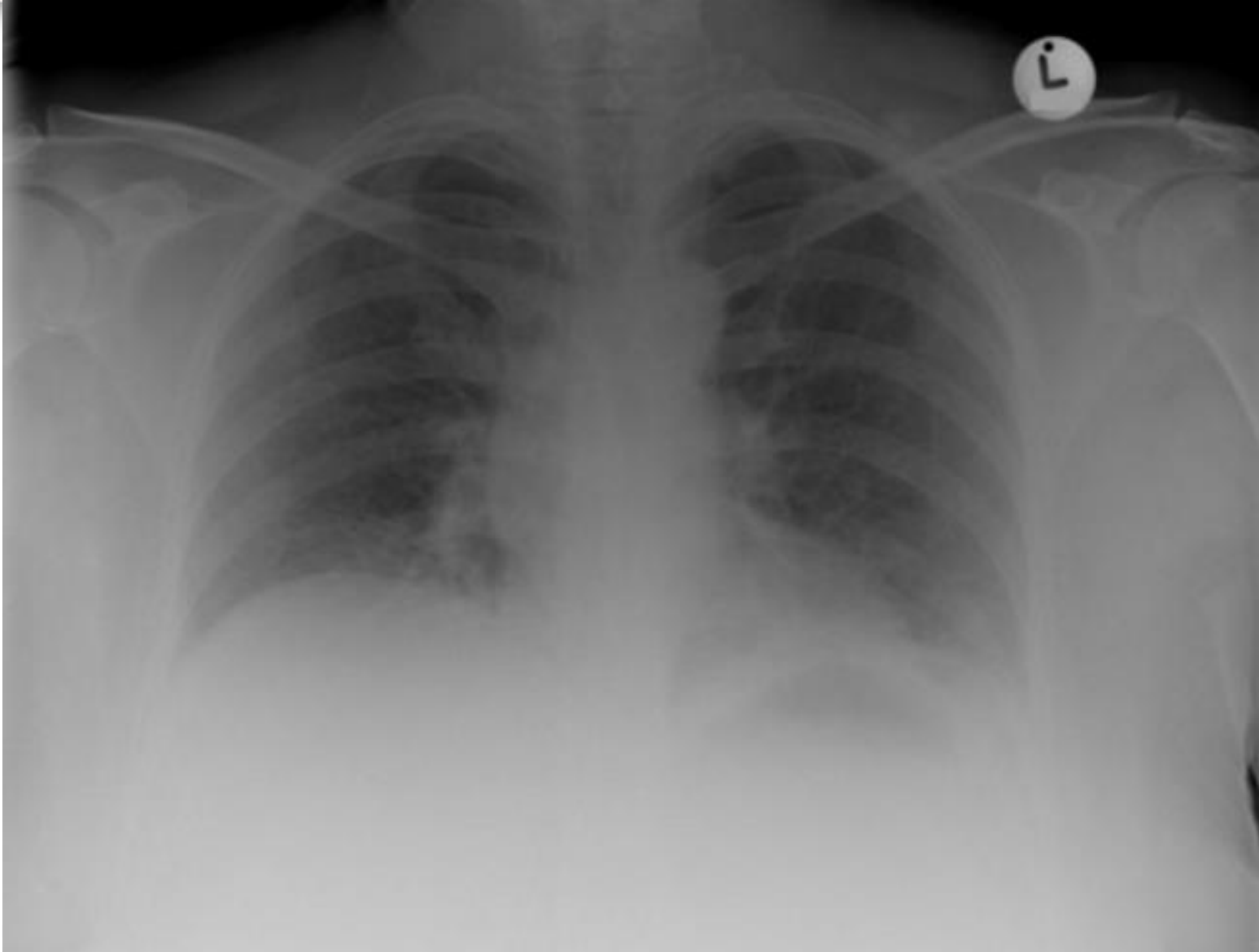Inspiratory phase



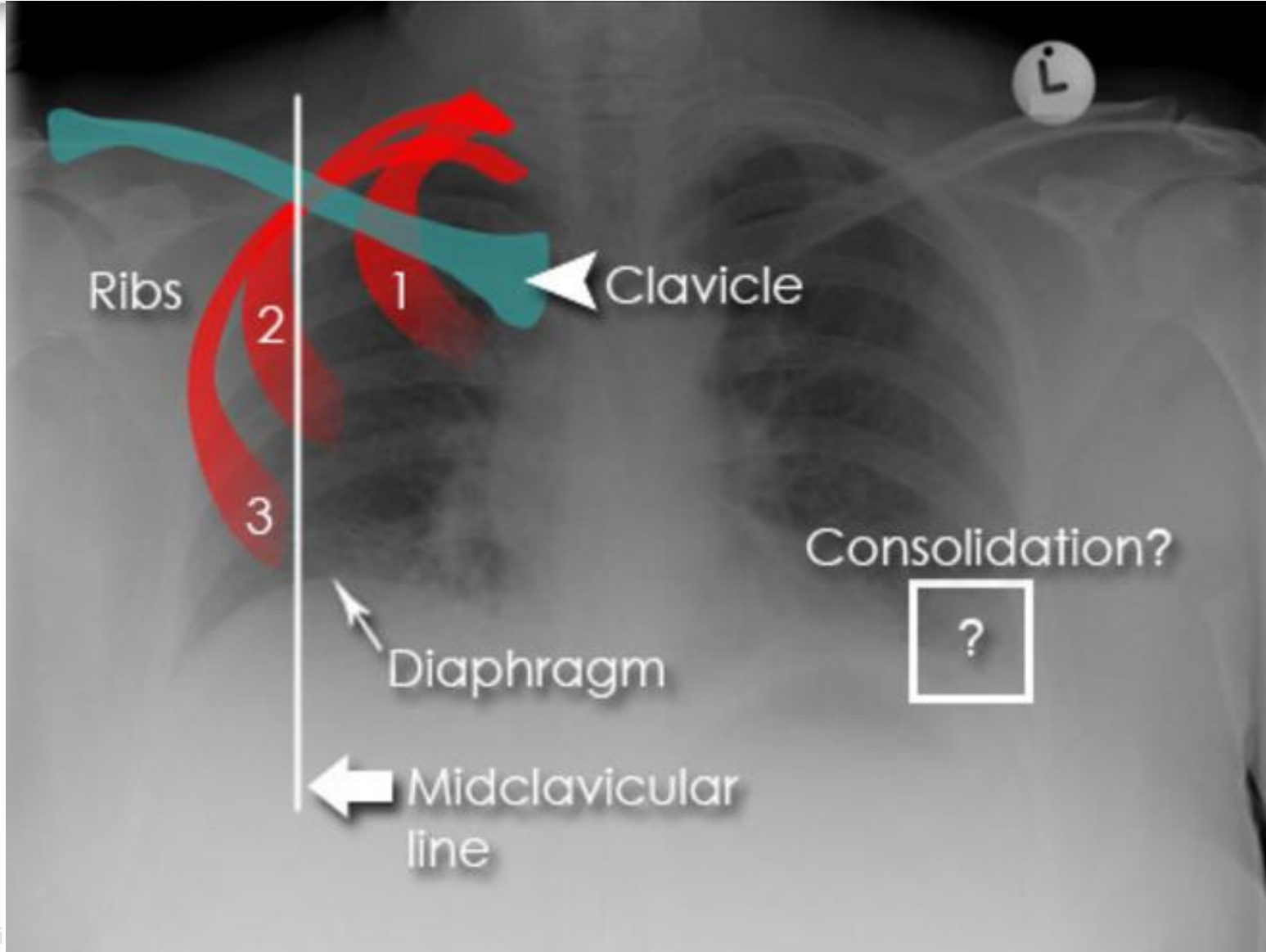
Inspiratory phase



Expiratory phase



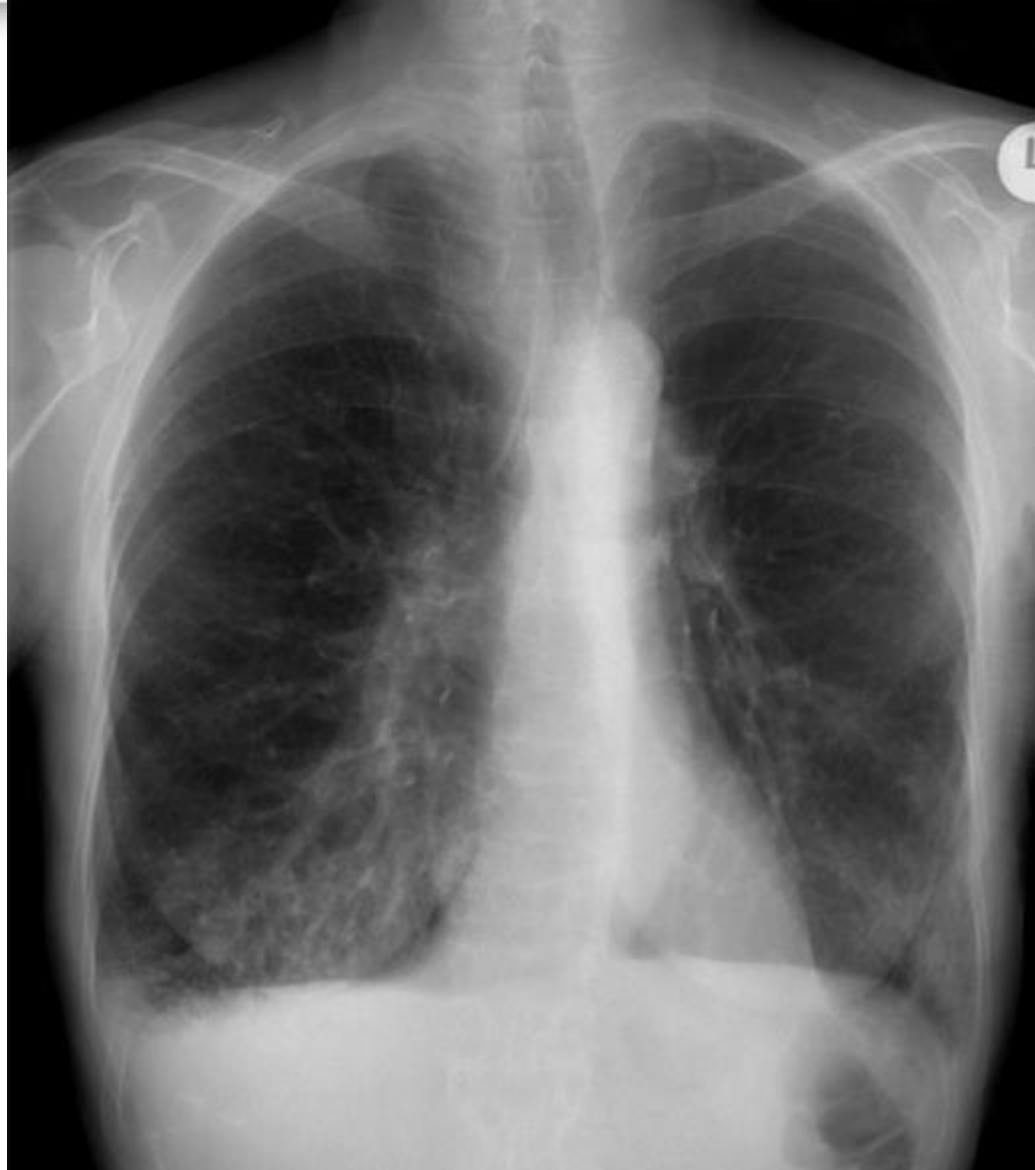
Expiratory phase



Hyperexpansion



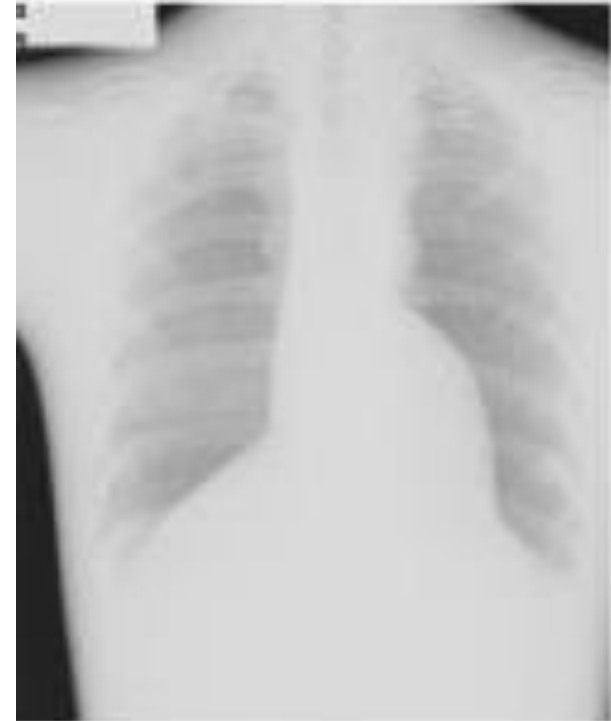- **Hyperexpansion** is diagnosed by **counting ribs** and by checking for **flattening of the hemidiaphragms**.



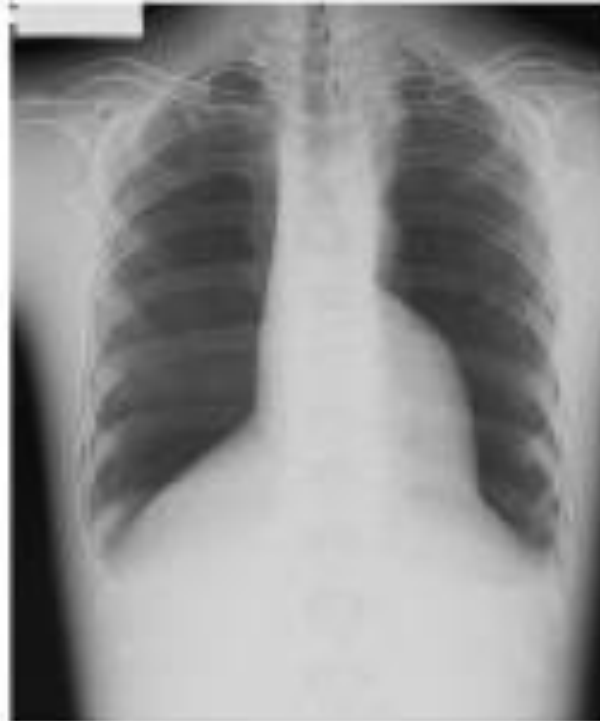Penetration (exposure)



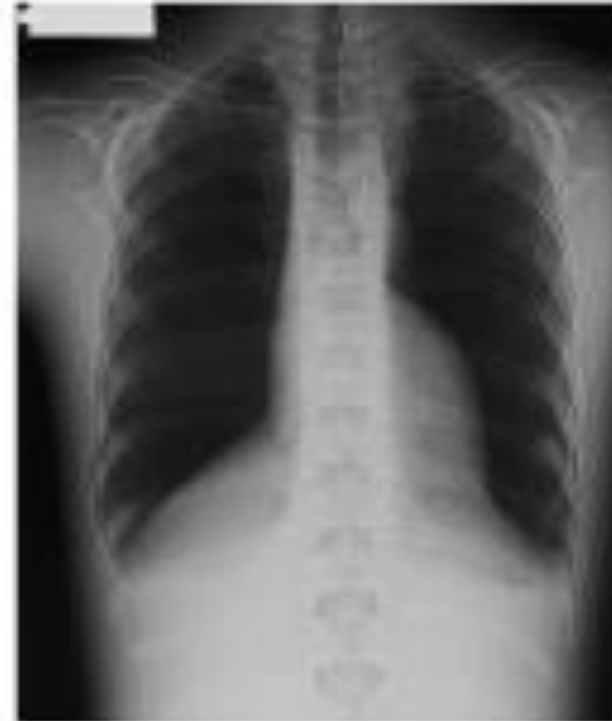- With correct exposure you should **barely see the intervertebral discs through the heart.**
- If you see them very clearly the film is **overpenetrated.**
- If you do not see them it is **underpenetrated.**



Underexposed



Optimal



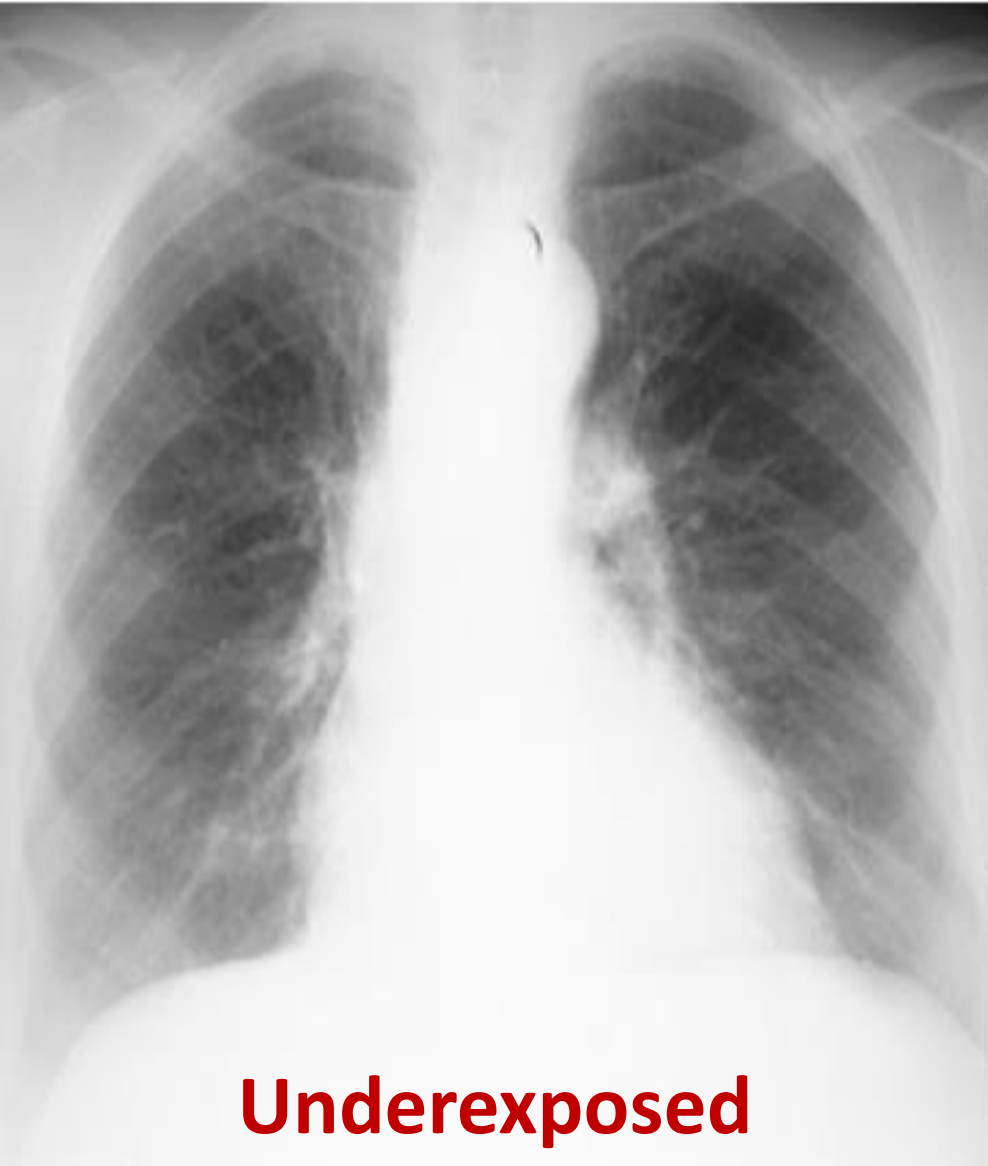Overexposed

Penetration (exposure)

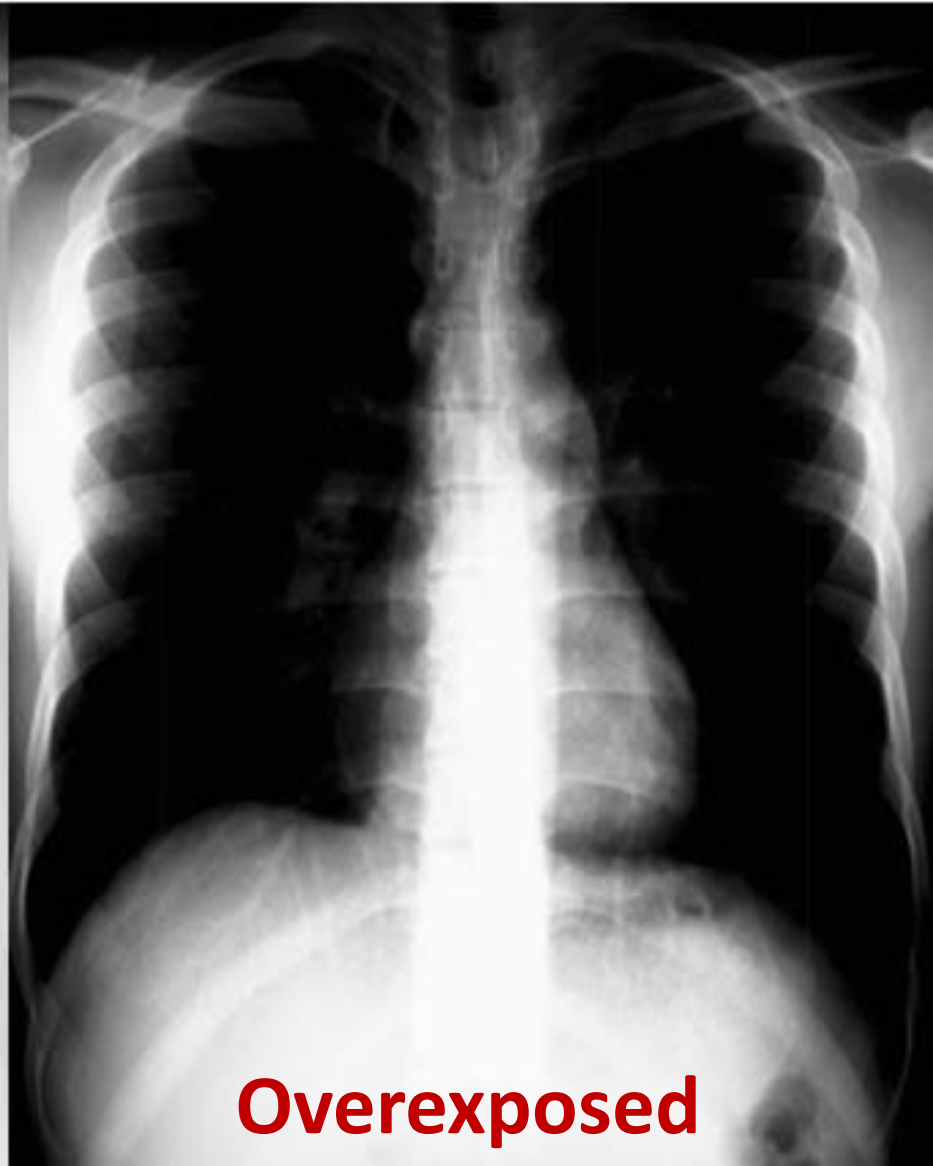

- An **under-penetrated (underexposed, soft)** film looks **diffusely opaque (too white)**, structures behind the heart are obscured, and left lower lobe pathology may be easily missed.
- An **over-penetrated (overexposed, hard)** film looks **diffusely lucent (too black)**, the lungs appear blacker than usual and the vascular markings and lung detail are poorly seen.

Penetration (exposure)



Underexposed



Overexposed

DRSABCDE approach



D	Details Patient Name, DOB, Date, Film Type
R	RIPE Image Rotation, Inspiration, Picture, Exposure (Penetration)
S	Soft Tissues & Bones
A	Airways & Mediastinum
B	Breathing Lung fields & Pleura
C	Circulation Heart position, borders, shape, size
D	Diaphragm
E	Extras ETT, CVP line, NG tube, PA catheters, ECG electrodes, PICC line, chest tube, PPM, AIDC, metalwork

D - Details



- Patient name, age / DOB, sex
- Type of film – PA or AP, erect or supine, correct L/R marker, inspiratory/expiratory series
- Date and time of study



R – RIP



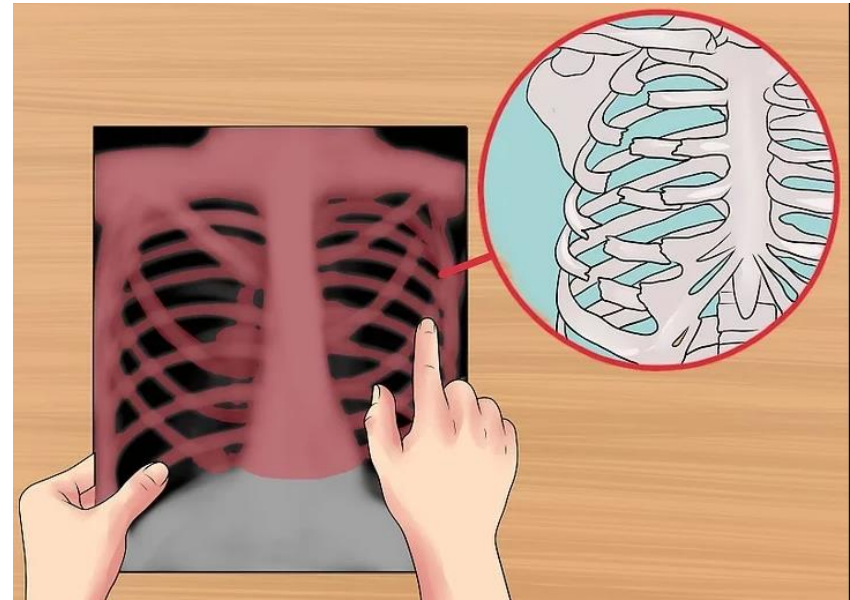
- **Rotation** – medial clavicle ends equidistant from spinous process
- **Inspiration** – 5-6 anterior ribs in MCL or 8-10 posterior ribs above diaphragm, poor inspiration?, hyperexpanded?
- **Penetration (Exposure)** – disc spaces, spinous processes to ~T4, hemidiaphragm visible through cardiac shadow.



S – Soft tissues and bones



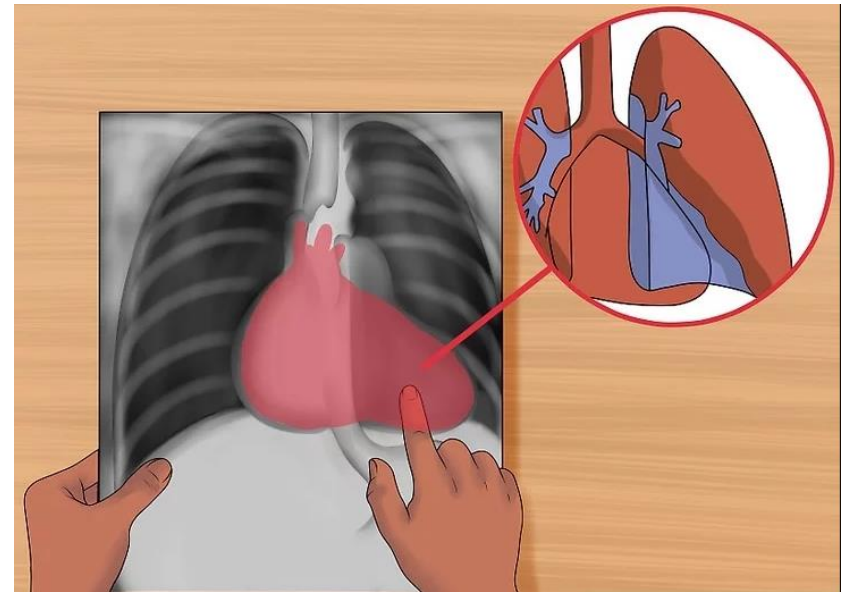
- **Ribs, sternum, spine, clavicles** – symmetry, fractures, dislocations, lytic lesions, density
- **Soft tissues** – looking for symmetry, swelling, loss of tissue planes, subcutaneous air, masses
- **Breast shadows**
- **Calcification** – great vessels, carotids



A – Airway & Mediastinum



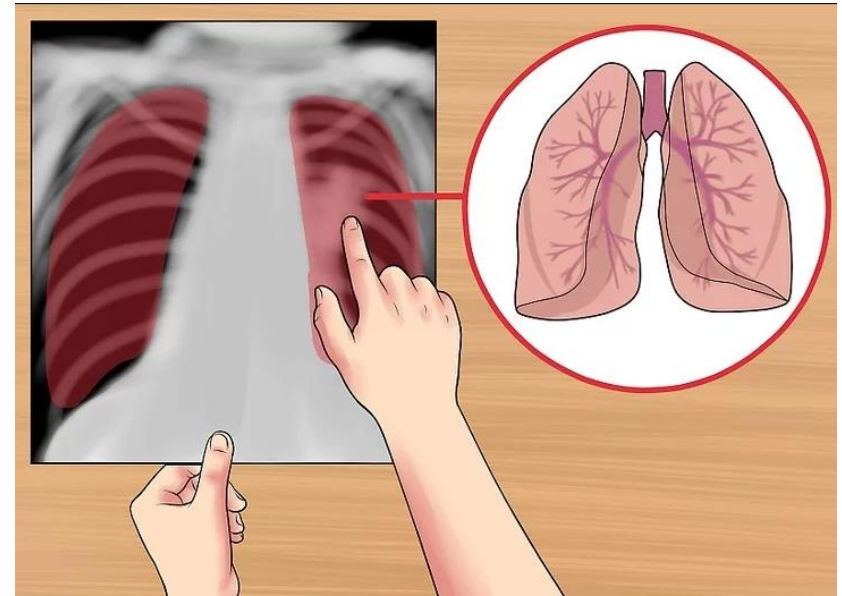
- **Trachea** – central or slightly to right lung as crosses aortic arch
- **Paratracheal/mediastinal masses or adenopathy**
- **Mediastinal width**
- **Aortic knob**
- **Hilum** – T6-7 IV disc level, left hilum is usually higher (2cm) and squarer than the V-shaped right hilum.



B – Breathing



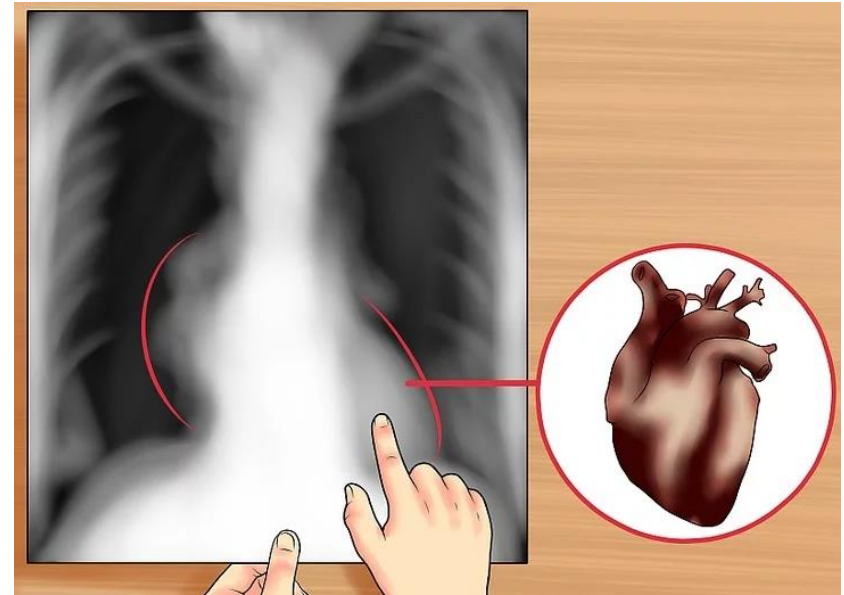
- Lung fields
 - *Vascularity*
 - *Pneumothorax* – don't forget apices
 - *Lung field outlines* – abnormal opacity/lucency, atelectasis, collapse, consolidation, bullae
 - *Horizontal fissure* on Right Lung
 - *Pulmonary infiltrates* – interstitial vs alveolar pattern
 - *Coin lesions*
 - *Cavitary lesions*
- Pleura



C – Circulation



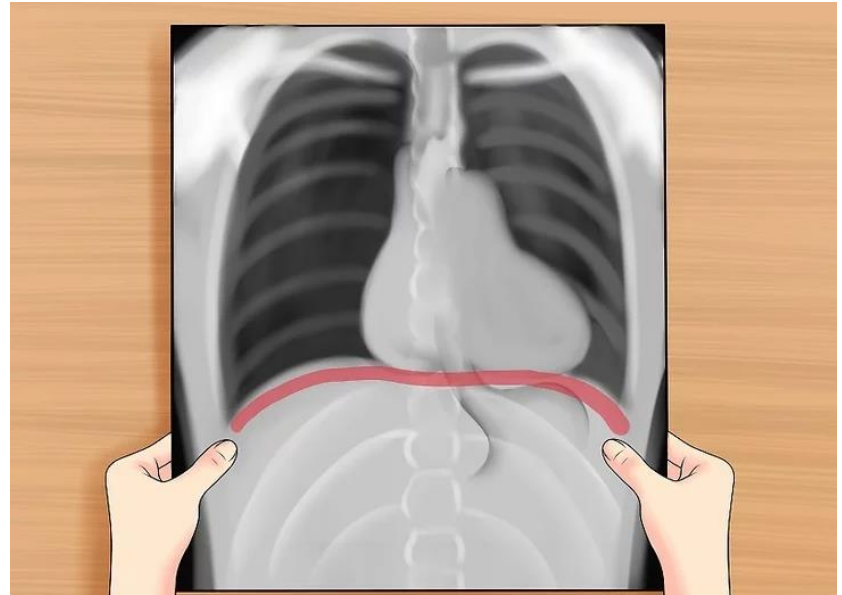
- **Heart position** – $\frac{2}{3}$ to left, $\frac{1}{3}$ to right
- **Heart size** – measure cardiothoracic ratio on **PA** film (normal <0.5)
- **Heart borders** – R border is R atrium, L border is L ventricle & atrium
- **Heart shape**
- **Aortic stripe**



D – Diaphragm



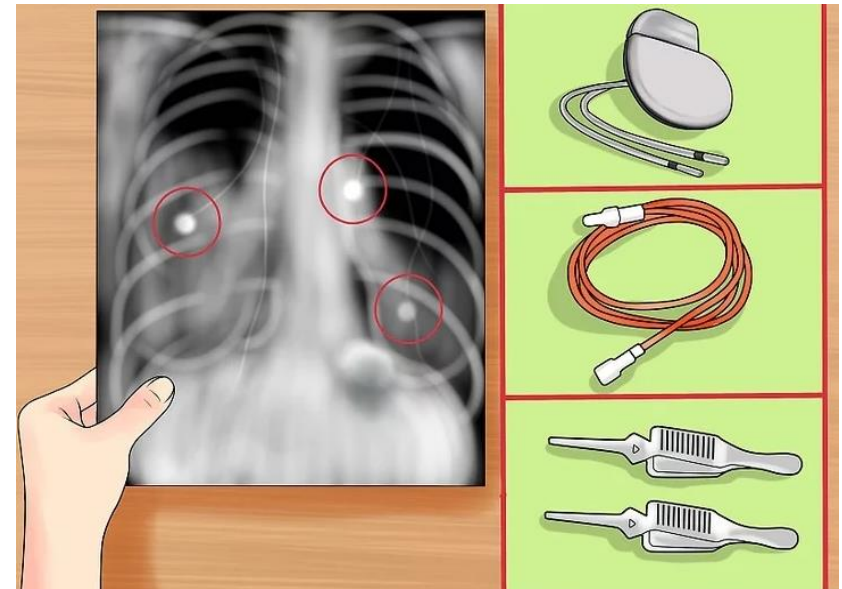
- **Hemidiaphragm levels –**
Right Lung higher than Left Lung (~2.5cm / 1 intercostal space)
- **Diaphragm shape/contour**
- **Cardiophrenic and costophrenic angles –** clear and sharp
- **Gastric bubble / colonic air**
- **Subdiaphragmatic air**
(pneumoperitoneum)



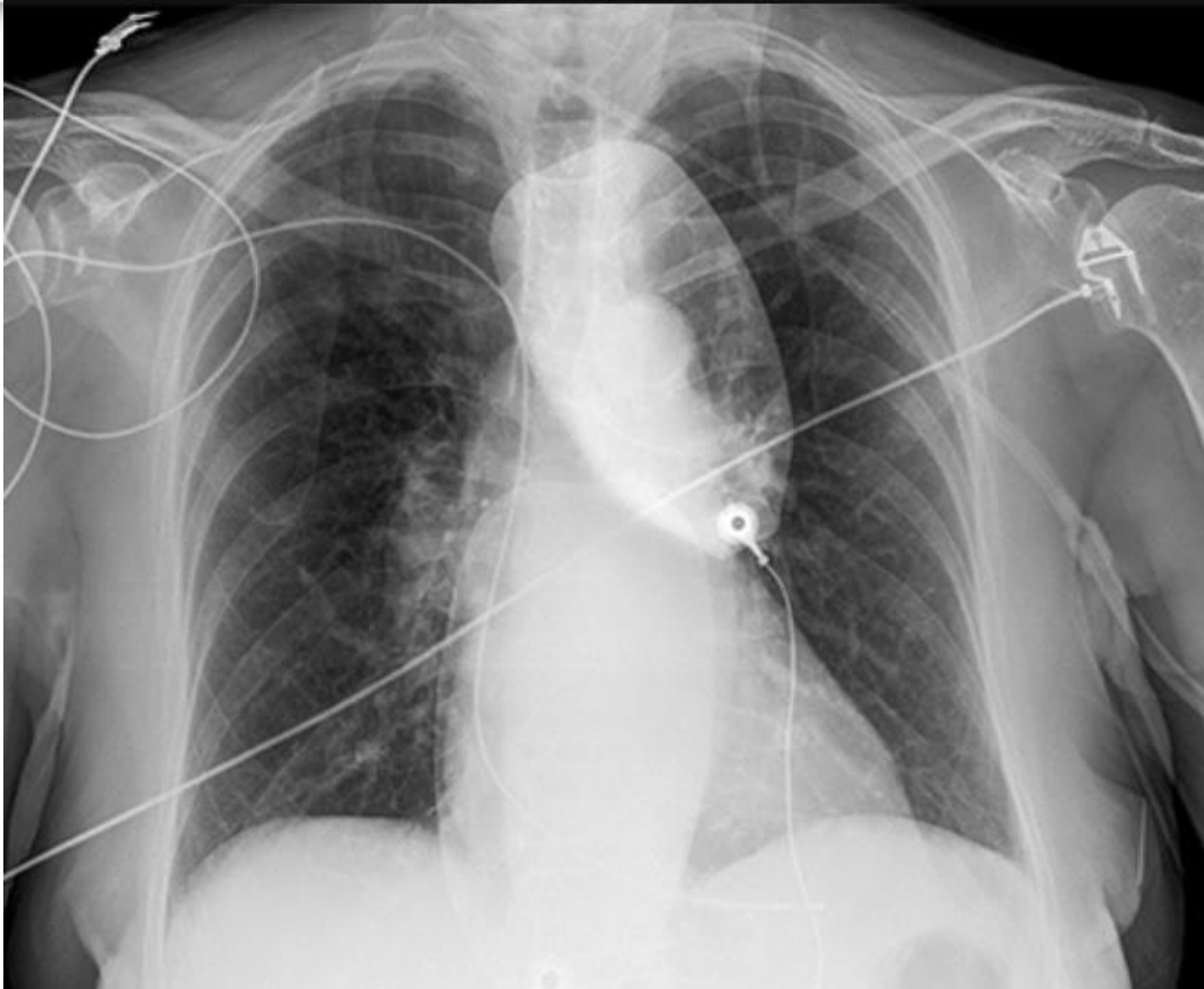
E – Extras (artifacts)



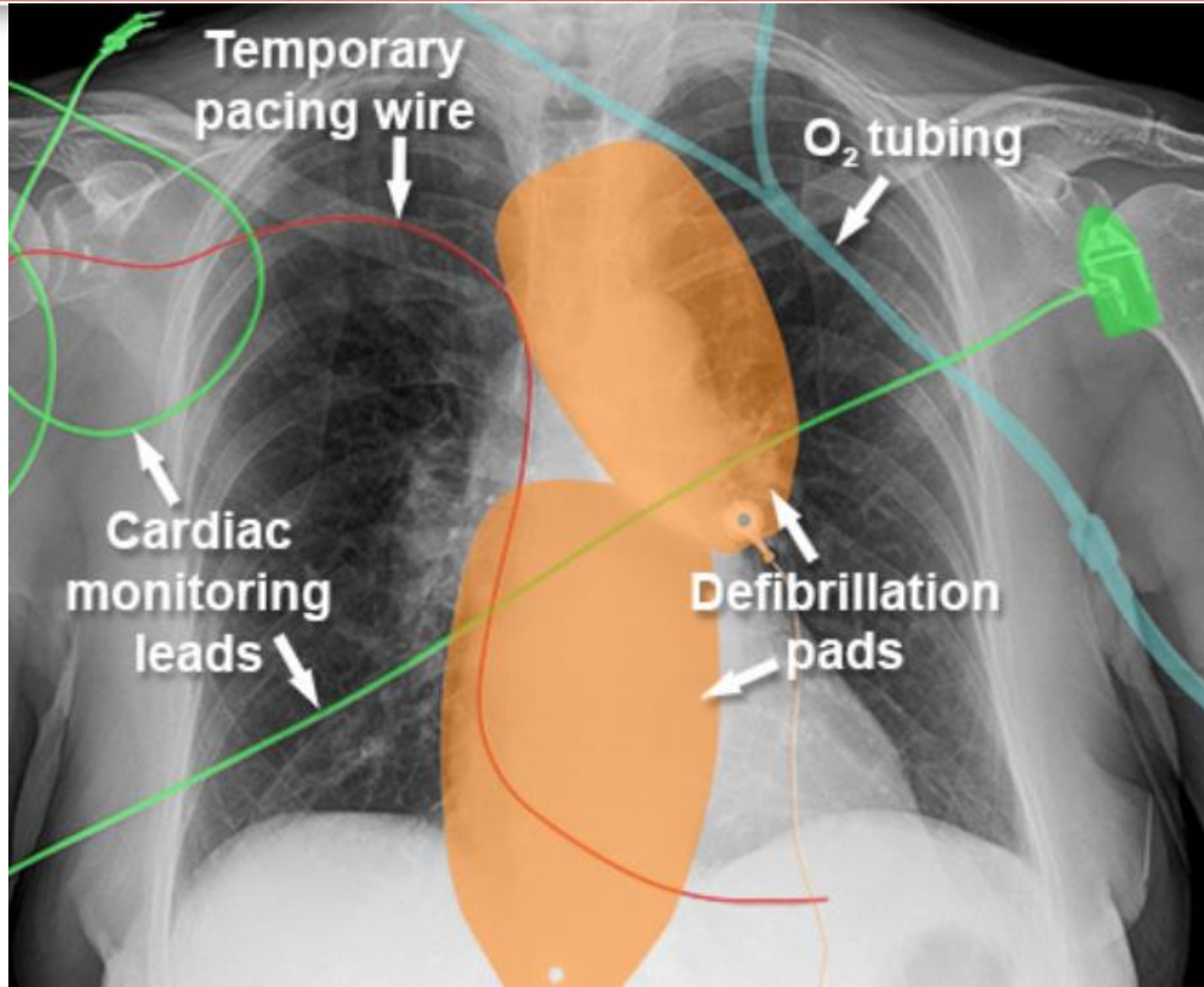
- **Medical ware** (NG tube, PA catheters, ECG electrodes, chest tube, pacemaker, etc)
- **Jewelery, buttons**
- **Gadgets**
(smartphones, MP3-players, etc)



Artifacts: numerous



Artifacts: numerous



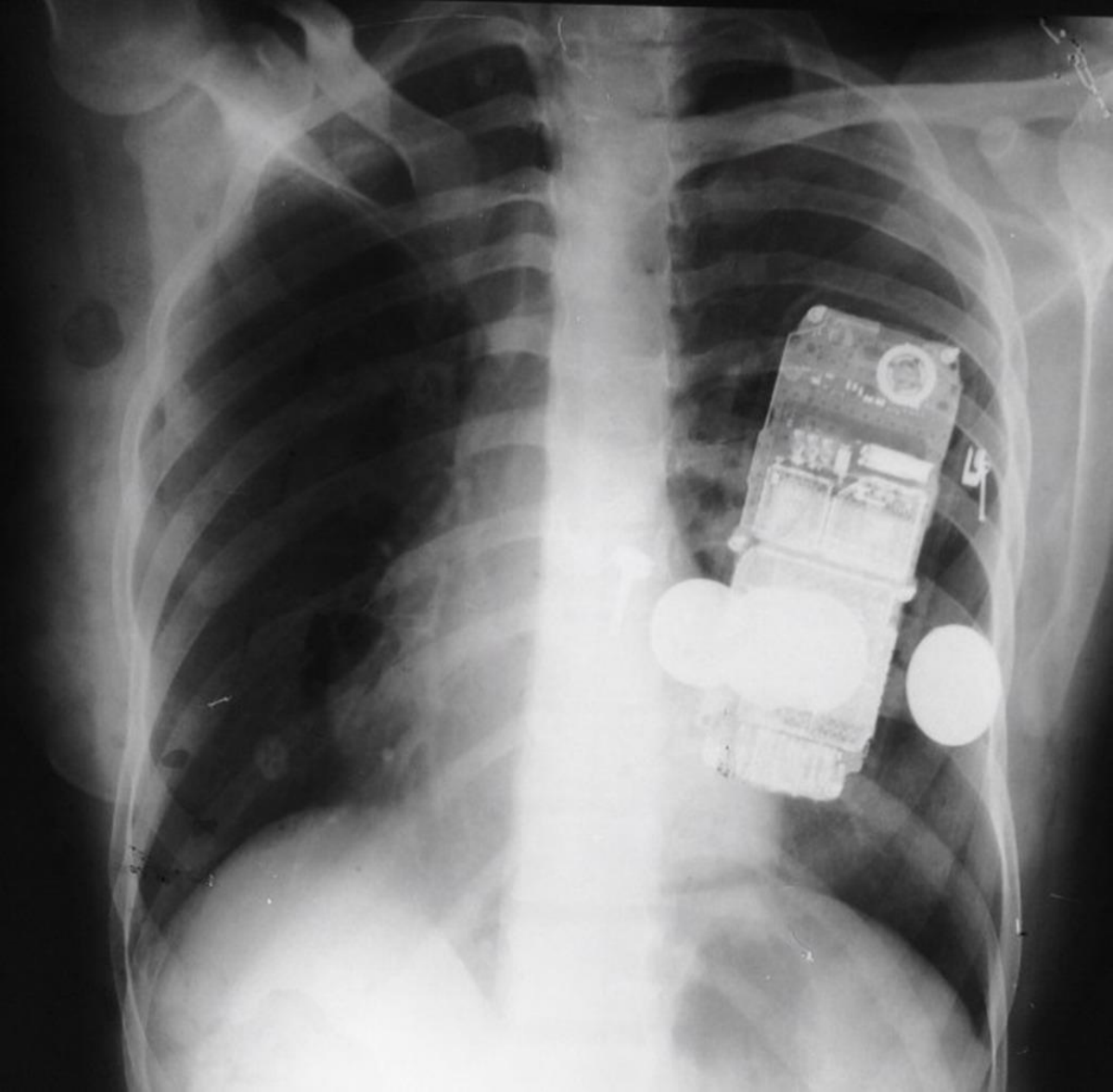
Temporary
pacing wire

O₂ tubing

Cardiac
monitoring
leads

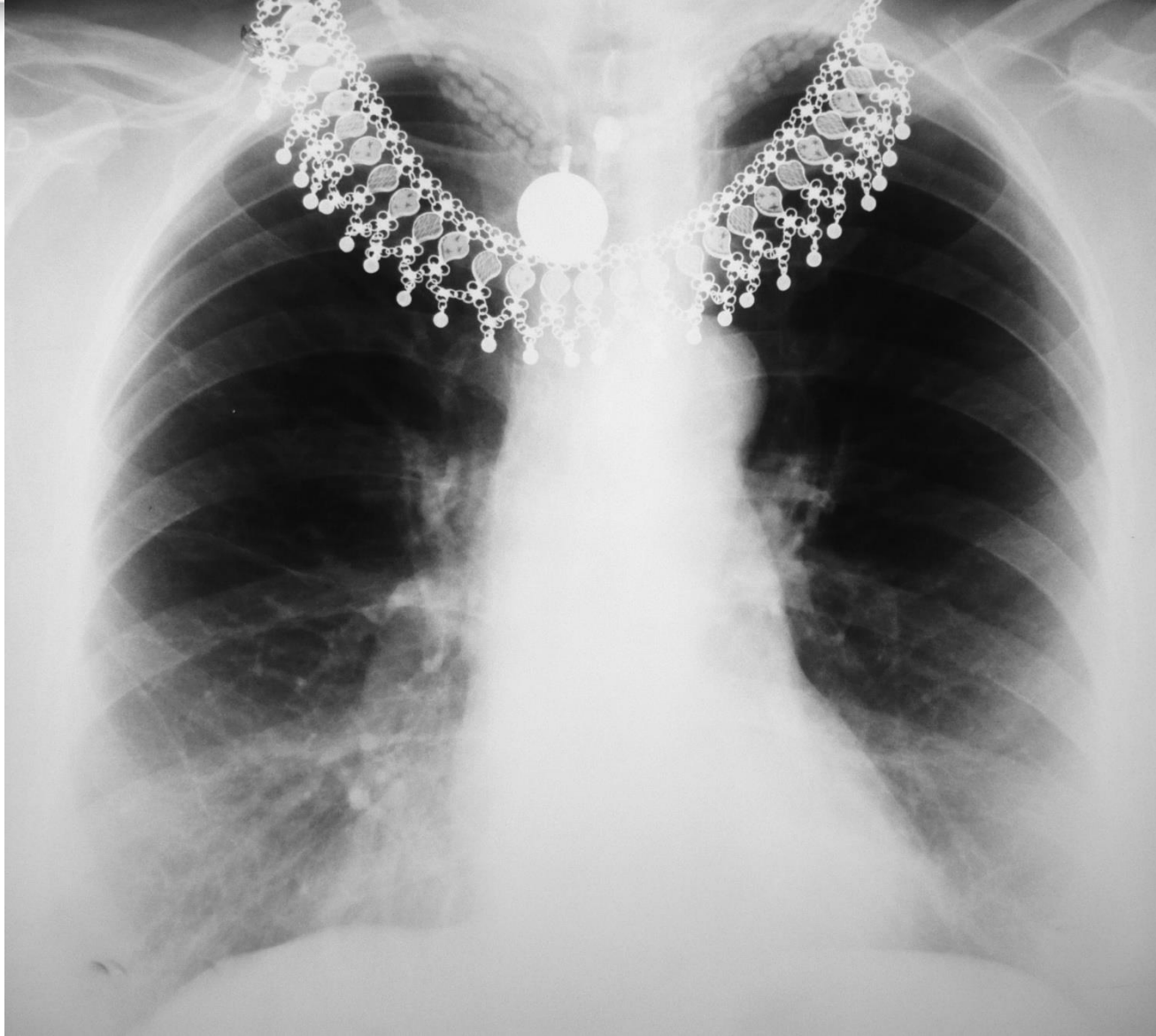Defibrillation
pads

Artifacts: Cell phone

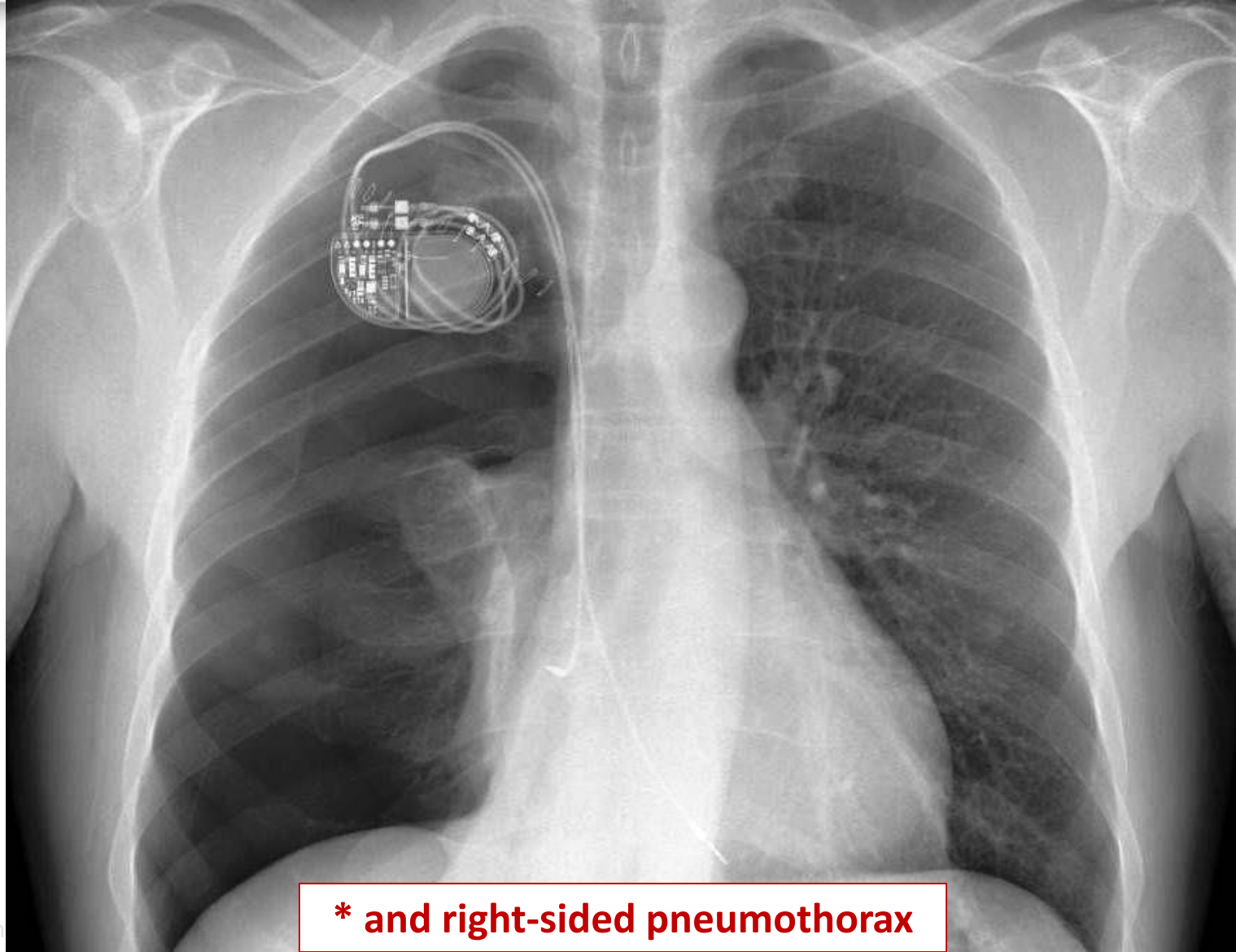


- The following “opacities” are noted:
 - **Cell phone**
 - **Coins**
 - **Pin**
 - **Button**

Artifacts: Jewellery



Artifacts: Pacemaker*



*** and right-sided pneumothorax**

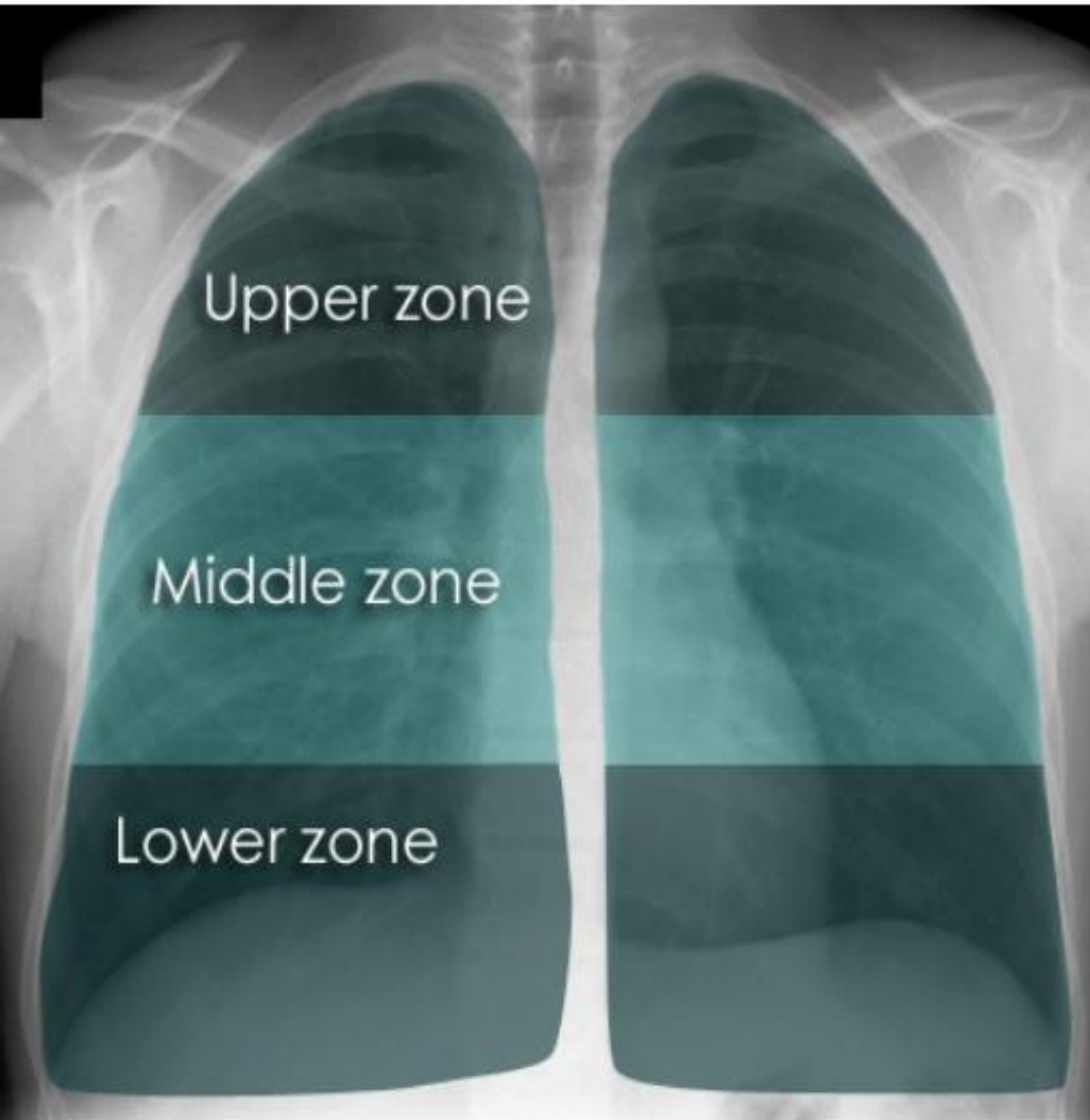
§3. CXR anatomy



- **Lung zones**
- **General topography**
- **Topography of lobes**
- **Hidden areas**

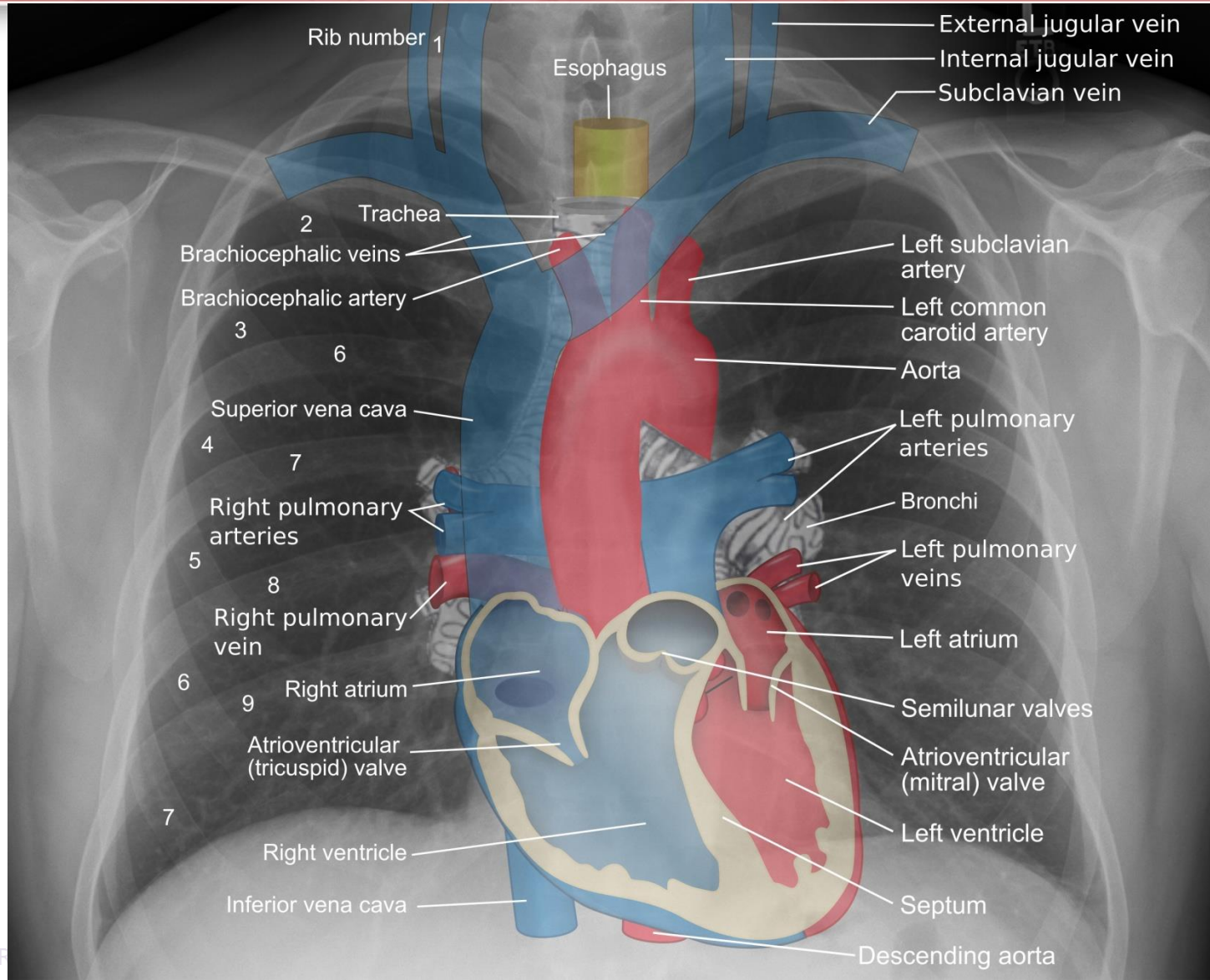


Lung zones

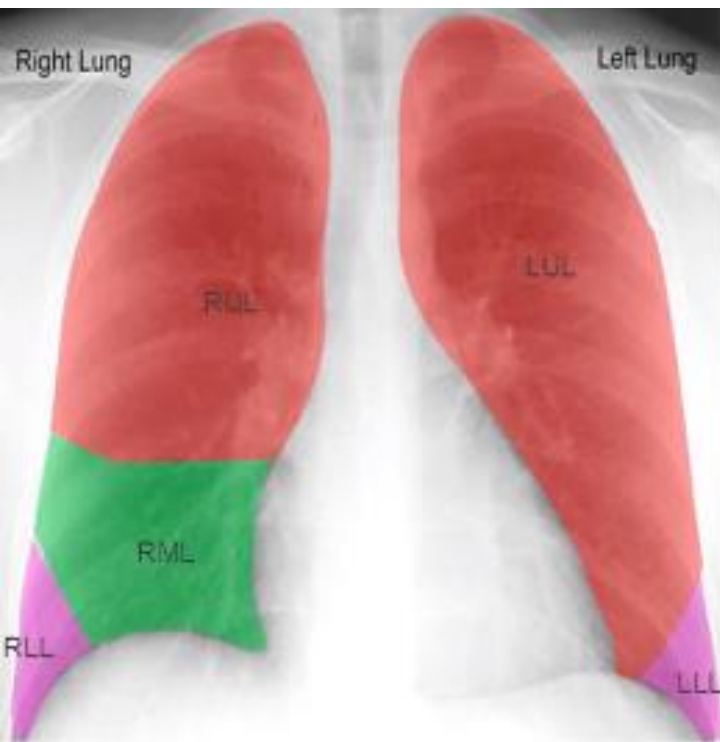


- The lungs are divided into **three zones** - **upper**, **middle** and **lower**.
- Each of these zones occupies approximately **1/3** of the height of the lungs.
- Sometimes **apical zone** is segregated in upper zone.
- The lung zones are not equal to the lung lobes.**

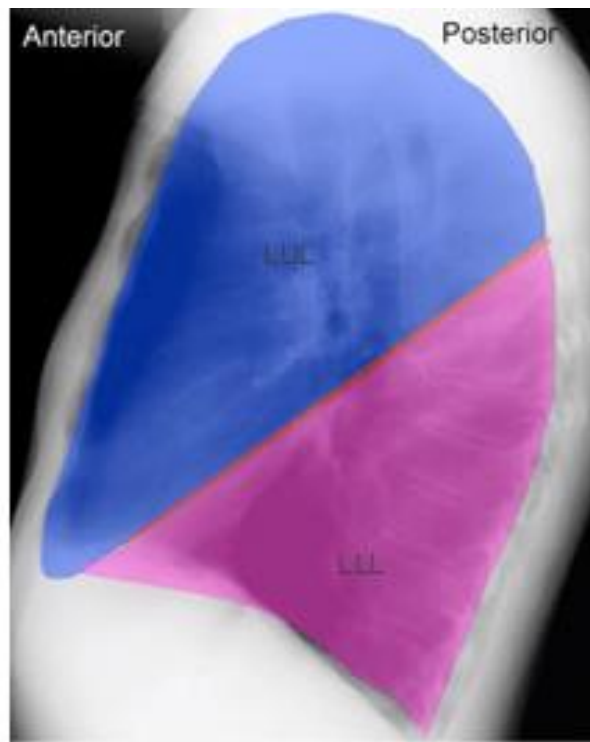
General topography



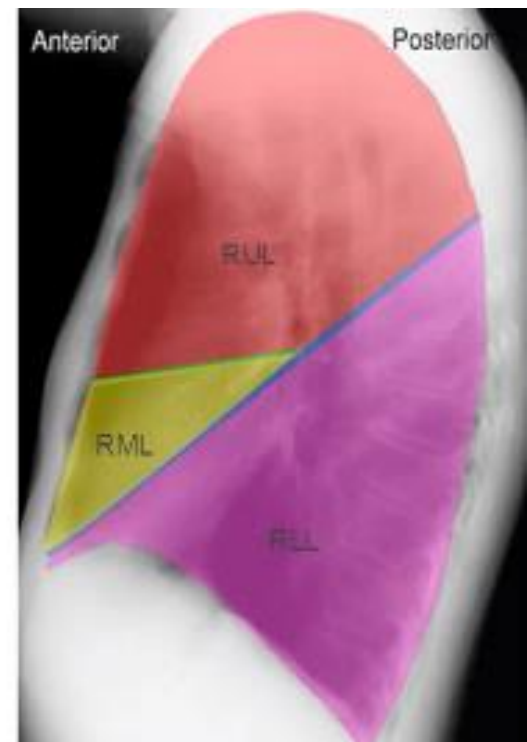
Topography of lobes



PA view

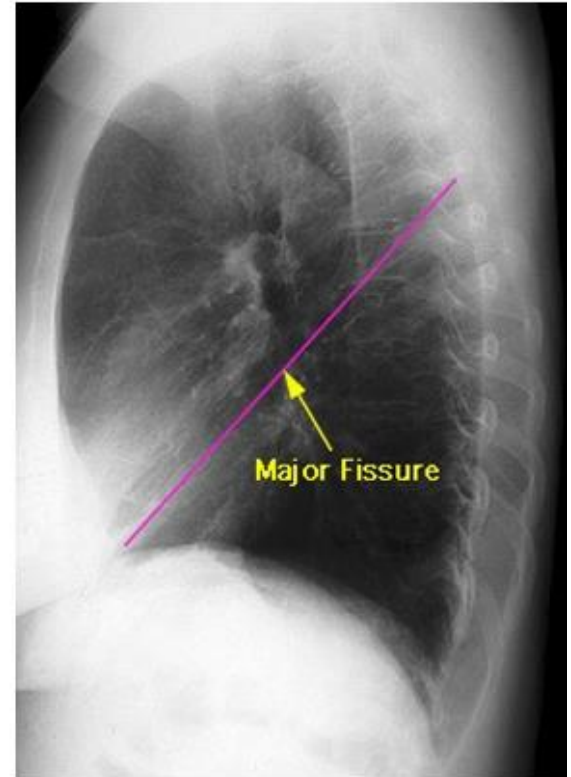
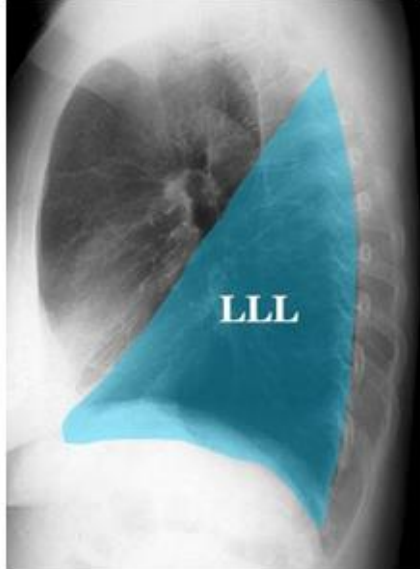
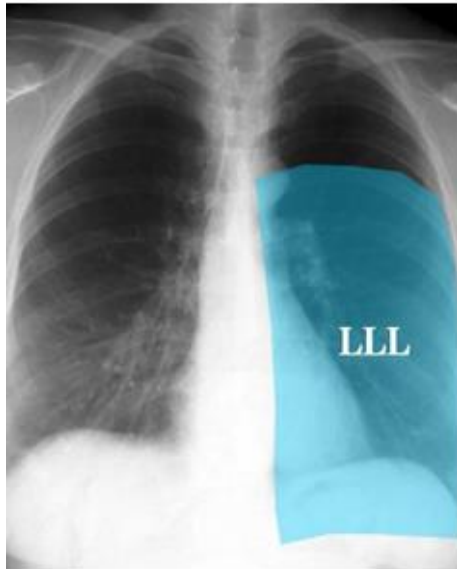
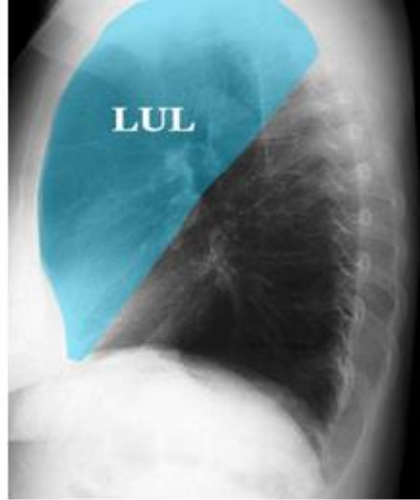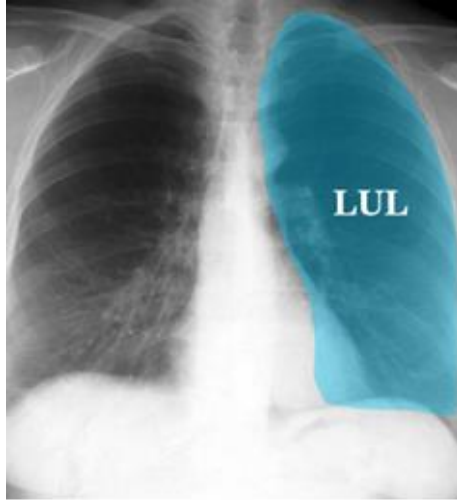


Left lateral view

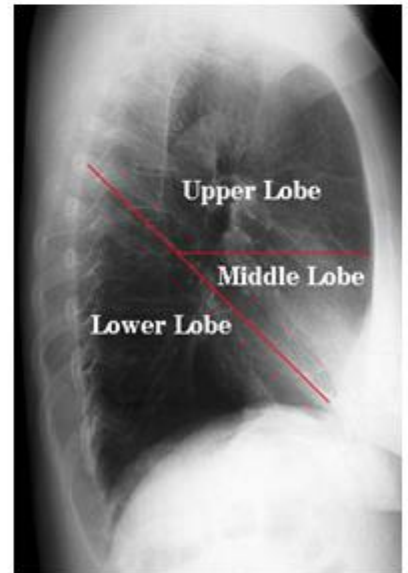
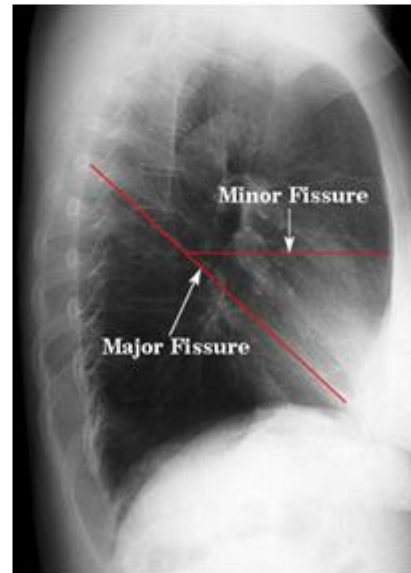
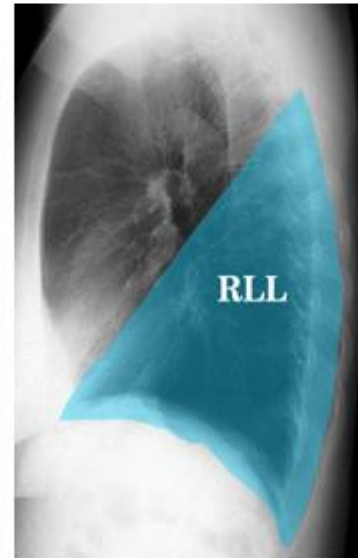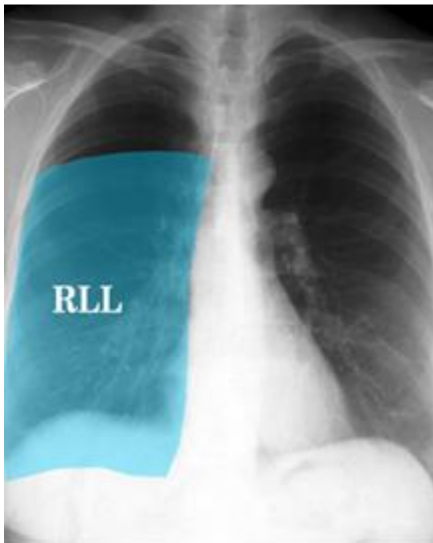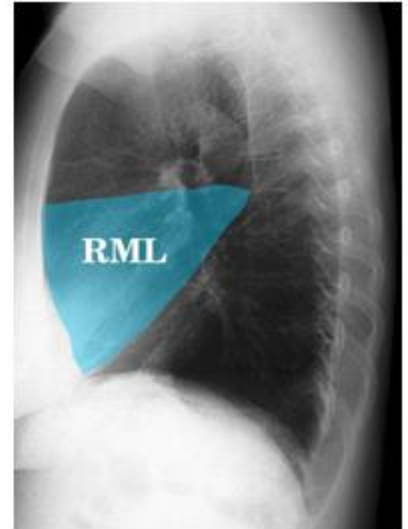
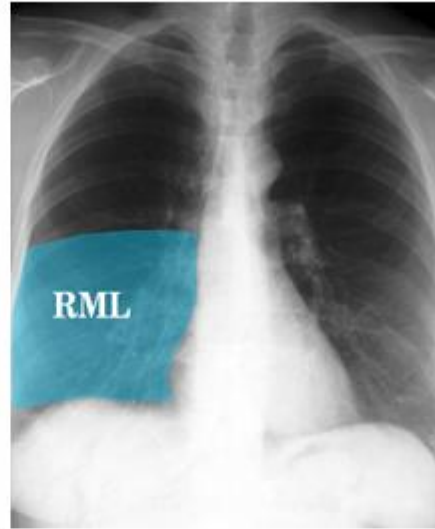
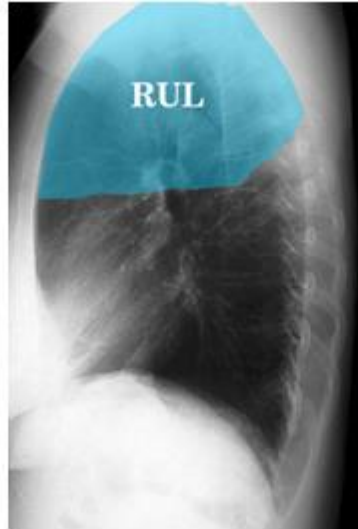
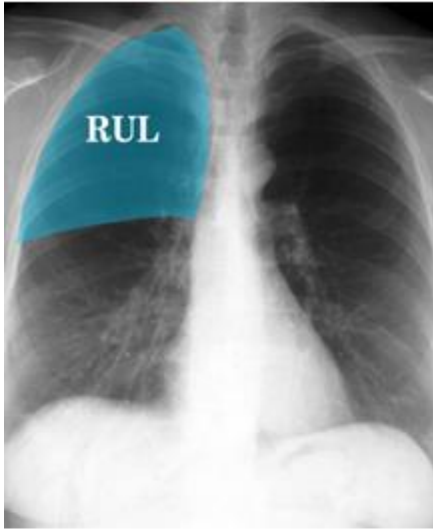


Right lateral view

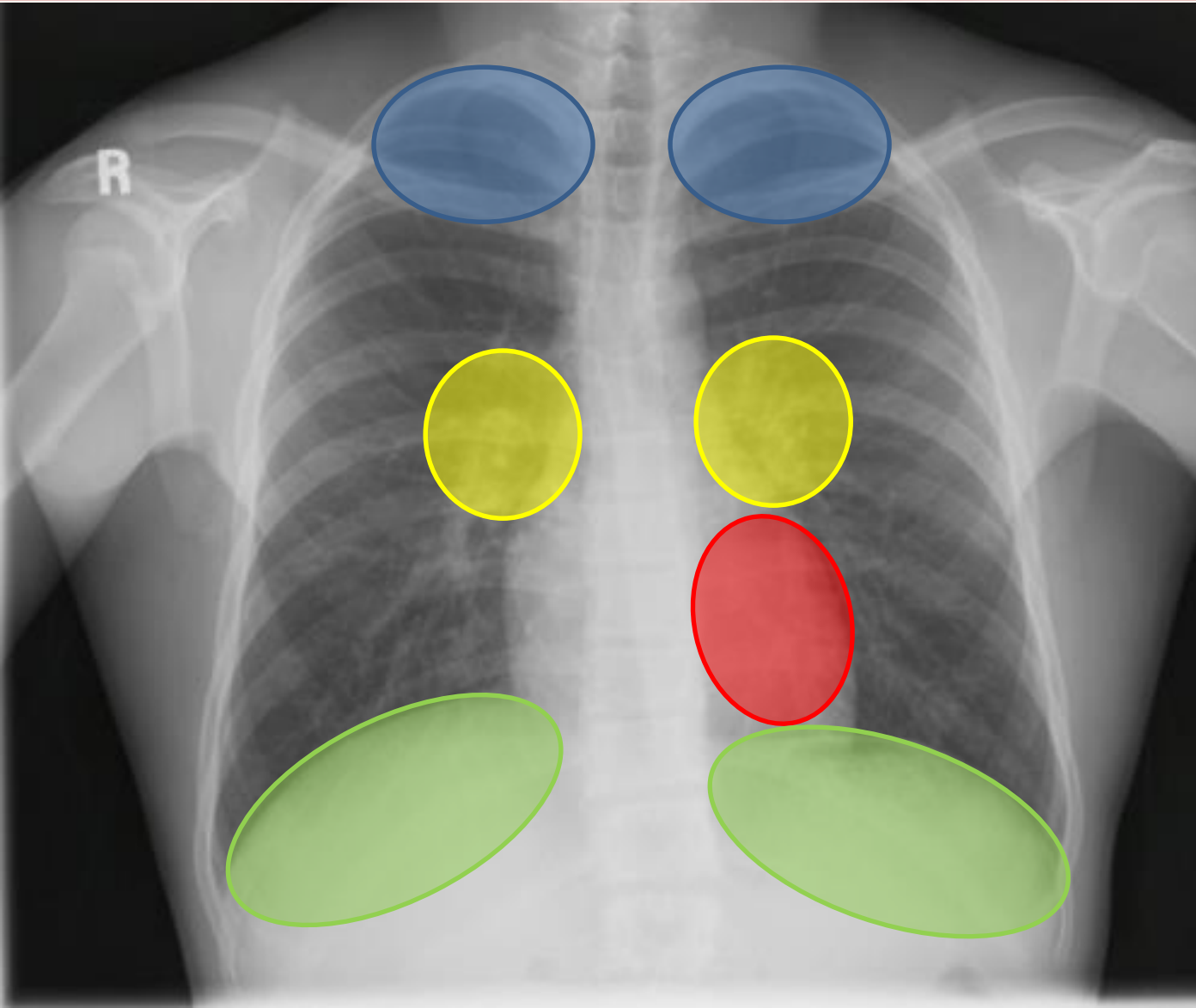
Left lung lobes



Right lung lobes



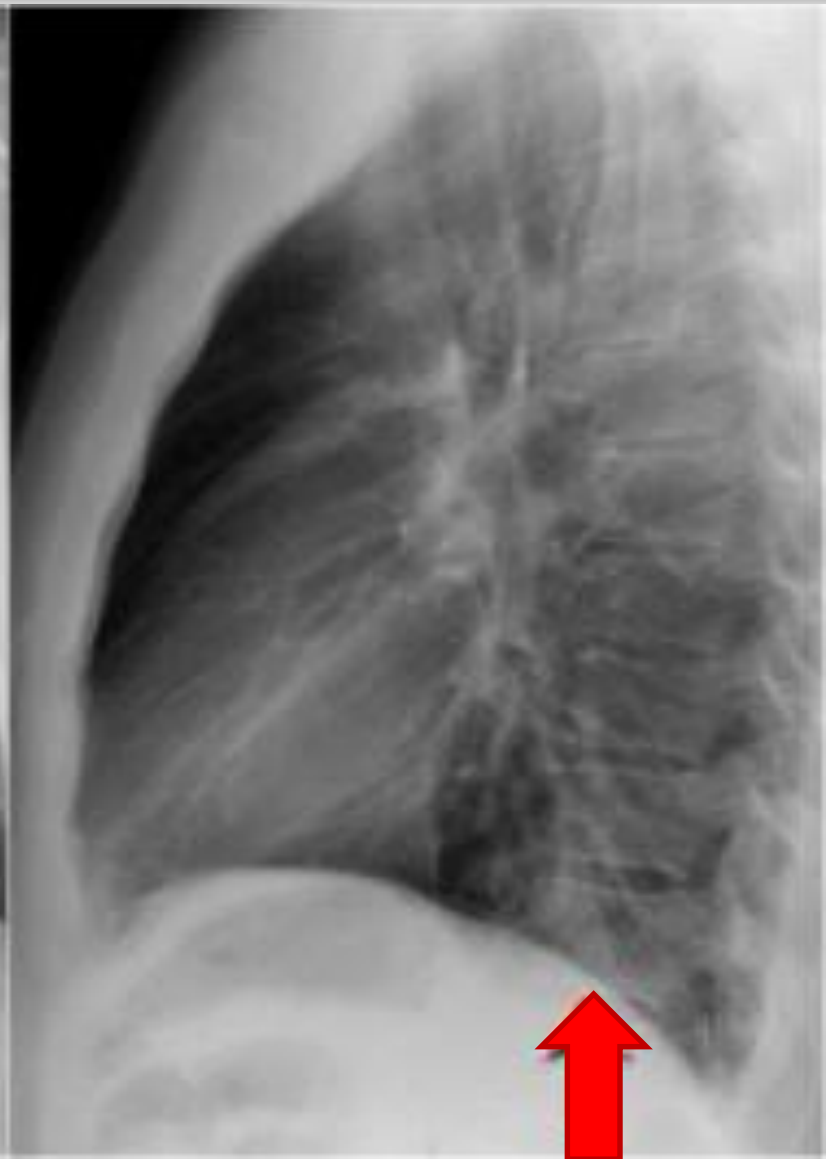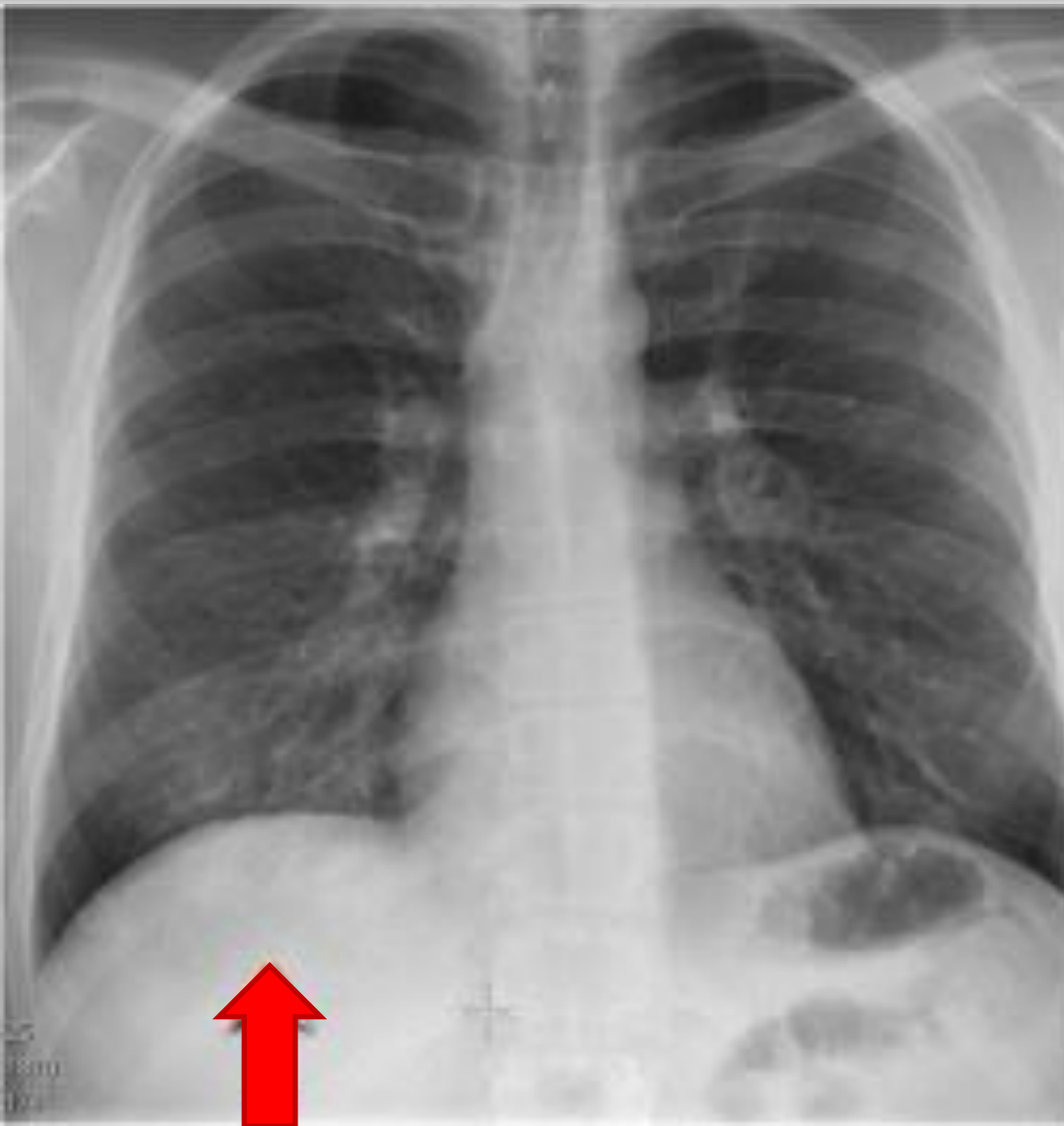
Hidden areas



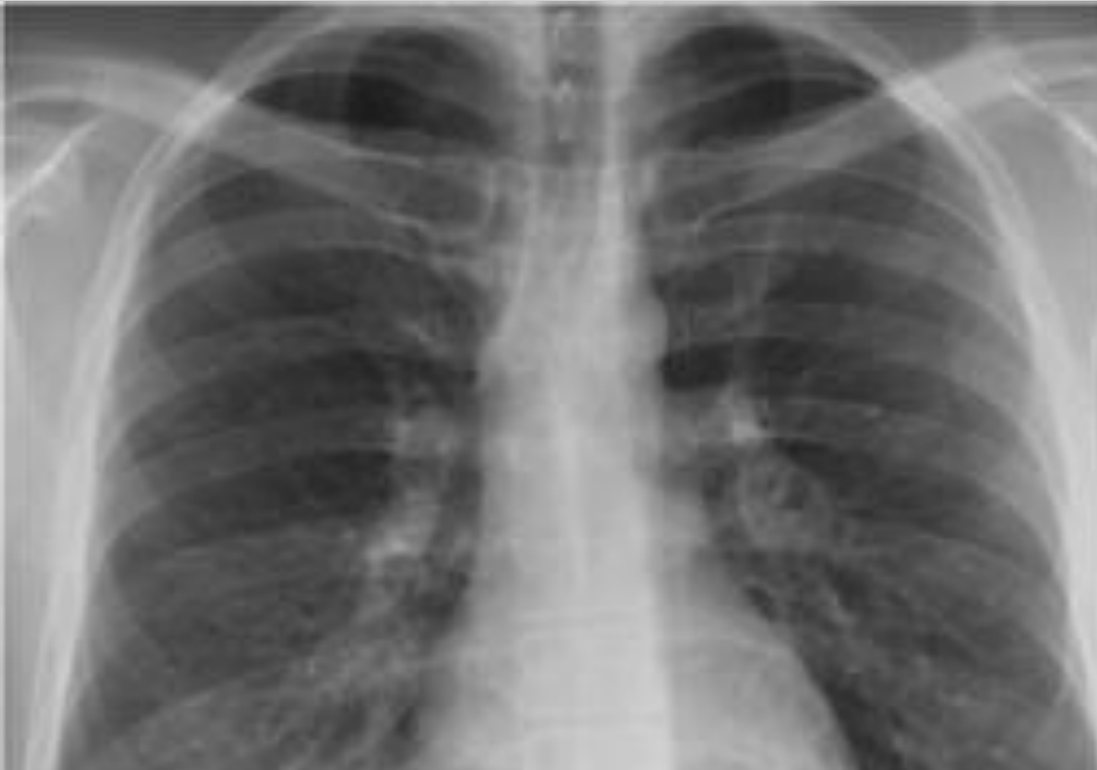These areas need special attention, because pathology in these areas can easily be overlooked:

-  **Apical zones**
-  **Hilar zones**
-  **Retrocardial zone**
-  **Zone below the dome of diaphragm**

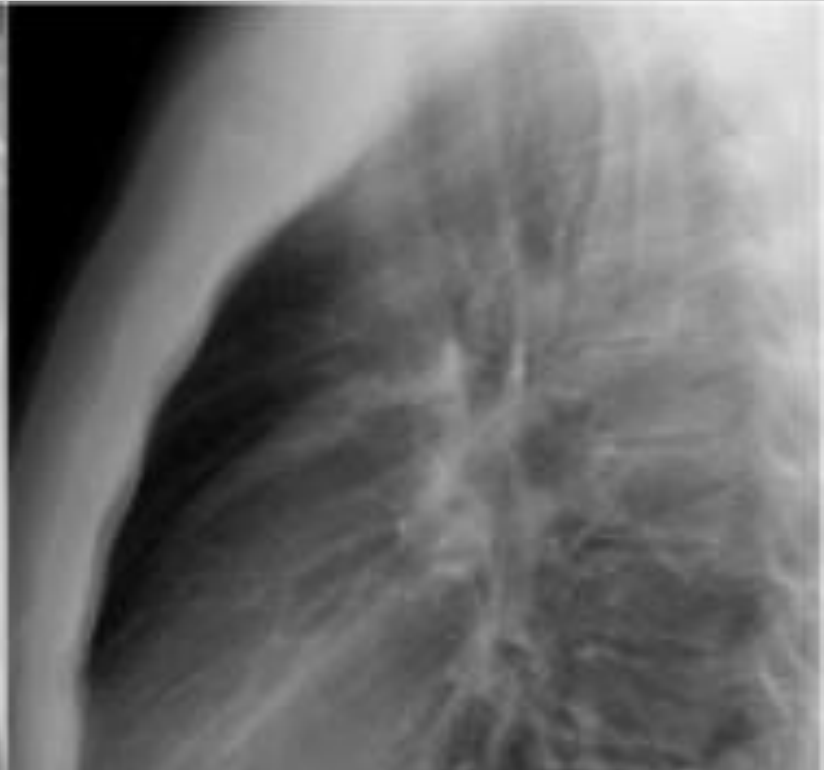Hidden areas



Hidden areas



Pneumonia is hidden in the right lower lobe mainly below the level of the dome of the diaphragm (red arrow).



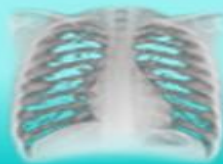
References*



Radiopaedia

<https://radiopaedia.org/>

RADIOLOGY
masterclass



<http://www.radiologymasterclass.co.uk/tutorials/tutorials/>



RADIOGRAPHY
world's largest radiography encyclopedia

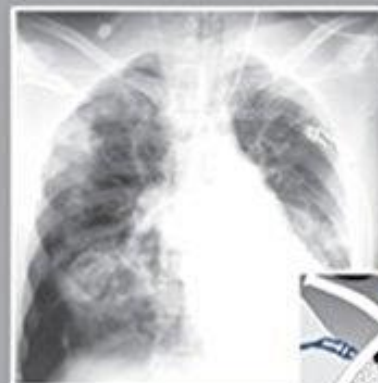<http://www.wikiradiography.net/>

Radiology Assistant

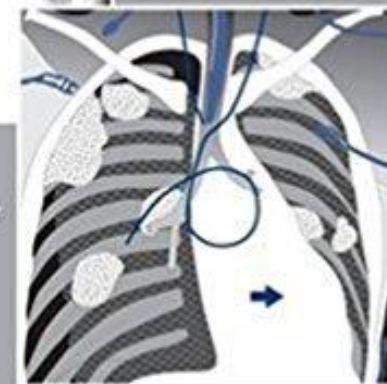
<http://www.radiologyassistant.nl/>

The Chest X-Ray

A Systematic Teaching Atlas



Matthias Hofer (Editor)
N. Abanador
L. Kamper
H. Rattunde
C. Zentai



- Radiographic Anatomy
- The ICU Chest X-Ray
- Thoracic Trauma
- Systematic Image Analysis
- Findings-oriented DD of Pathological Changes
- Identification of Foreign Bodies

 Thieme



Thank you!



to be continued