



**DISEASES OF
GONADS**

PLAN OF THE NOTES

1. NORMAL SEXUAL DIFFERENTIATION OF THE GONADS

2. ANATOMY AND PHYSIOLOGY OF THE GONADS

- male sex hormones, functions

- female sex hormones, functions

3. SEXUAL DEVELOPMENT IN BOYS AND GIRLS

4. CONGENITAL VIOLATION OF SEXUAL DIFFERENTIATION

4.1 MALE HYPOGONADISM

4.2 Klinefelter's syndrome

4.3 Shereshevsky -Turner syndrome

4.4 syndrome of hermaphroditism

4.5 cryptorchidism

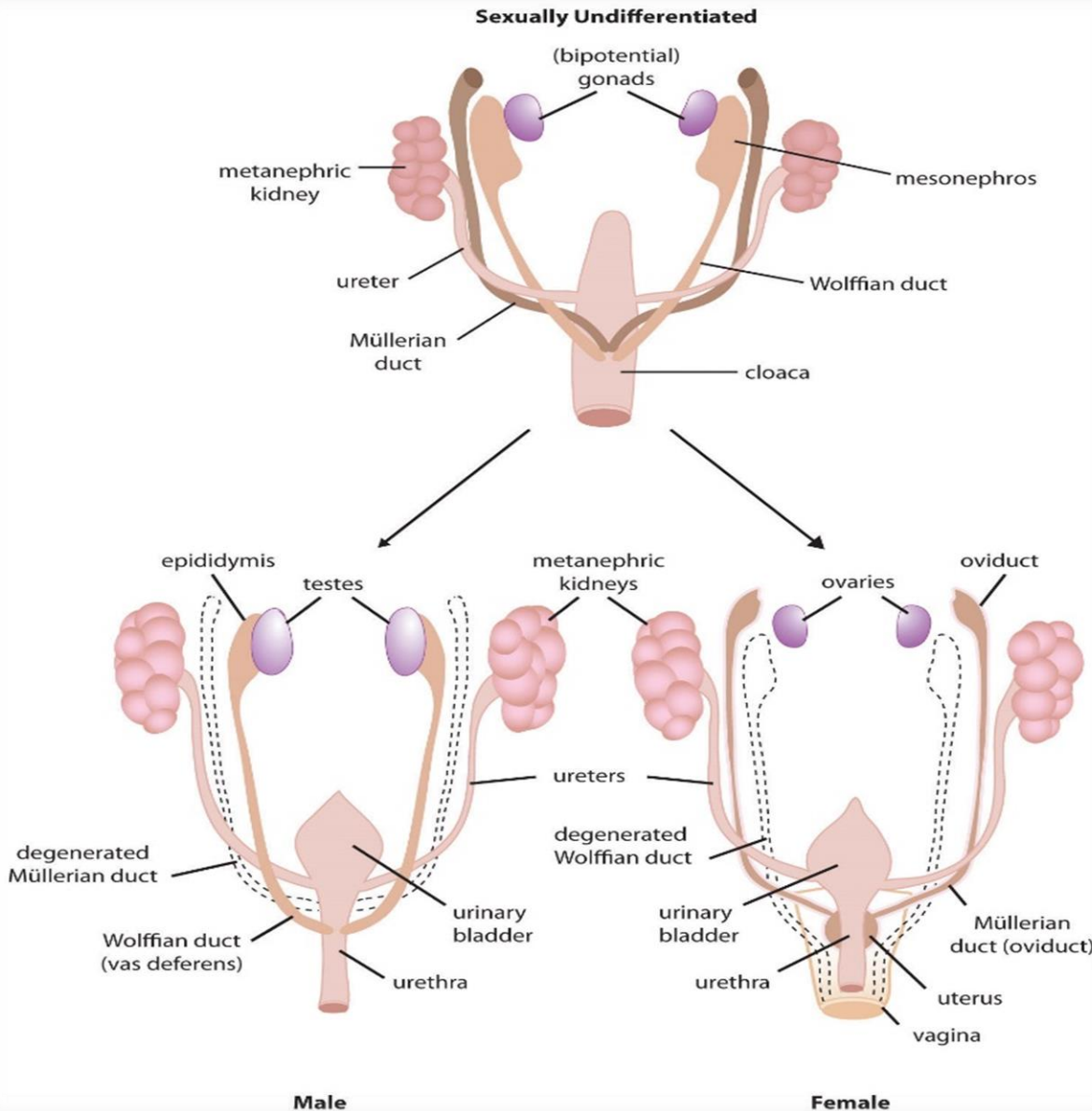
4.6 syndrome of mono- and anorchism

5. MENOPAUSE

1) NORMAL SEXUAL DIFFERENTIATION OF THE GONADS

**DIFFERENTIATION OF THE GONADS
STARTS FROM...?**

1) NORMAL SEXUAL DIFFERENTIATION OF THE GONADS 1.1



- Genetic sex is determined
- Testes develop in XY fetus
- Ovaries develop in XX fetus
- XY fetus produces MIS and androgens and XX fetus does not
- XY fetus develops Wolffian ducts -XX fetus develops Mullerian ducts
- XY fetus masculinizes the female genitalia to make it male and the XX fetus retains female genitalia

2) ANATOMY AND PHYSIOLOGY OF THE GONADS

DO YOU KNOW ANATOMICAL AND
HISTOLOGICAL STRUCTURE OF
THE FEMALE GONADS?

2) ANATOMY AND PHYSIOLOGY OF THE GONADS (female) 1.1

The **ovaries** are paired, oval organs attached to the posterior surface of the broad ligament of the uterus by the mesovarium (a fold of peritoneum, continuous with the outer surface of the ovaries). Neurovascular structures enter the hilum of the ovary via the mesovarium

The main functions of the ovaries are: to produce **oocytes** (female gametes) in preparation for fertilization, to produce the sex steroid hormones **oestrogen** and **progesterone**, in response to pituitary gonadotrophins (LH and FSH)

The ovary has 3 components:

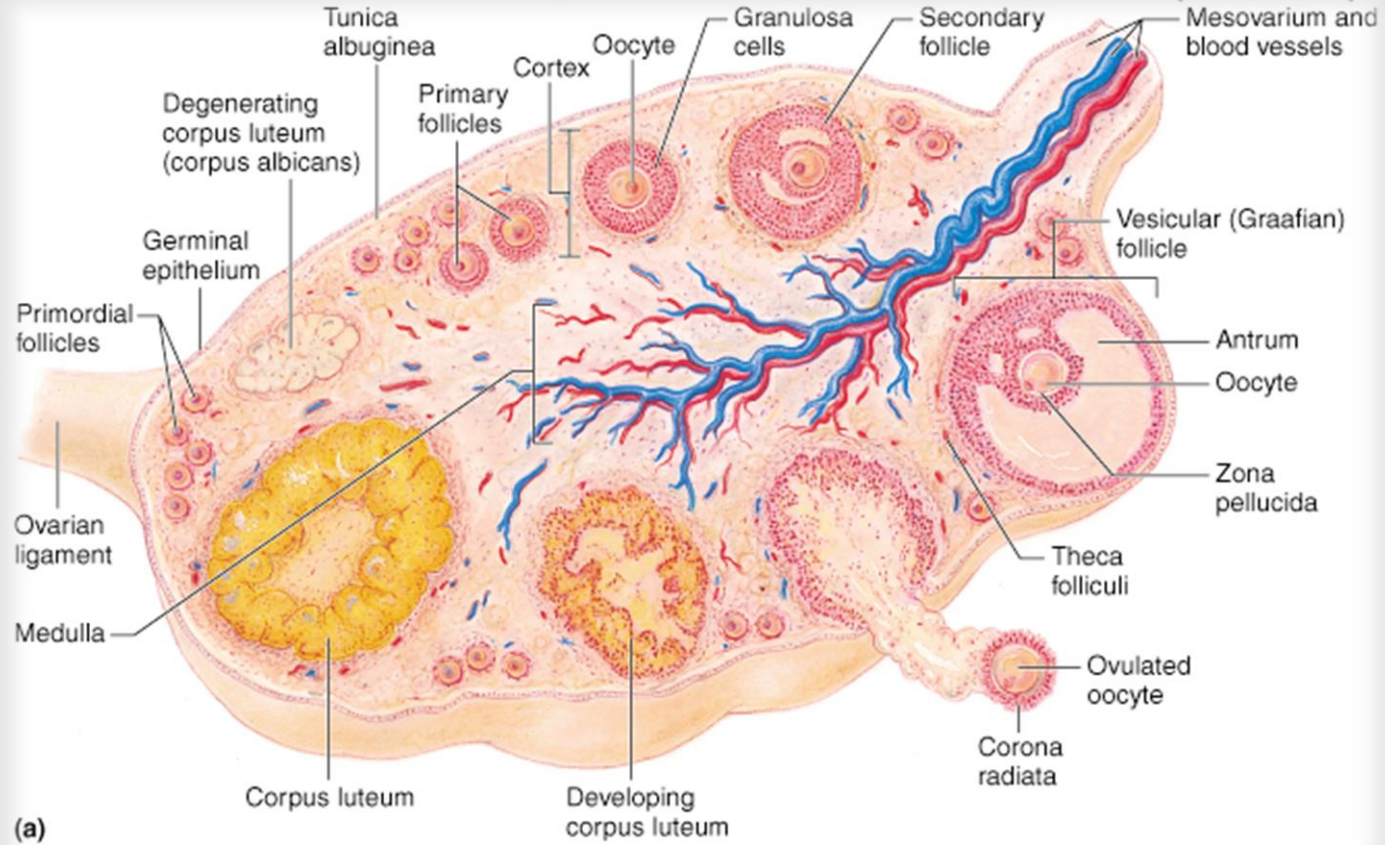
- **Surface:** The surface layer of the ovary is formed by simple cuboidal epithelium, known as germinal epithelium
- **Cortex:** The cortex (outer part) of the ovary is largely comprised of a connective tissue stroma. It supports thousands of follicles. Each primordial follicle contains an oocyte surrounded by a single layer of follicular cells
- **Medulla:** The medulla (inner part) is composed of supporting stroma and contains a rich neurovascular network which enters the hilum of ovary from the mesovarium

2) ANATOMY AND PHYSIOLOGY OF THE GONADS

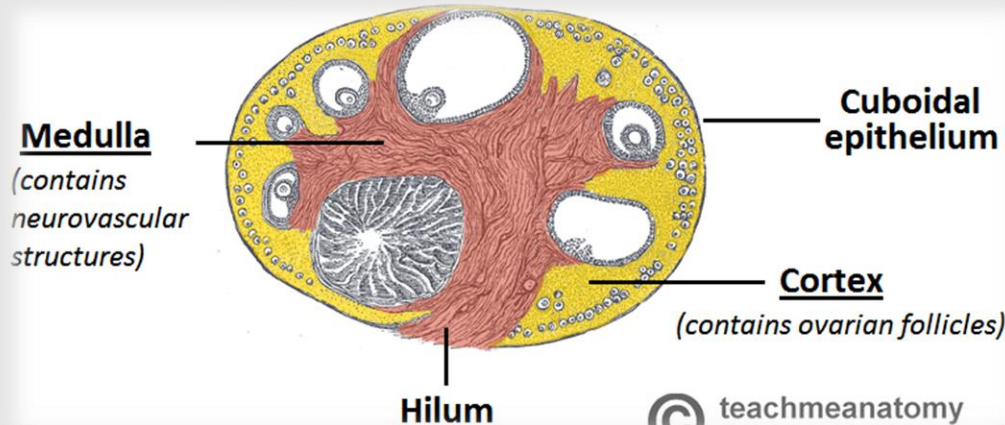
WHAT FEMALE HORMONES DO YOU
KNOW ?

WHAT ARE THEIR FUNCTIONS?

2) ANATOMY AND PHYSIOLOGY OF THE GONADS (female) 1.2



Copyright © 2001 Benjamin Cummings, an imprint of Addison Wesley Longman, Inc.



2) ANATOMY AND PHYSIOLOGY OF THE GONADS 2.2

(female sex hormones, functions)

Estrogens - Group of female sex hormones important for reproduction and the development of female sex characteristics. Estrogens are responsible for growth and maturation of the uterus and vagina; breast development; widening of the pelvis; greater fat distribution in the hips, thighs, and breast; uterus changes during the menstrual cycle; and increased growth of body hair

Progesterone - Hormone that functions to prepare the uterus for conception; regulates uterus changes during the menstrual cycle; increases sexual desire; aids in ovulation; and stimulates gland development for milk production during pregnancy

Androstenedione - Androgen hormone that serves as a precursor to testosterone and estrogens

Activin - Hormone that stimulates the production and release of follicle-stimulating hormone (FSH). It also assists in menstrual cycle regulation

Inhibin - Hormone that inhibits the production and release of FSH

2) ANATOMY AND PHYSIOLOGY OF THE GONADS

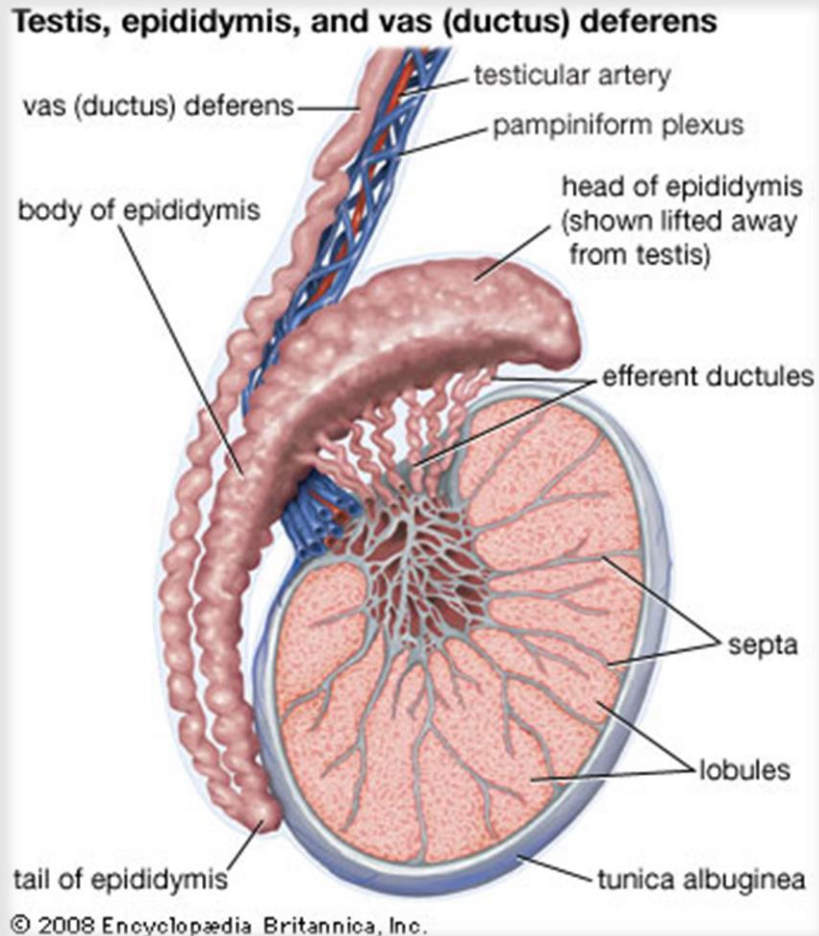
DO YOU KNOW ANATOMICAL
STRUCTURE OF THE MALE GONADS?

WHAT MALE HORMONES DO YOU
KNOW ?

WHAT ARE THEIR FUNCTIONS?

2) ANATOMY AND PHYSIOLOGY OF THE GONADS 1.1

(male sex hormones, functions)



Testosterone - Sex hormone important for the development of male sex organs and sex characteristics. Testosterone is responsible for increased muscle and bone mass; increased growth of body hair; development of broad shoulders; deepening of the voice; and growth of the penis

Androstenedione - Hormone that serves as a precursor to testosterone and estrogens

Inhibin - Hormone that inhibits the release of FSH and is thought to be involved in sperm cell development and regulation

3) SEXUAL DEVELOPMENT IN BOYS AND GIRLS

CLASSIFICATION OF SEXUAL DEVELOPMENT IN BOYS AND GIRLS?

3) SEXUAL DEVELOPMENT OF GIRLS 1.6

Development of mammary gland

Phase

Ma 0

Mammary glands does not project over the surface thorax

Ma 1

Glands something project, alveolla together with nipple form uniform cone

Ma 2

Glands much project, together with nipple and alveola have cone shape

Ma 3

Glands bodies adopt roundish form, nipples rise over the alveola

Grows of pubic hair

Phase

P 0

Absence of hair

P 1

Sporadic hair

P 2

The hair on the antral part of pubic is few and long

P 3

Hair on surface of pubic is long ,curly, dense (thick)

3) SEXUAL DEVELOPMENT OF GIRLS 2.6

Grows of pubic hair

Phase

Absence of hair

P 0

Sporadic hair

P 1

Sparse growth of long, straight, downy and slightly pigmented hair at base of penis

P 2

Hair darker, coarser and curly and spread sparsely over entire pubis

P 3

Pubic hair more abundant with curling but restricted to pubic area

P 4

Hair adult in quantity and type with spread to inner surface of thighs

P 5

Development of hair in axillary fossa

Phase

Absence of hair

Ax 0

Sporadic hair

Ax 1

Hair is scarce on the central part

Ax 2

Dense straight hair on the entire fossa

Ax 3

Dense curly hair on the entire fossa

Ax 4

3) SEXUAL DEVELOPMENT OF GIRLS 3.6

Formation of menstrual function

Phase

Absence of menstrual cycle (menses)

Me 0

1-2 menstrual cycle before examination

Me 1

Irregular menstrual cycle (menses)

Me 2

Regular menstrual cycle (menses)

Me 3

3) SEXUAL DEVELOPMENT OF BOYS 4.6

Development of hair in axillary fossa

Phase

Absence of hair

Ax 0

Sporadic hair

Ax 1

Hair is scarce on the central part

Ax 2

Dense straight hair on the entire fossa

Ax 3

Dense curly hair on the entire fossa

Ax 4

Grows of pubic hair

Phase

Absence of hair

P 0

Sporadic hair

P 1

Sparse growth of long, straight, downy and slightly pigmented hair at base of penis

P 2

Hair darker, coarser and curly and spread sparsely over entire pubis

P 3

Pubic hair more abundant with curling but restricted to pubic area

P 4

Hair adult in quantity and type with spread to inner surface of thighs

P 5

3) SEXUAL DEVELOPMENT OF BOYS 5.6

Grows of thyroid cartilage

Phase

No signs of grows

L 0

Beginning of cartilage projection

L 1

Distinct projection of Adam's-apple

L 2

Change of voice timbre

Phase

Childish voice

V 0

Mutation (creaking)of voice

V 1

Male timbre of voice

V 2

3) SEXUAL DEVELOPMENT OF BOYS 6.6

Grows of facial hair

Phase

Absence of hair	F 0
Beginning of hair grows over the upper lip	F 1
Harsh hair over the upper lip and appearance of hair on the chin	F 2
Spreading of hair grows over the upper lip and chin with tendency to confluence, beginning on whiskers grows	F 3
Confluence of hair over the upper lip and chin, pronounced of whiskers grows	F 4
Confluence of all zones of hair grows	F 5

4) CONGENITAL VIOLATION OF SEXUAL DIFFERENTIATION

4.1 MALE HYPOGONADISM

WHAT IS MALE HYPOGONADISM?

4) CONGENITAL VIOLATION OF SEXUAL DIFFERENTIATION

4.1 MALE HYPOGONADISM 1.1

Definition

A decrease in either of the two major functions of the testes:

sperm production

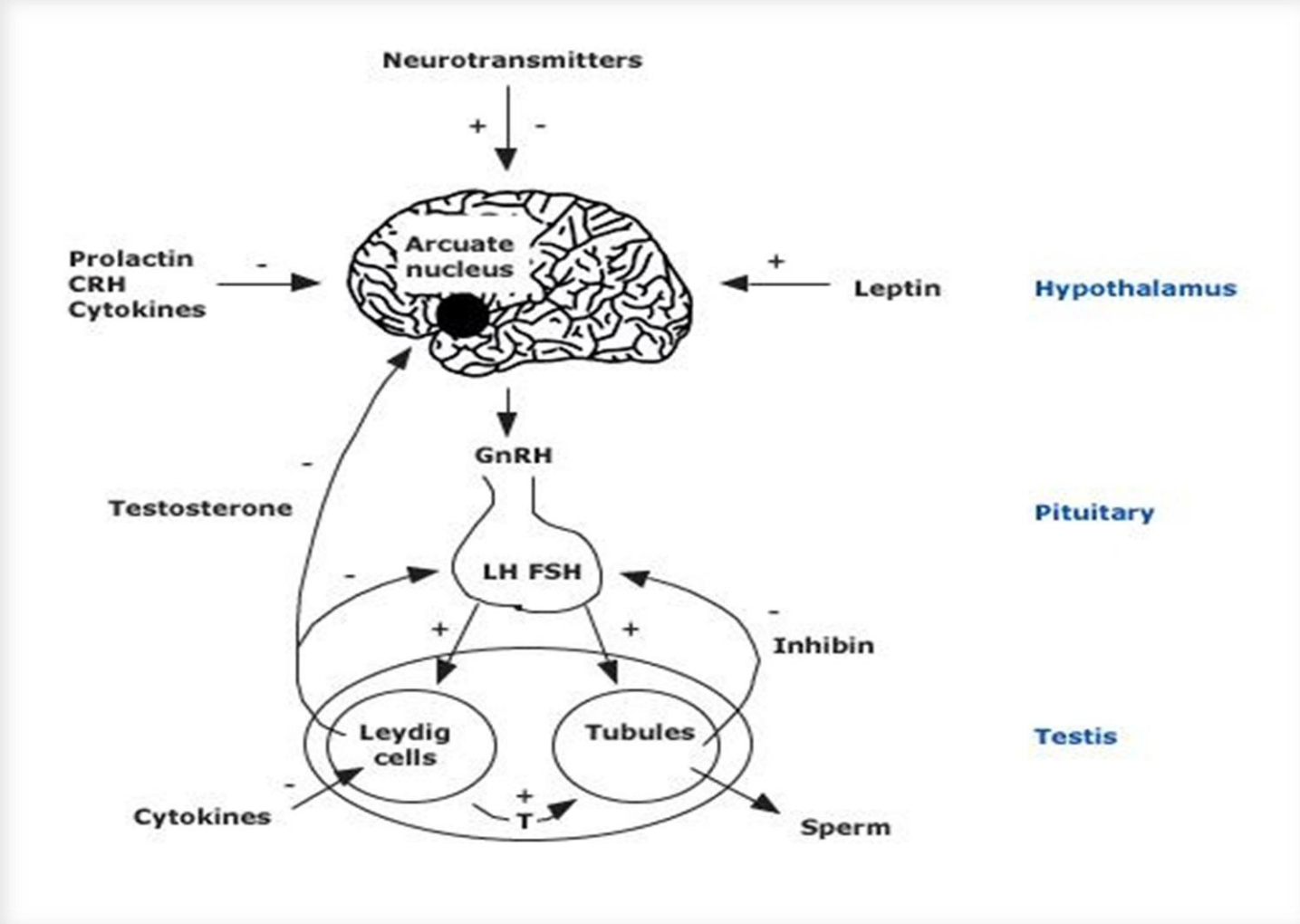
testosterone production

“TD [testosterone deficiency] is a clinical and biochemical syndrome frequently associated with age and comorbidities, and characterized by a deficiency in testosterone and relevant symptoms

4) CONGENITAL VIOLATION OF SEXUAL DIFFERENTIATION

4.1 MALE HYPOGONADISM ???

Hypothalamic-Pituitary-Testis Axis





4) CONGENITAL VIOLATION OF SEXUAL DIFFERENTIATION
4.1 MALE HYPOGONADISM

**CLASSIFICATION OF MALE
HYPOGONADISM?**

4) CONGENITAL VIOLATION OF SEXUAL DIFFERENTIATION

4.1 MALE HYPOGONADISM 1.2

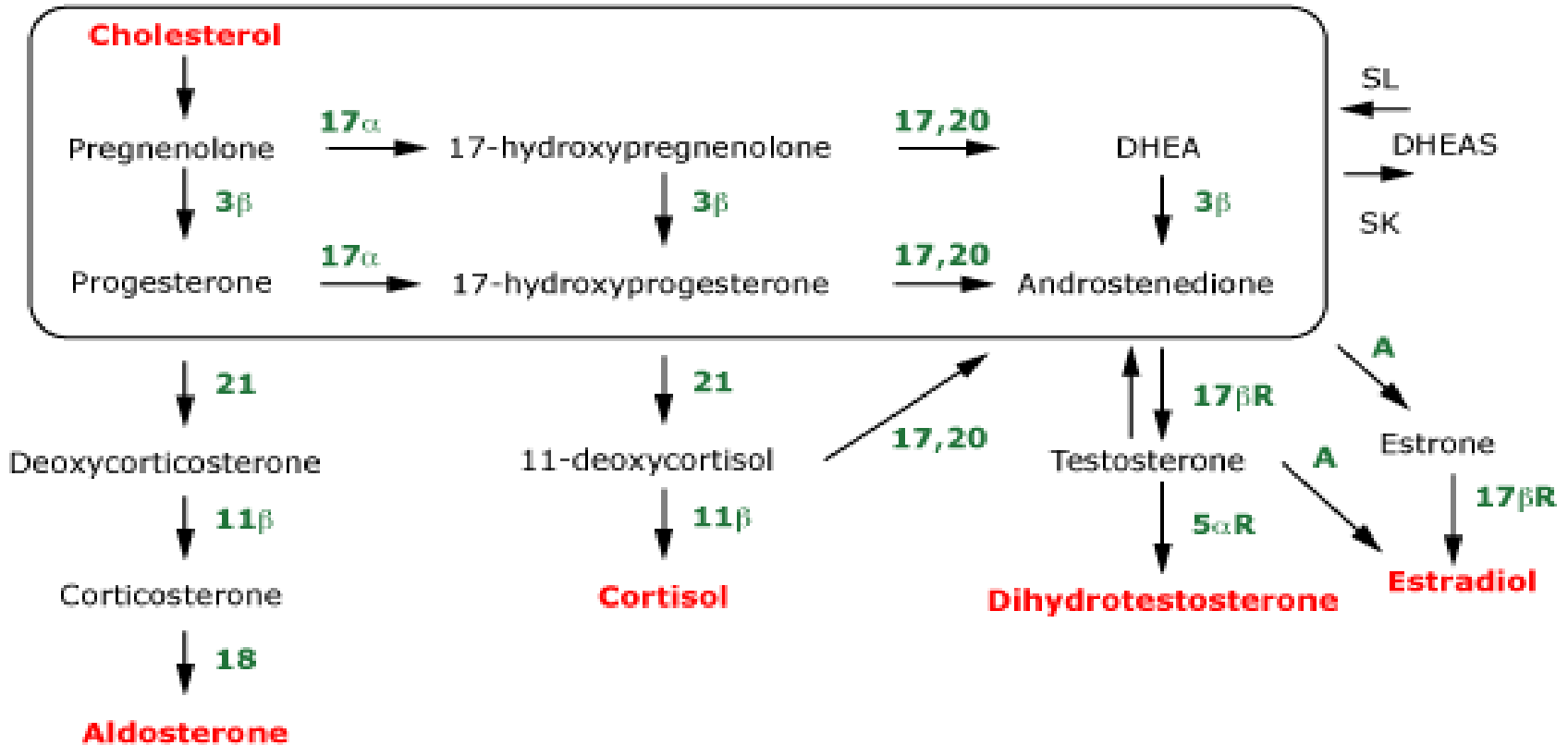
CLASSIFICATION OF MALE HYPOGONADISM

Secondary hypogonadism		Hypothalamus Pituitary
Primary hypogonadism		Testes
Target organ resistance	<ul style="list-style-type: none">● Androgen receptor defect● 5α-reductase deficiency● Aromatase deficiency	Target tissues for testosterone, estradiol and DHT

4) CONGENITAL VIOLATION OF SEXUAL DIFFERENTIATION

4.1 MALE HYPOGONADISM 2.2

TESTOSTERONE



4) CONGENITAL VIOLATION OF SEXUAL DIFFERENTIATION

4.1 MALE HYPOGONADISM

WHAT ARE THE CAUSES OF PRIMARY
HYPOGONADISM?

4) CONGENITAL VIOLATION OF SEXUAL DIFFERENTIATION

4.1 MALE HYPOGONADISM 1.1

PRIMARY HYPOGONADISM CAUSES

Prepubertal onset

- **Klinefelter syndrome**
- Other chromosomal abnormalities
- Mutation in the FSH and LH receptor genes
- Cryptorchidism
- Disorders of androgen biosynthesis
- Myotonic dystrophy
- Congenital anorchia
- Varicocele

Postpubertal onset

- Infections — Mumps orchitis
- Radiation
- Drugs
- Trauma
- Bilateral orchiectomy
- Autoimmune damage
- Chronic systemic diseases
 - Cirrhosis
 - Chronic renal failure
 - HIV

4) CONGENITAL VIOLATION OF SEXUAL DIFFERENTIATION

4.1 MALE HYPOGONADISM

WHAT ARE THE CAUSES OF SECONDARY
HYPOGONADISM?

4) CONGENITAL VIOLATION OF SEXUAL DIFFERENTIATION

4.1 MALE HYPOGONADISM 1.1

SECONDARY HYPOGONADISM.CAUSES

Prepubertal onset

- Isolated idiopathic hypogonadotropic hypogonadism
- Kallmann's syndrome
- Idiopathic hypogonadotropic hypogonadism associated with mental retardation
- Abnormal β -subunit of LH
- Abnormal β -subunit of FSH
- Idiopathic hypogonadotropic hypogonadism associated with other hypothalamic pituitary hormonal deficits

Postpubertal onset

- Sella or suprasellar tumor
- Infiltrative disease
 - Sarcoidosis, eosinophilic granuloma → hypothalamic hypogonad
 - Hemochromatosis → pituitary hypogonad
- Infection: meningitis
- Trauma
- Critical illness: surgery, MI, head trauma
- Chronic systemic illness : cirrhosis, CKD, HIV
- Drugs

4) CONGENITAL VIOLATION OF SEXUAL DIFFERENTIATION

4.1 MALE HYPOGONADISM

**DESCRIBE THE CLINICAL PICTURE
OF HYPOGONADISM?**

4) CONGENITAL VIOLATION OF SEXUAL DIFFERENTIATION

4.1 MALE HYPOGONADISM 1.4

SYMPTOMS AND SIGNS SUGGESTIVE OF MALE HYPOGONADISM

Androgen Deficiency Symptoms

Musculoskeletal :

Sexuality:

- Decreased vigour and physical energy
- Diminished muscle strength
- Decreased interest in sex
- Reduction in frequency of sexual activity
- Poor erectile function/arousal
- Loss of nocturnal erections
- Reduced quality of orgasm
- Reduced volume of ejaculate

4) CONGENITAL VIOLATION OF SEXUAL DIFFERENTIATION

4.1 MALE HYPOGONADISM 2.4

SYMPTOMS AND SIGNS SUGGESTIVE OF MALE HYPOGONADISM

Androgen Deficiency Symptoms

Mood disorder and cognitive function

- Irritability & lethargy
- Decreased sense of well-being
- Lack of motivation
- Low mental energy
- Difficulty with short-term memory
- Depression
- Low self-esteem
- Insomnia
- Nervousness

Vasomotor and nervous

- Hot flushes
- Sweating

4) CONGENITAL VIOLATION OF SEXUAL DIFFERENTIATION

4.1 MALE HYPOGONADISM 3.4

PHYSICAL SIGNS

- Diminished muscle mass
- Loss of body hair
- Abdominal obesity
- Gynæcomastia
- Testes frequently normal, occasionally small

4) CONGENITAL VIOLATION OF SEXUAL DIFFERENTIATION

4.1 MALE HYPOGONADISM 4.4

PHYSICAL SIGNS

Prepubertal onset: Eunuchoidism

- Lack of adult male hair distribution
- Sparse axillary, pubic hair
- Lack of temporal hair recession
- High-pitched voice
- Infantile genitalia
- Small penis, testes and scrotum
- ↑ fat deposition in pectoral, hip, thigh and lower abdomen
- Eunuchoidal proportion
- Arm span > Height > 5 cm
- Upper/ lower segment ratio < 1

Postpubertal onset

- Loss of libido
- Impotence
- Infertility

4) CONGENITAL VIOLATION OF SEXUAL DIFFERENTIATION

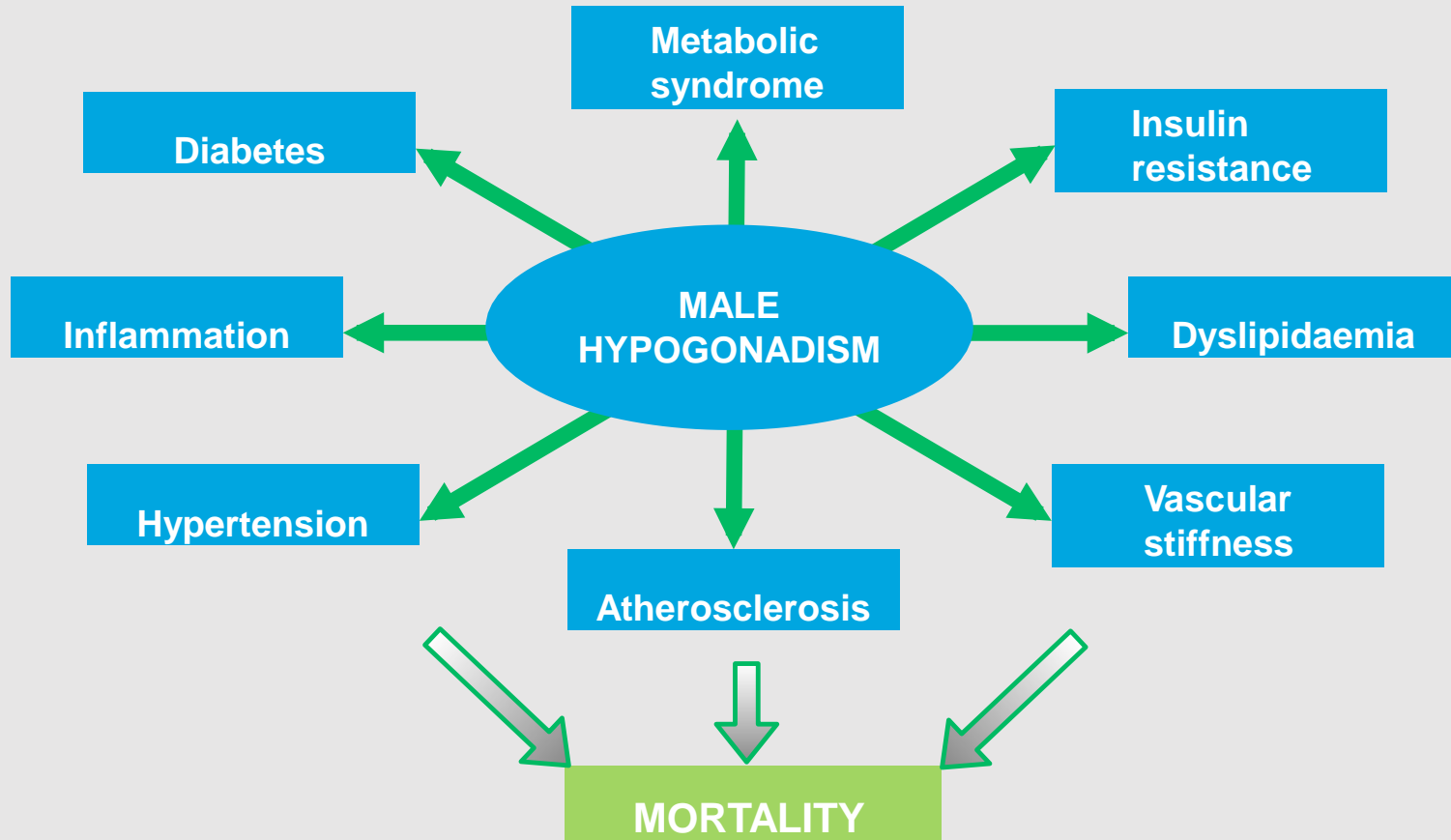
4.1 MALE HYPOGONADISM

WHAT COMPLICATIONS OF
HYPOGONADISM DO YOU KNOW?

4) CONGENITAL VIOLATION OF SEXUAL DIFFERENTIATION

4.1 MALE HYPOGONADISM 1.2

New spectrum of CV complications of low **testosterone levels**



4) CONGENITAL VIOLATION OF SEXUAL DIFFERENTIATION

4.1 MALE HYPOGONADISM 2.2

METABOLIC AND OTHER EFFECTS

1. Cardiovascular disease
2. Diabetes
3. Obesity and the metabolic syndrome
4. Osteoporosis

4) CONGENITAL VIOLATION OF SEXUAL DIFFERENTIATION

4.1 MALE HYPOGONADISM

DIAGNOSTICS OF MALE HYPOGONADISM?

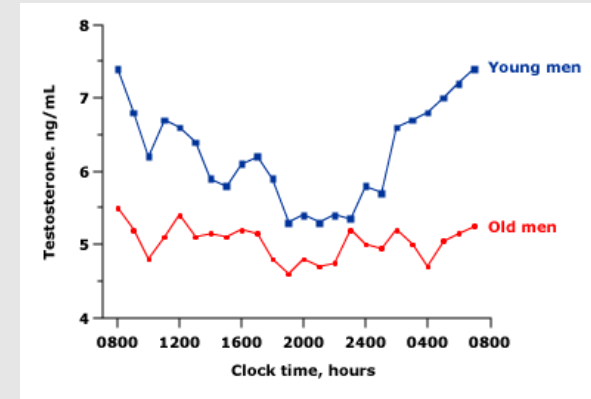
4) CONGENITAL VIOLATION OF SEXUAL DIFFERENTIATION

4.1 MALE HYPOGONADISM 1.4

DIAGNOSTICS

Serum testosterone : 8.00 AM

- Free testosterone: Equilibrium dialysis
- Bioavailable testosterone
- Total testosterone



SHBG ↑	SHBG ↓
<ul style="list-style-type: none">■ moderate obesity■ nephrotic syndrome■ hypothyroidism■ use of glucocorticoids, progestins, androgenic steroids	<ul style="list-style-type: none">■ aging■ cirrhosis■ hyperthyroidism■ use of anticonvulsants, estrogen■ HIV

4) CONGENITAL VIOLATION OF SEXUAL DIFFERENTIATION

4.1 MALE HYPOGONADISM 2.4

DIAGNOSTICS

- Serum FSH,LH
- Semen analysis
- Others
 - Peripheral leukocyte karyotype
 - Other pituitary hormones
 - Serum prolactin
 - Iron saturation
 - MRI brain

4) CONGENITAL VIOLATION OF SEXUAL DIFFERENTIATION

4.1 MALE HYPOGONADISM 3.4

DIAGNOSTICS

Primary hypogonadism

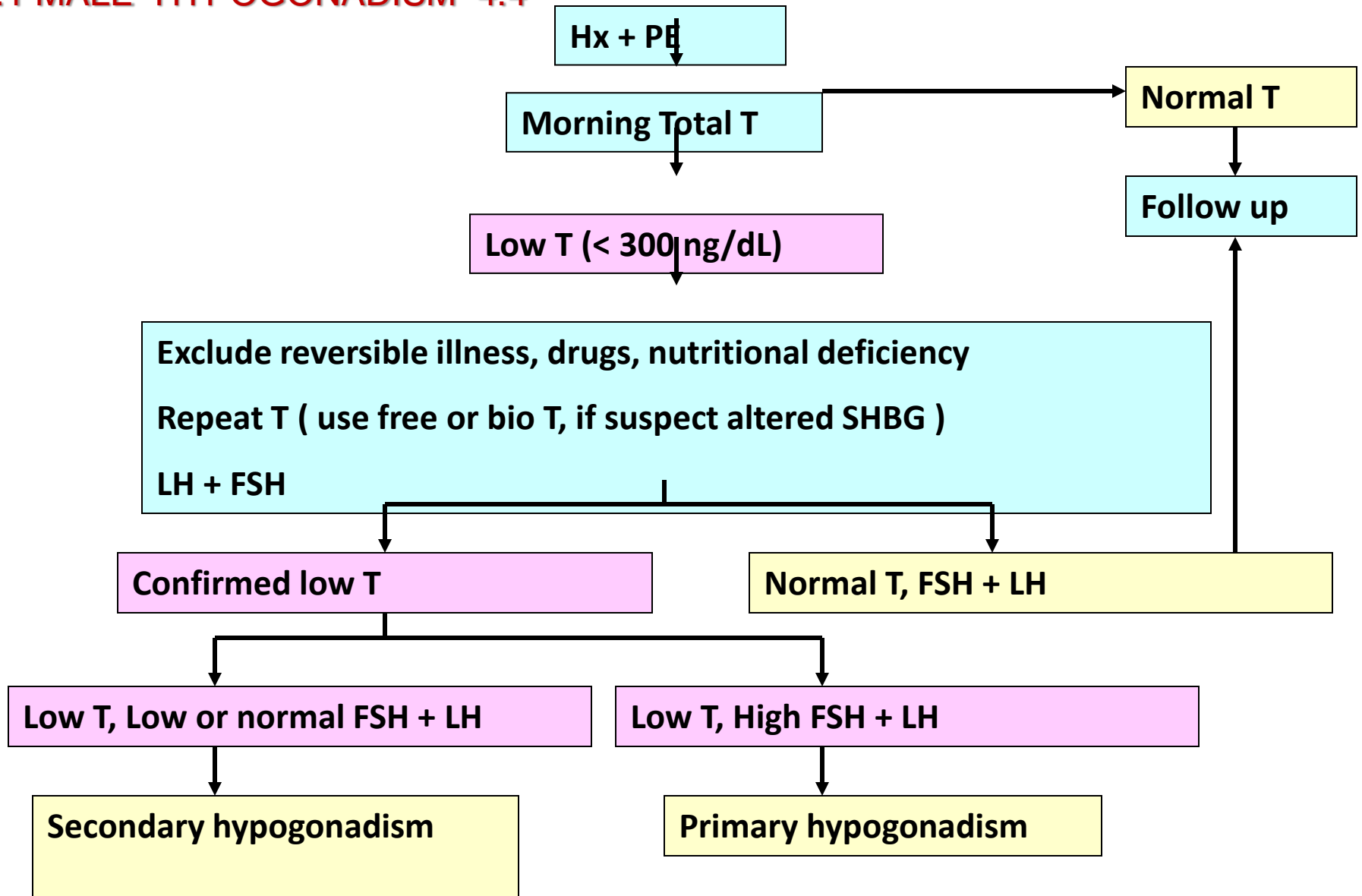
- Testes
- Serum Testosterone ↓, FSH & LH ↑

Secondary hypogonadism

- Pituitary gland or Hypothalamus
- Serum Testosterone ↓, FSH & LH ↔ , ↓

4) CONGENITAL VIOLATION OF SEXUAL DIFFERENTIATION

4.1 MALE HYPOGONADISM 4.4



4) CONGENITAL VIOLATION OF SEXUAL DIFFERENTIATION

4.1 MALE HYPOGONADISM

HOW ARE YOU GOING TO TREAT
HYPOGONADISM?

4) CONGENITAL VIOLATION OF SEXUAL DIFFERENTIATION

4.1 MALE HYPOGONADISM 1.18

TREATMENT

- Testosterone replacement
- Rx. Underlying disease

4) CONGENITAL VIOLATION OF SEXUAL DIFFERENTIATION

4.1 MALE HYPOGONADISM 1.18

DRUGS: 1° HYPOGONADISM

- ↓ Leydig cell production of testosterone
 - Corticosteroids, ethanol, ketoconazole
- ↓ Conversion of testosterone to DHT
 - Finasteride
- Androgen receptor blockers
 - Spironolactone, flutamide, cimetidine

4) CONGENITAL VIOLATION OF SEXUAL DIFFERENTIATION

4.1 MALE HYPOGONADISM 2.18

DRUGS: 2° HYPOGONADISM

↓ Pituitary secretion of gonadotropins

- corticosteroids
- ethanol
- GnRH analogs
- estrogen, progesteron
- medications that raise prolactin levels(opiate, metoclopramide)

4) CONGENITAL VIOLATION OF SEXUAL DIFFERENTIATION

4.1 MALE HYPOGONADISM 3.17

TESTOSTERONE REPLACEMENT

Intramuscular preparations

- Transdermal patch
- Transdermal gel

Oral agent

- Testosterone pellet
- Buccal testosterone tablets

4) CONGENITAL VIOLATION OF SEXUAL DIFFERENTIATION

4.1 MALE HYPOGONADISM 4.17

INTRAMUSCULAR INJECTION

- Short-acting:
 - Testosterone propionate
- Intermediate-acting:
 - Testosterone enanthate
 - Testosterone cypionate
- Long-acting:
 - Testosterone undecanoate

4) CONGENITAL VIOLATION OF SEXUAL DIFFERENTIATION

4.1 MALE HYPOGONADISM 5.17

TESTOSTERONE ENANTHATE

- 250 – 300 mg IM q 3 wk
- Advantage:
 - Relatively inexpensive
 - Flexibility of dosing
- Disadvantage:
 - Peak and valley in serum T level

4) CONGENITAL VIOLATION OF SEXUAL DIFFERENTIATION

4.1 MALE HYPOGONADISM 6.17

Oral testosterone undecanoate (Andriol)

- Dose: 40-80 mg po 2-3 times daily
- Advantage:
 - Convenience
- Disadvantage:
 - Variable clinical response
 - Variable serum T levels

4) CONGENITAL VIOLATION OF SEXUAL DIFFERENTIATION

4.1 MALE HYPOGONADISM 7.17

MONITORING OF TREATMENT

Serum testosterone

- IM: Measured midway between injection
- Oral: Measured after intake 3-5 hr
- 1° hypogonad
- Normalization of serum LH

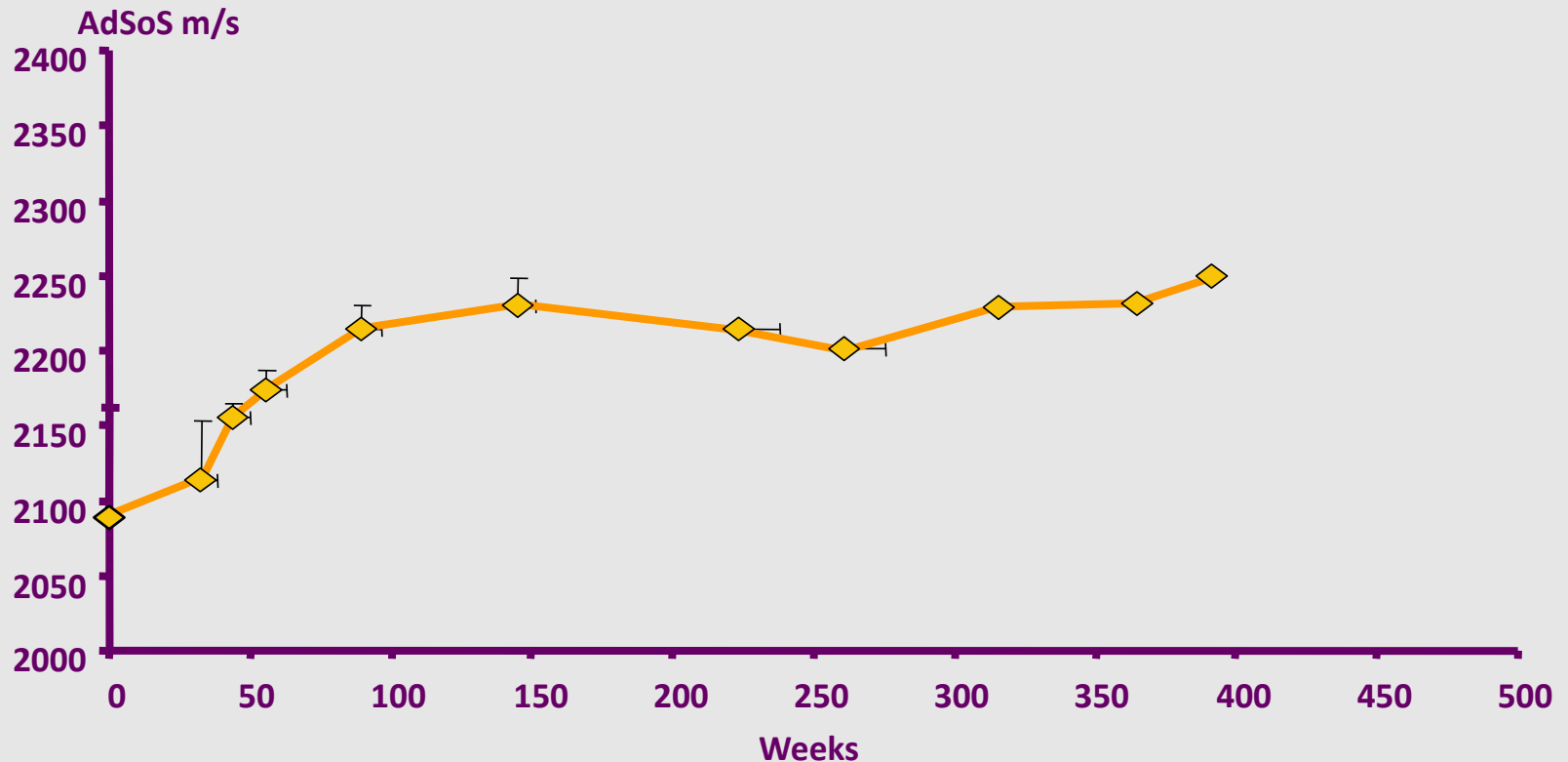
Desirable effect

- Normal and maintained virilization
- Improvement of libido
- Improvement of energy
- Improvement of muscle strength
- Improvement of BMD

4) CONGENITAL VIOLATION OF SEXUAL DIFFERENTIATION

4.1 MALE HYPOGONADISM 8.17

Bone Density Changes with Long-term Treatment*



* Testosterone Undecanoate (Nebido)

4) CONGENITAL VIOLATION OF SEXUAL DIFFERENTIATION

4.1 MALE HYPOGONADISM 9.17

MONITORING OF TREATMENT

UNDESIRABLE EFFECTS

1. Effects on the prostate:

- Benign prostatic hypertrophy
- Prostate cancer

2. Effect on cardiovascular risk

- Lipids

3. Effect on haemopoiesis

- Polycythaemia

4. Effects on the liver

4) CONGENITAL VIOLATION OF SEXUAL DIFFERENTIATION

4.1 MALE HYPOGONADISM 10.17

ANDROGENS AND PROSTATE CANCER

There is no evidence that testosterone treatment causes a prostate cancer

4) CONGENITAL VIOLATION OF SEXUAL DIFFERENTIATION

4.1 MALE HYPOGONADISM 11.17

ANDROGENS AND CARDIOVASCULAR RISK

- Both androgen deficiency and androgen excess are associated with unfavourable lipid profiles and increased CV risk
- Maintaining androgen levels in the physiological range promotes a favourable lipid profile
- Early studies have been conducted in hypogonadal men with angina and chronic heart failure showing benefit from normalisation of testosterone levels
- More researches are needed on CV risk

4) CONGENITAL VIOLATION OF SEXUAL DIFFERENTIATION

4.1 MALE HYPOGONADISM 12.17

ANDROGENS AND POLYCYTHAEMIA

- Clinically significant polycythaemia has been associated with androgen replacement
- More common with conventional injectable (up to 44%*) therapy, where high peak plasma concentrations are found immediately after administration
- Much less common with transdermal (8%) therapy or long-acting injection (Nebido)

4) CONGENITAL VIOLATION OF SEXUAL DIFFERENTIATION

4.1 MALE HYPOGONADISM 13.17

ANDROGENS AND THE LIVER

- Only alkylated testosterone preparations have been associated with liver disease
- Modern testosterone preparations, either biologically identical testosterone or testosterone esters are **NOT** associated with liver disease

4) CONGENITAL VIOLATION OF SEXUAL DIFFERENTIATION

4.1 MALE HYPOGONADISM 14.17

RARELY REPORTED SIDE EFFECTS

Others side effects are rare

- Acne
- Male pattern hair loss
- Hirsutism
- Mood changes

4) CONGENITAL VIOLATION OF SEXUAL DIFFERENTIATION

4.1 MALE HYPOGONADISM 15.17

FOLLOW UP

- Hct q 3 month then annually
- Lipid profile
- LFT (if alkylated testosterone preparations used)
- PSA (if age > 50 yr)
 - > 4 ng/ml
 - ↑ > 1.4 ng/ml within 12 month after Rx.
 - ↑ > 0.4 ng/ml/yr

4) CONGENITAL VIOLATION OF SEXUAL DIFFERENTIATION

4.1 MALE HYPOGONADISM 16.17

MONITORING of TREATMENT

- Time course of effect
 - ↑ fat-free mass, prostate volume, erythropoiesis, energy, and sexual function within 3-6 month

4) CONGENITAL VIOLATION OF SEXUAL DIFFERENTIATION

4.1 MALE HYPOGONADISM 17.17

TREATMENT OF INFERTILITY

- 2° hypogonad only
 1. GnRH pulsatile infusion
 2. hCG (~ LH)
 - + Leydig cell → testosterone
- hMG (~ FSH+LH)
 - + Seminiferous tubule → spermatogenesis

4) CONGENITAL VIOLATION OF SEXUAL DIFFERENTIATION

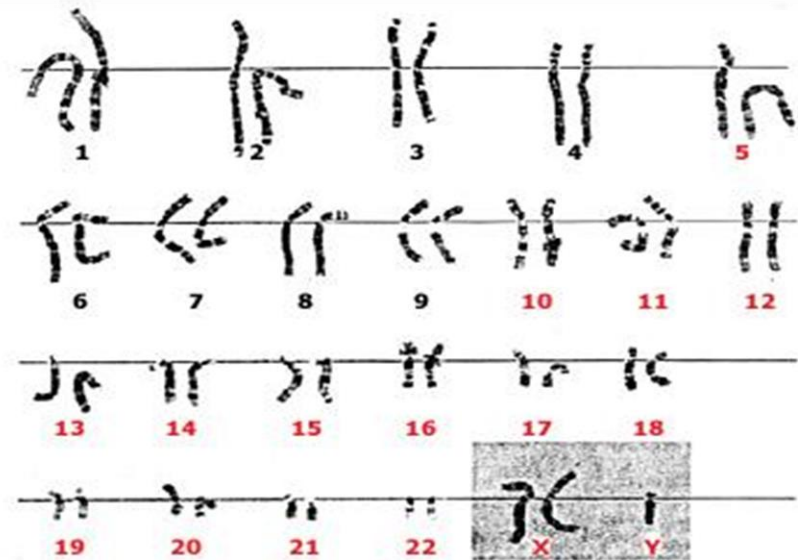
WHAT CONGENITAL VIOLATIONS
OF SEXUAL DIFFERENTIATION DO
YOU KNOW?

4) CONGENITAL VIOLATION OF SEXUAL DIFFERENTIATION

4.2 Klinefelter's syndrome 1.4

KLINEFELTER'S SYNDROME

- Most common congenital abnormality causing primary hypogonadism
- Male who has an extra X chromosome
- Genotype
 - 47,XXY (most common)
 - 48,XXX
 - 46,XY/46,XXY mosaicism
 - 46,XX

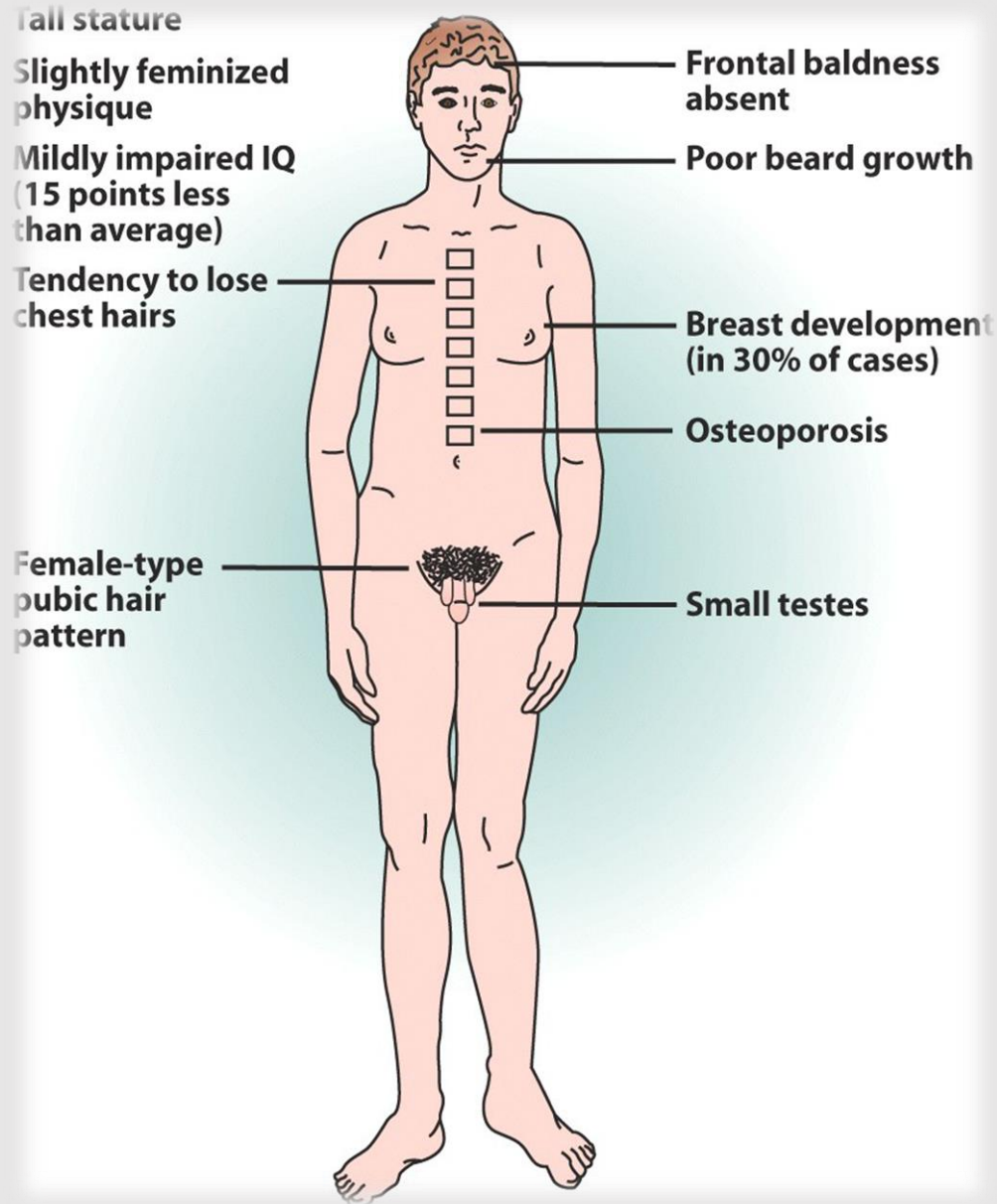


4) CONGENITAL VIOLATION OF SEXUAL DIFFERENTIATION

4.2 Klinefelter's syndrome 2.4

KLINEFELTER'S SYNDROME

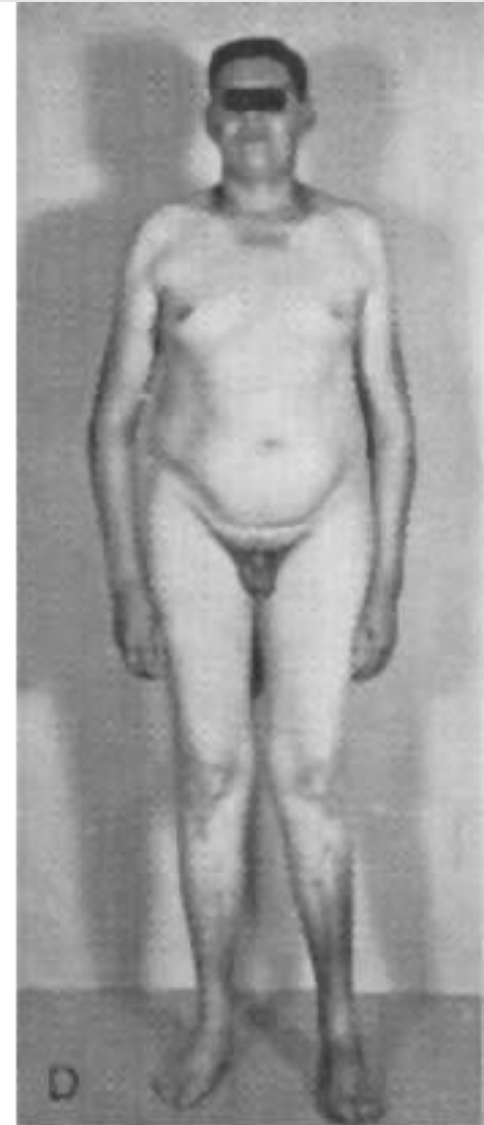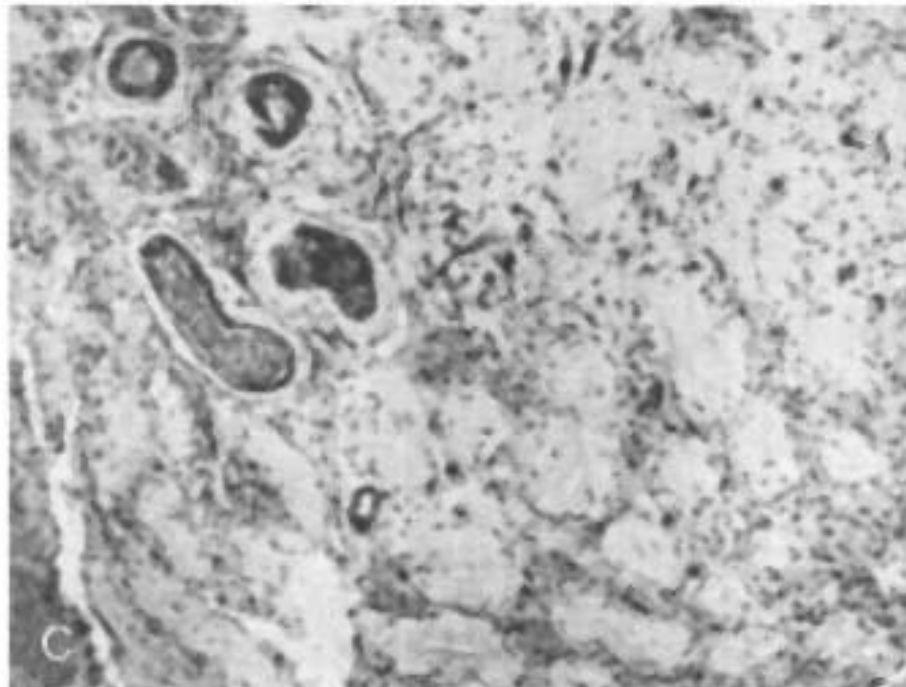
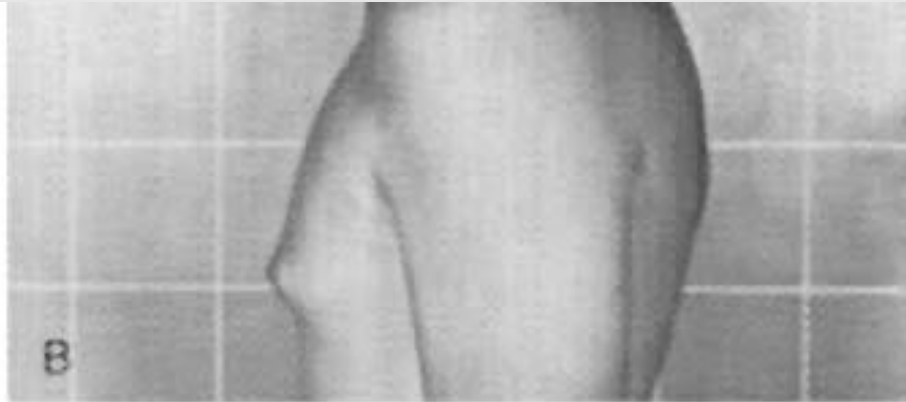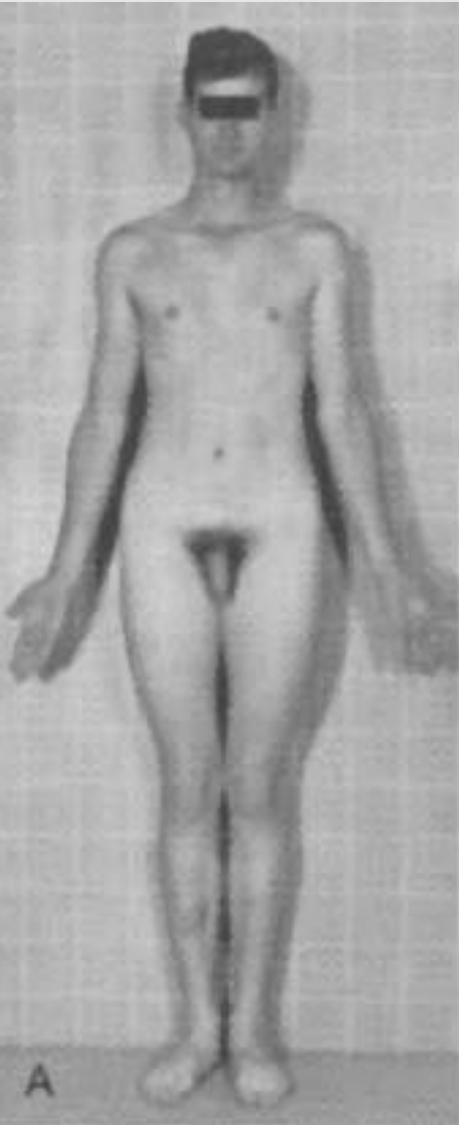- Testes
 - Hyalinization & fibrosis of seminiferous tubule
 - Sertoli cell → inhibin↓ → FSH ↑
- Gynecomastia
 - ↑ peripheral conversion of testosterone
 - ↓ clearance of estradiol
 - Intraductal hyperplasia



4) CONGENITAL VIOLATION OF SEXUAL DIFFERENTIATION

4.2 Klinefelter's syndrome 3.4

KLINEFELTER'S SYNDROME



4) CONGENITAL VIOLATION OF SEXUAL DIFFERENTIATION

4.2 Klinefelter's syndrome 4.4

KLINFELTER'S SYNDROME

Associated with:

- Cancer: CA breast, extragonadal germ cell tumor
- Autoimmune: SLE, SS, RA
- Intelligent & psychology: IQ score, development, memory, depression, psychosis
- Others: DM, DVT, Pulmonary dz. (chronic bronchitis, bronchiectasis, emphysema)

4) CONGENITAL VIOLATION OF SEXUAL DIFFERENTIATION

4.2 Klinefelter's syndrome

Clinical case 1.3

End-stage renal disease and primary hypogonadism associated with a 46,XX karyotype

OBJECTIVE:

- To determine the cause of absent sexual development in a 17-year-old girl with end-stage renal disease

DESIGN--Case study

- PARTICIPANT--Seventeen-year-old girl with end-stage renal failure.
- INTERVENTIONS--None MEASUREMENTS/MAIN RESULTS--The patient had phenotypically normal external female genitalia, mullerian duct hypoplasia, and no ovaries
- Her serum gonadotropin levels were in the castrate range at baseline and after gonadotropin-releasing hormone stimulation. Her karyotype, in lymphocytes and cultured fibroblasts, was 46,XX.

4) CONGENITAL VIOLATION OF SEXUAL DIFFERENTIATION

4.2 Klinefelter's syndrome

Clinical case 2.3

Analysis of genomic dna, following polymerase chain reaction-amplication with oligonucleotide primers corresponding to the Y-encoded zinc finger protein ZFY and the testis-determining SRY gene, showed y chromosome material in a male control but none in the patient. CONCLUSIONS--The results suggest a diagnosis of frasier syndrome, a disorder characterized by true gonadal dysgenesis and end-stage renal disease occurring in normal phenotypic girls. Although previously reported only in individuals with a 46,XX karyotype, our studies indicate that frasier syndrome may also occur in 46,XX girls. Delayed puberty is not uncommon in renal failure. This case illustrates the importance of measuring gonadotropin levels in teenage girls with delayed puberty and renal failure, particularly if the origin of the renal disease is obscure

4) CONGENITAL VIOLATION OF SEXUAL DIFFERENTIATION

4.2 Klinefelter's syndrome

Clinical case 3.3

- Although previously reported only in individuals with a 46,XX karyotype, our studies indicate that frasier syndrome may also occur in 46,XX girls
- Delayed puberty is not uncommon in renal failure
- This case illustrates the importance of measuring gonadotropin levels in teenage girls with delayed puberty and renal failure, particularly if the origin of the renal disease is obscure

4) CONGENITAL VIOLATION OF SEXUAL DIFFERENTIATION

WHAT IS TURNER SYNDROME?

4) CONGENITAL VIOLATION OF SEXUAL DIFFERENTIATION

4.3 Shereshevsky -Turner syndrome 1.1

TURNER SYNDROME

- Turner syndrome (TS) also known as Shereshevsky-Ullrich-Turner syndrome, gonadal dysgenesis, and 45,X, is a condition in which a female is partly or completely missing an X chromosome
- Turner syndrome is not usually inherited from a person's parents
- Environmental risks are known and the mother's age does not play a role
- Turner syndrome is due to a chromosomal abnormality in which all or part of one of the X chromosomes is missing or altered
- While most people have 46 chromosomes, people with TS usually only have 45
- The chromosomal abnormality may be present in just some cells in which case it is known as TS with mosaicism

4) CONGENITAL VIOLATION OF SEXUAL DIFFERENTIATION

WHAT CAUSES OF TURNER
SYNDROME DO YOU KNOW?

4) CONGENITAL VIOLATION OF SEXUAL DIFFERENTIATION

4.3 Shereshevsky -Turner syndrome 1.1

TURNER SYNDROME CAUSES

- Turner syndrome is caused by the absence of one complete or partial copy of the X chromosome in some or all the cells
- The abnormal cells may have only one X (monosomy) (45,X) or they may be affected by one of several types of partial monosomy like a deletion of the short p arm of one X chromosome (46,X,del(Xp)) or the presence of an isochromosome with two q arms (46,X,i(Xq))
- In mosaic individuals, cells with X monosomy (45,X) may occur along with cells that are normal (46,XX), cells that have partial monosomies, or cells that have a Y chromosome (46,XY)
- The presence of mosaicism is estimated to be relatively common in affected individuals (67–90%)

4) CONGENITAL VIOLATION OF SEXUAL DIFFERENTIATION

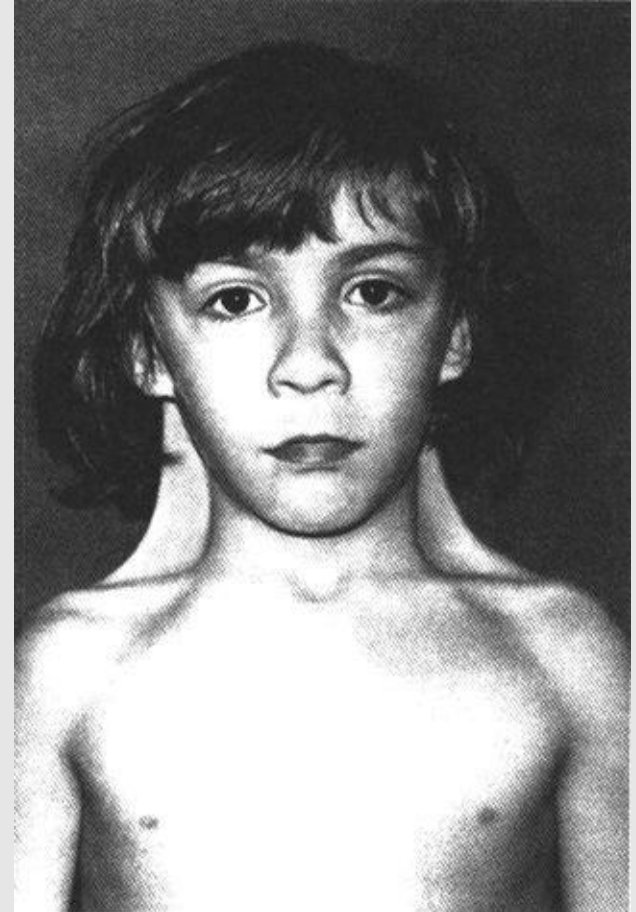
**SIGNS AND SYMPTOMS OF TURNER
SYNDROME?**

4) CONGENITAL VIOLATION OF SEXUAL DIFFERENTIATION

4.3 Shereshevsky -Turner syndrome 1.4

SIGNS AND SYMPTOMS

- Of the following common symptoms of Turner syndrome, an individual may have any combination of symptoms and is unlikely to have all symptoms
- [Lymphedema](#), puffy legs of a newborn with Turner syndrome
- Short stature
- [Lymphedema](#) (swelling) of the hands and feet
- Broad chest (shield chest) and widely spaced nipples
- Low hairline
- Low-set ears
- Reproductive sterility
- Rudimentary ovaries gonadal streak (underdeveloped gonadal structures that later become fibrotic)

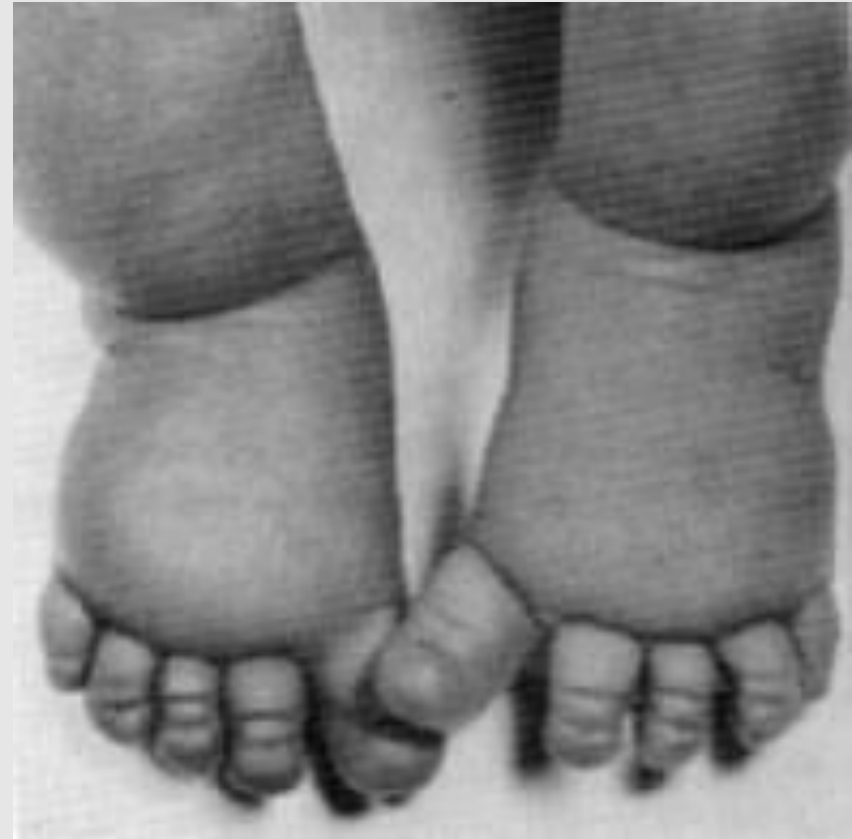

4) CONGENITAL VIOLATION OF SEXUAL DIFFERENTIATION

4.3 Shereshevsky -Turner syndrome 2.4

SIGNS AND SYMPTOMS

- Amenorrhoea, the absence of a menstrual period
- Increased weight, obesity
- Shortened metacarpal IV
- Small fingernails
- Characteristic facial features
- Webbed neck from cystic hygroma in infancy
- Aortic valve stenosis
- Coarctation of the aorta



4) CONGENITAL VIOLATION OF SEXUAL DIFFERENTIATION

4.3 Shereshevsky -Turner syndrome 3.4

Signs and symptoms

- Bicuspid aortic valve
- Horseshoe kidney
- Visual impairments – sclera, cornea , glaucoma, etc.
- Ear infections and hearing loss
- High waist-to-hip ratio (the hips are not much bigger than the waist)
- Attention deficit hyperactivity disorder (problems with concentration, memory, attention with hyperactivity seen mostly in childhood and adolescence)

4) CONGENITAL VIOLATION OF SEXUAL DIFFERENTIATION

4.3 Shereshevsky -Turner syndrome 4.4

SIGNS AND SYMPTOMS

- Nonverbal learning disability (problems with math, social skills, and spatial relations)
- Other features may include a small lower jaw (micrognathia), cubitus valgus, soft upturned nails, palmar crease, and drooping eyelids. Less common are pigmented moles, hearing loss, and a high-arch palate (narrow maxilla). Turner syndrome manifests itself differently in each female affected by the condition; therefore, no two individuals share the same features.
- While most of the physical findings are harmless, significant medical problems can be associated with the syndrome

TREATMENT OF TURNER'S SYNDROME?

4) CONGENITAL VIOLATION OF SEXUAL DIFFERENTIATION

4.3 Shereshevsky -Turner syndrome 1.1

TREATMENT

- Treatment may help with symptoms
- Human growth hormone injections during childhood may increase adult height
- Estrogen replacement therapy can promote development of the breasts and hips
- Medical care is often required to manage other health problems with which TS is associated

4) CONGENITAL VIOLATION OF SEXUAL DIFFERENTIATION

4.3 Shereshevsky -Turner syndrome

Clinical case 1.1

- An eighteen years old girl came from Ishargang, Mymensingh complaining of short stature, absence of development of breast, lack of menstruation and other secondary sex characters.
- She was found in infantile appearance with a height of 123 cm, body weight of 28 kg
- She had short, broad, webbed neck, cuvitus valgus, absence of development of breast, axillary and public hairs with infantile external genitalia. Hormonal profile revealed high level of LH and FSH, low level of estrogens
- Ultrasonography revealed uterine hypoplasia and ill defined gonadal streaks, karyotype showed typical 45, X0 pattern
- She was diagnosed as a case of gonadal dysgenesis due to turner syndrome

4) CONGENITAL VIOLATION OF SEXUAL DIFFERENTIATION

WHAT IS TRUE
HERMAPHRODITISM?

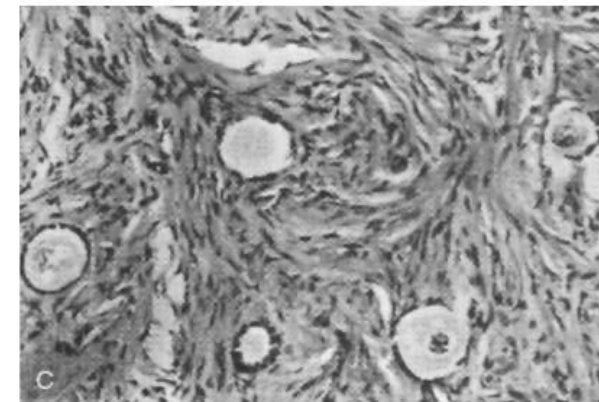
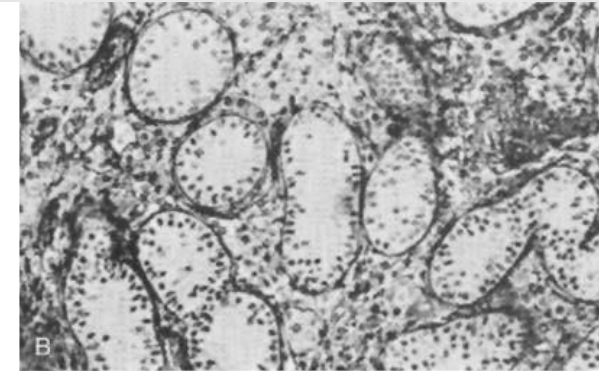
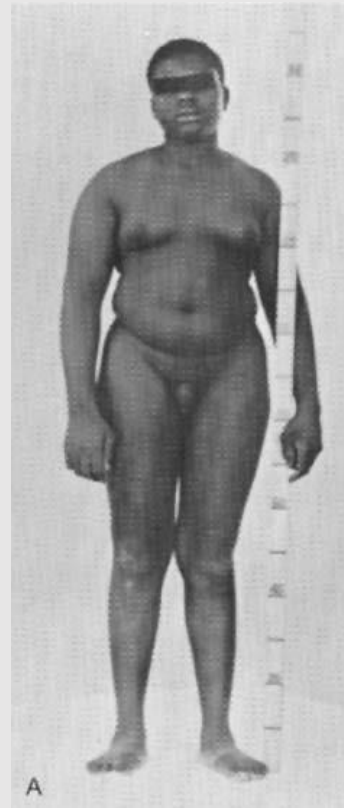
4) CONGENITAL VIOLATION OF SEXUAL DIFFERENTIATION

4.4 syndrome of hermaphroditism 1.5

TRUE HERMAPHRODITISM

Individuals who have both testicular tissue with well-developed seminiferous tubules and ovarian tissue with primordial follicles, which may take the form of one ovary and one testis or, more commonly, one or two ovotestes.

External genitalia and internal duct structures of true hermaphrodites display gradations between male and female



4) CONGENITAL VIOLATION OF SEXUAL DIFFERENTIATION

4.4 syndrome of hermaphroditism 2.5

TRUE HERMAPHRODITISM

- **In most patients, the external genitalia are ambiguous but masculinized to variable degrees, and 75% are raised as male**
- **Internal ductal development are influenced by ipsilateral gonad**
 - Fallopian tubes are consistently present on the side of the ovary
 - a vas deferens is always present adjacent to a testis
 - Fallopian tube is present with 66% of ovotestes, vas or both in 33%
 - Most have urogenital sinus and uterus
- 80% of those raised as male have hypospadias and chordae
- Ovaries usually on left in normal position, testis usually on right and located anywhere along path of descent
- 60% of gonads palpable in canal or labia are ovotestes

4) CONGENITAL VIOLATION OF SEXUAL DIFFERENTIATION

4.4 syndrome of hermaphroditism 3.5

TRUE HERMAPHRODITISM

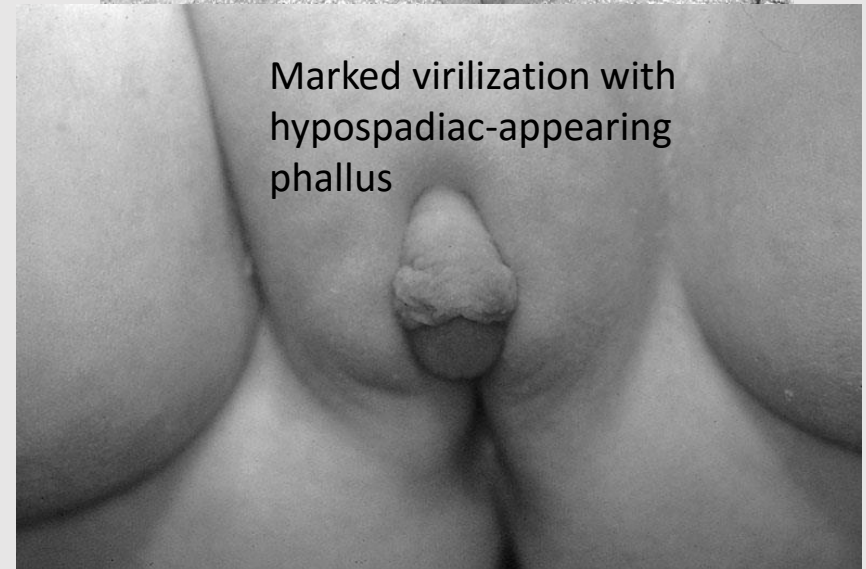
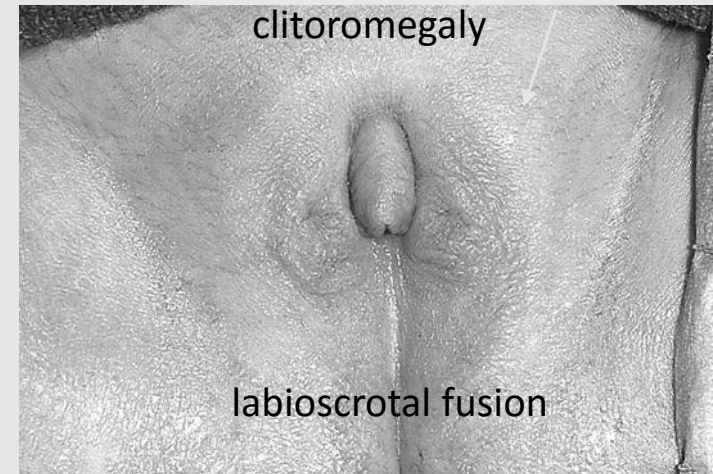
- Ovarian portion of the ovotestis is frequently normal, whereas the testicular portion is typically dysgenetic
- 66% of patients are 46 XX
- Tumors of Gonads are approximately 10% in 46,XY true hermaphroditism and 4% in 46,XX true hermaphroditism
- Most important aspect of management in true hermaphroditism is gender assignment
- Sex assignment should be based on the functional potential of external genitalia, internal ducts, and gonads, according to the findings at laparoscopy or laparotomy.
- **Unlike patients with most other forms of gonadal dysgenesis, true hermaphrodites have the potential for fertility if raised as female with the appropriate ductal structures**
- Males with ovaries and/or ovotestis and mullerian duct structures consider gonadectomy.
- Females with testicular and wolffian duct structures consider gonadectomy.

4) CONGENITAL VIOLATION OF SEXUAL DIFFERENTIATION

4.4 syndrome of hermaphroditism 4.5

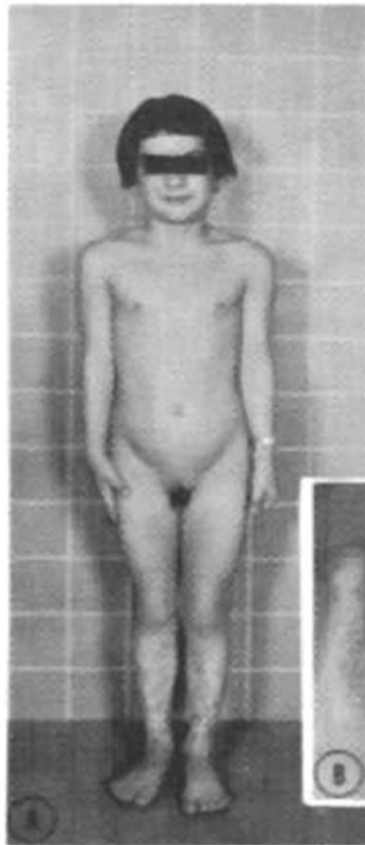FEMALE PSEUDOHERMAPHRODITISM

- 46,XX individuals with ovaries have a partially masculinized phenotype and ambiguous genitalia
- CAH is most common cause
- Uncommon etiologies:
 - Maternal ingestion of androgens
 - Virilizing tumors in the mother

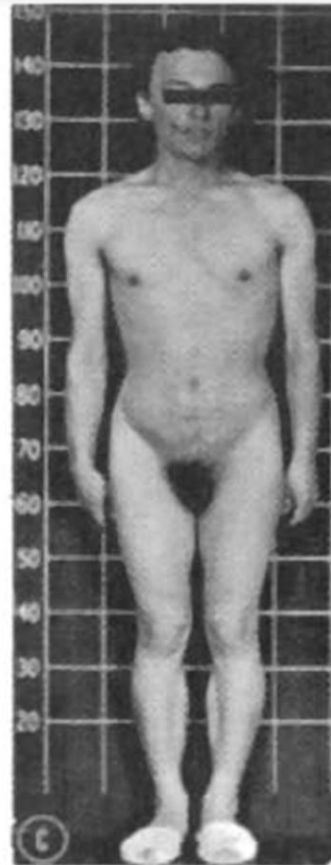

4) CONGENITAL VIOLATION OF SEXUAL DIFFERENTIATION

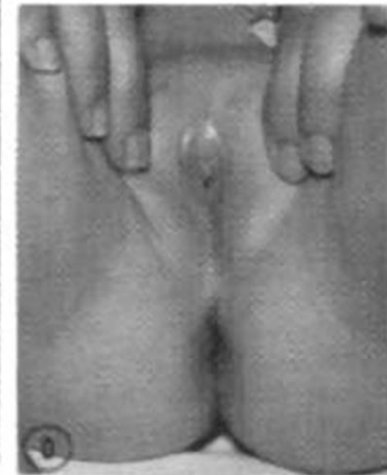4.4 syndrome of hermaphroditism 5.5



ADRENAL HYPERPLASIA



ADRENAL HYPERPLASIA



MATERNAL PROGESTINS
8th to 12th FETAL WEEK

FEMALE PSEUDOHERMAPHRODITISM

AGE -----	4 1/2 yrs.	23 yrs.	8 yrs.
HT. AGE ----	5 yrs.	1 yrs.	8 yrs.
BONE AGE -	9 yrs.	ADULT	8 1/2 yrs.
17 K.S. ----	6.0mgm /24 hrs.	50 mgm/24 hrs	1.8 mgm/24 hrs.
Pregnanetriol	13.6mgm /24 hrs.	—	<0.5 mgm /24 hrs.

4) CONGENITAL VIOLATION OF SEXUAL DIFFERENTIATION

4.4 syndrome of hermaphroditism

Clinical case 1.10

- A 3-year-old patient presented in outpatient department of Sheikh Zayed Hospital Rahim Yar Khan. This child was reared as male and chief complaint was the absence of left testicle in the scrotum along with passage of urine from an abnormal urethral opening at the junction of penis and scrotum. A surgical procedure was performed at 18 months of age to straighten the penis and few injections (testosterone) were given to increase the size of penis, although no record was available

4) CONGENITAL VIOLATION OF SEXUAL DIFFERENTIATION

4.4 syndrome of hermaphroditism

Clinical case 2.10

On examination left testicle was not palpable in the scrotum or inguinal canal. Right testicle was palpable in the scrotum and was of adequate size according to the age of child. Phallus examination showed scar mark on the ventral surface of penis and meatal opening was present at penoscrotal junction. Penis was about 4 cm long with 1.5 cm diameter. All routine investigations were within normal range. Testosterone level was 2.50 micro gram/ dl (normal value 30-50). Barr body test was negative. Karyotyping was 46 XY. Ultrasound report showed left undescended testis which was not visible in inguinal canal or abdomen. No Mullerian structures were noted. A diagnosis of left undescended testis (UDT) with penoscrotal hypospadias was made

4) CONGENITAL VIOLATION OF SEXUAL DIFFERENTIATION

4.4 syndrome of hermaphroditism

Clinical case 3.10

- Abdominal exploration for UDT revealed Mullerian structures (ovary, unicornuate uterus, fallopian tube and cervix) on left side
- On Right side vas and vessels were found into deep inguinal ring
- After counseling with the parents it was planned to rear this child as male due to predominant male phenotype
- The persistent Mullerian structures were excised and sent for histopathology

4) CONGENITAL VIOLATION OF SEXUAL DIFFERENTIATION

4.4 syndrome of hermaphroditism

Clinical case 4.10

- Biopsy was taken from Right testicle in order to find any dysgenesis or ovotesticular tissue
- Biopsy report confirmed ovary, fallopian tube and uterus on left side
- Right testicular biopsy showed normal histology with seminiferous tubules without any dysgenesis or ovarian tissue

4) CONGENITAL VIOLATION OF SEXUAL DIFFERENTIATION

4.4 syndrome of hermaphroditism

Clinical case 5.10

Figure 1: Showing ovary and fallopian tubes.



4) CONGENITAL VIOLATION OF SEXUAL DIFFERENTIATION

4.4 syndrome of hermaphroditism

Clinical case 6.10

DISCUSSION

- Disorder of sexual differentiation is the terms used for a child born without clear male or female phenotype. The term “hermaphrodite” is derived from Greek mythological God “Hermaphroditos” son of Hermes and Aphrodite, whose body after being merged with nymph Salmakis assumed a more perfect form with both male and female attributes .
- Proper gender assignment to a neonate born with DSD is a social emergency of the newborn period. Infants and children born with DSD pose a diagnostic and therapeutic challenge to the clinicians. Success depends upon rapid and precise diagnosis, appropriate gender assignment, proper medical therapy and meticulous surgical technique

4) CONGENITAL VIOLATION OF SEXUAL DIFFERENTIATION

4.4 syndrome of hermaphroditism

Clinical case 7.10

- The causes of true hermaphroditism remain enigmatic and the commonest presentation is an abnormal external genitalia ranging from normal male to normal female. In many of these cases such distinction may not be present and chordee, hypospadias and cryptorchidism may be noted
- Similar picture is found in our case
- Other presenting symptoms are hematuria, amenorrhea, lower abdominal pain and inguinal hernia

4) CONGENITAL VIOLATION OF SEXUAL DIFFERENTIATION

4.4 syndrome of hermaphroditism

Clinical case 8.10

- Documentation of location of gonads is important. In true hermaphrodites gonads are always asymmetrical with predominant testis descends and predominant ovary lies in the abdomen above the external ring as noted in index case
- On the basis of location of gonads and histology these patients are classified as:
- Lateral: Testis and contralateral ovary (30%)
- Bilateral: Testicular and ovarian tissue identified on both sides, usually as ovotestis (50 %)

4) CONGENITAL VIOLATION OF SEXUAL DIFFERENTIATION

4.4 syndrome of hermaphroditism

Clinical case 9.10

- Unilateral: Ovotestis on one side and testis or ovary on other side (20%)
- Our patient was of lateral variety in which testis was on right side and ovary on left side
- The choice of rearing hermaphrodite as male or female sex is governed by phallus size
- In our patient penis was of adequate size thus plan in consultation with parents was made to rear him as a male
- All female structures were thus removed
- A repair of hypospadias will be performed in the next stage
- Prosthesis can be placed in left hemiscrotum for psychological comfort

4) CONGENITAL VIOLATION OF SEXUAL DIFFERENTIATION

4.4 syndrome of hermaphroditism

Clinical case 10.10

- True hermaphroditism is rarely associated with gonadal tumours, unlike in mixed gonadal dysgenesis, where the presence of a dysgenetic gonad predisposes to gonadal malignancy
- However a few cases of malignancies like dysgerminoma and gonadoblastoma have been reported in true hermaphroditism
- Hence this patient will require close follow up to diagnose any malignancy arising in his remaining testis. Since the incidence of gonadal malignancy is low, estimated at 4.6 %, prophylactic removal of his remaining testis is not justified.
- Our case was unique as chromosomal analysis was 46 XY, which is very rare in a case of true hermaphrodite DSD

4) CONGENITAL VIOLATION OF SEXUAL DIFFERENTIATION

WHAT IS CRYPTORCHIDISM?

4) CONGENITAL VIOLATION OF SEXUAL DIFFERENTIATION

4.5 cryptorchidism 1.4

CRYPTORCHIDISM

- Cryptorchidism is a congenital condition in which one or both testicles are not appropriately positioned in the scrotum at birth
- Cryptorchidism may be unilateral or bilateral, and the undescended testicles may be palpable or nonpalpable
- The undescended testicles may be present in the abdomen or the groin area or misplaced in the scrotum
- The undescended testicles may be functional or atrophied
- Some individuals have no testicles at all (anorchia)

4) CONGENITAL VIOLATION OF SEXUAL DIFFERENTIATION

4.5 cryptorchidism 2.4

THE ETIOLOGY OF CRYPTORCHIDISM

- The etiology of cryptorchidism is not well understood
- Cryptorchidism affects an estimated 3 percent of full-term male neonates and up to 30 percent of premature infants
- About 70 percent of cryptorchid testicles spontaneously descend within the first year of life
- However, the number of boys whose condition persists after this period remains constant at approximately 1 percent
- Long-term consequences of cryptorchidism may include testicular malignancy and infertility/subfertility

4) CONGENITAL VIOLATION OF SEXUAL DIFFERENTIATION

4.5 cryptorchidism 3.4

TREATMENT STRATEGY FOR CRYPTORCHIDISM

The appropriate evaluation and treatment strategy for cryptorchidism may

be influenced by many factors including:

Whether or not the testicle is palpable

Whether the condition is present unilaterally or bilaterally

The age at presentation

Comorbid conditions

The majority of undescended testicles (UDTs) can be located on physical examination.

For locating nonpalpable UDTs, exploratory laparoscopic surgery is routinely used in clinical practice

4) CONGENITAL VIOLATION OF SEXUAL DIFFERENTIATION

4.5 cryptorchidism 4.4

TREATMENT STRATEGY FOR CRYPTORCHIDISM

- Treatment for cryptorchidism is usually initiated between the ages of 6 months and 1 year
- There are three key surgical options commonly used to treat cryptorchidism
- Surgical options depend on the location and appearance of the undescended testicle and include:
 - Primary orchiopexy
 - Single-stage Fowler-Stephens orchiopexy
 - Two-stage Fowler-Stephens orchiopexy

5) MENOPAUSE

WHAT IS CLIMACTERIC?

STAGES OF CLIMACTERIC?

5) MENOPAUSE 1.2

MENOPAUSE The term menopause is derived from Greek Meno (months) and pause (cessation). The word means cessation of menstruation

Climacteric of physical and emotional change that precedes that accompanies menopause. These changes usually occur gradually over a period of year, though the time may vary from six months to as long as five years or more

Climacteric consists of three stages:

PRE-MENOPAUSE (the transition between fertility and the last menstrual period)

MENOPAUSE (when periods have actually ceased for a year)

POST-MENOPAUSE (the years after the end of menstruation)

5) MENOPAUSE 2.2

PATHOPHYSIOLOGY

- The number of primordial follicle declines even before birth but dramatically just before menopause.
- Increased FSH, LH from about 10 years before menopause
- Close to menopause: There will be -anovulation
- -inadequate Leuteal phase → decreased progesterone but not estrogen level → leads to DUB and endometrial Hyperplasia
- - at menopause dramatic decrease of estrogen → menstruation ceases and symptoms of menopause started
- But still ovarian stroma produces →small amount of androstenedione and testosterone but, main postmenopausal estrogen is estrone produced by Peripheral fat from adrenal androgen

5) MENOPAUSE

WHAT KINDS OF SYMPTOMS OF
MENOPAUSE DO YOU KNOW?

5) MENOPAUSE 1.9

SYMPTOMS OF MENOPAUSE:

1. Hot flushes cutaneous vasodilation

- occurs in 75% of women
- more severe after surgical menopause
- continue for 1 year
- 25% continue more than 5 years

3. Urinary Symptoms

- urgency
- frequency
- nocturia

2. Psychological changes decreased

level of central neurotransmitters

- Depression
- Irritability
- Anxiety
- Insomnia
- lose of concentration

5) MENOPAUSE 2.9

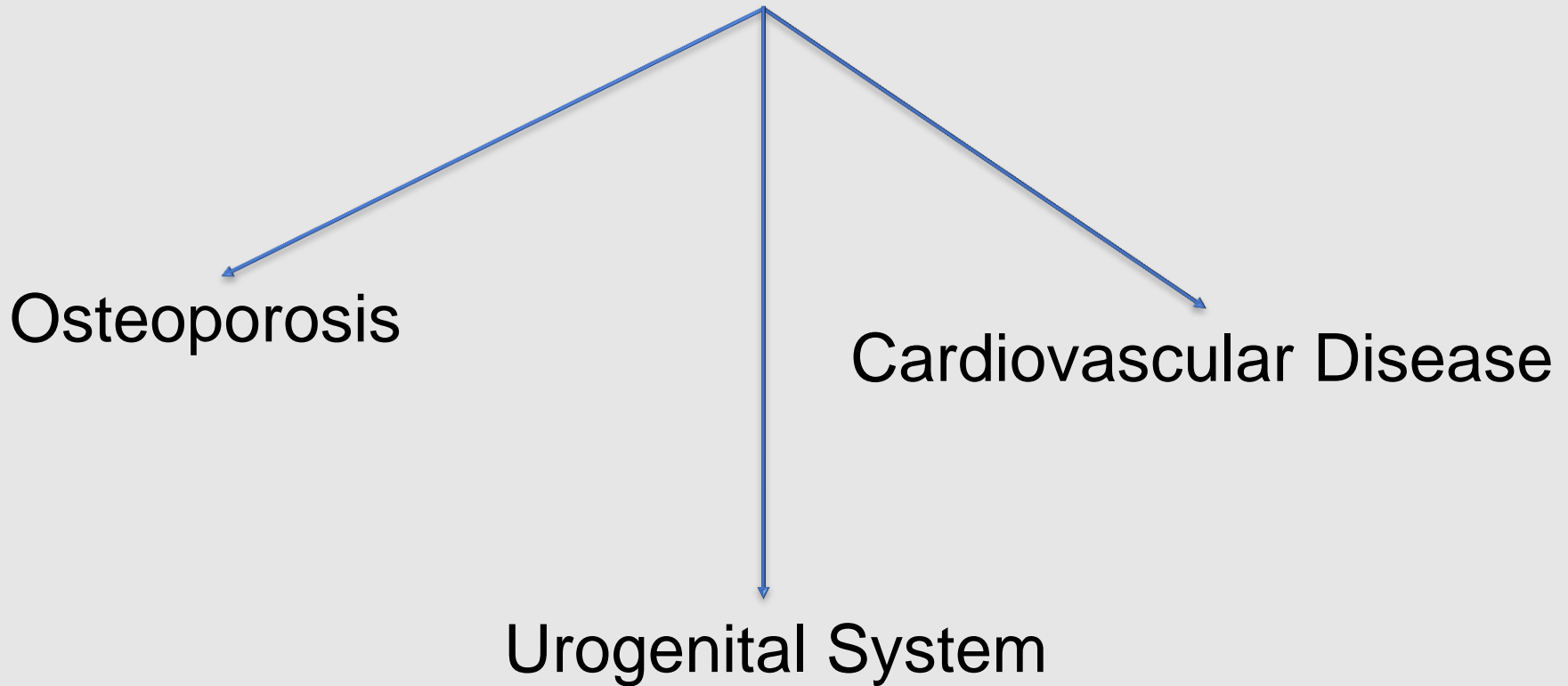
SYMPTOMS OF MENOPAUSE:

4. Atrophic Changes

- Vagina
 - *vaginitis due to thinning of epithelium, ↓ PH and lubrication
 - *dysparnue → due to decrease vascularity and dryness
 - Decrease size of cervix and mucus with retract of segumocolumnar (SC) junction into the endocervical cana
 - Decrease size of the uterus, shrinking of myoma & adenomyosis.
 - Decrease size of ovaries, become non palpabl
 - Pelvic floor - relaxation →prolapse
 - Urinary tract →atrophy →lose of urethral tone →caruncle
Hypertonic Bladder - detrusor instability
 - Decrease size of breast and benign cysts
5. Skin Collagen – ↓ collagen & thickness → ↓ elasticity of the skin
6. Reversl of premenstural syndrom

5) MENOPAUSE 3.9

LATE EFFECT OF MENOPAUSE



5) MENOPAUSE 4.9

LATE EFFECT OF MENOPAUSE

Osteoporosis:

- bone mass reaches peak at the end of 3rd decade of life.
- After 40years bone resorption exceeds bone formation by 0.5% per year.
- This negative balance increases after menopause to a lose of 5% of bone per year.

Risk factors:

- Gender: more in women (male to female ratio is 1:3),BMI
- Race: high in white women, moderate in Asian women, lowest in Black women
- Family History Life style: smoking, caffeine intake, alcohol, increase in protein diet, decrease in Calcium and Vit D intake
- Steriod Medication: exogenous medication, Cushing Syndrome

5) MENOPAUSE 5.9

LATE EFFECT OF MENOPAUSE

Medication

- a. ERT (Estrogen Replacement Therapy)
- b. Biphosphonate (Fosamax) that inhibit osteoclastic activity & minimal S/E
- c. Raloxifene (Evista) is selective oestrogen receptors moderator [SERMs] that bind with a high affinity to estrogen receptors. It has some oestrogen like effect e.g. ↑ bone density, ↓LDL Cholesterol [cardioprotective] but act as estrogen antagonist on endometrium and breast
- d. Calcitonin inhibit osteoclastic activity + analgesic effect of
- e. Calcium Supplement & Vit D

Prevention

- IMPROVE LIFESTYLE - REGULAR EXERCISE - ELIMINATE SMOKING & ALCOHOL

5) MENOPAUSE 6.9

LATE EFFECT OF MENOPAUSE

CARDIOVASCULAR DISEASE

CVD is now the leading cause of death among post menopausal women

-before menopause, risk of heart attack is 1/3 of man

-after menopause increase in women become the same of man at an age of 70years

5) MENOPAUSE 7.9

LATE EFFECT OF MENOPAUSE CARDIOVASCULAR DISEASE

Because of effect of oestrogen:

Before menopause:

- increased HDL & decreased LDL
- decreased Atherogenic plaque formation by direct action on vascular endothelium

After menopause:

- HDL : LDL ratio becomes closer to male ratio
- Observational Studies :HRT decreases mortality by 30%. But recent studies do not show a beneficial effect of HRT on CHD but there is increased number of Breast Cancer when compared with non users of HRT

5) MENOPAUSE 8.9

LATE EFFECT OF MENOPAUSE

UROGENITAL SYSTEM

- Embryologically female genital tract & lower urinary system develop in close proximity from primitive urogenital sinus
 - The Urethra and vagina have a high concentration of estrogen receptors and there is significant evidence to support one use of estrogen in treatment of urogenital symptoms such as (recurrent UTI, vaginitis ad dysparunia)
 - AL Zheimer's Disease -prevalence of Dementia as high 50% by age 85 years. ALZheimer 's disease account for 60-65% of cases. Observation studies decrease risk of Al Zheimer's by 1/3 among women taking HRT.
- It has beneficial effect on brain function but no randomized studies to confirm observational data

DIAGNOSIS AND INVESTIGATIONS:

1. The Triad of:

- Hot flushes
- Amenorrhea
- increase FSH > 15 i.u./L

2. Before starting treatment: You should perform

- breast self examination
- mammogram
- pelvic exam (Pap Smear)
- weight, Blood pressure

3. No indication to perform

- bone density
- Endometrial Biopsy

but any bleeding should be investigated before starting any treatment

5) MENOPAUSE

YOUR TREATMENT PLAN FOR
PERIOD OF MENOPAUSE?

5) MENOPAUSE 1.5

TREATMENT

- Estrogen – a minimum of 2mg of oestradiol are needed to maintain bone mass and relief symptoms of menopause.
- Women with uterus – add progestin at last 10 days of cycle to prevent endometrial Hyperplasia
- Using oestrogen or oestrogen & Progetin

5) MENOPAUSE 3.5

BENEFITS OF HRT:

- Vagina-↑ vaginal thickness of epithelium →↓ dysparunia & vaginitis
- Urinary tract – enhancing normal bladder function
- Osteoporosis – decreases fractures by more than 50%
- CVS – decreases by 30% by observation studies but recent studies shows no benefits
- Colon Cancer decreases up to 50%

5) MENOPAUSE 4.5

CONFIRMED RISK:

- Endometrial CA eliminated by
 1. Adding Progesterone
 2. Using selective oestrogen receptors modulators (SERMS).
- Gall Bladder Disease
 - ERT: ↑ triglyceride, ↑ total cholesterol, increase risk of Gall stone
- Breast Cancer risk with long term HRT adds
 - 2/1000 after 5 years – 6/1000 – 10years
 - 12/1000 after 15 years – background risk 45/1000 between the age of 50 and 70 not taken HRT

5) MENOPAUSE 5.5

CONTRAINDICATIONS TO HRT

- Undiagnosed vaginal bleeding
- Acute liver disease
 - chronic impaired liver functions
- Acute vascular thrombosis
- Breast Cancer

CLINICAL ENDOCRINOLOGY TESTS

Test 1

A 49-year-old female patient complains of itching, burning in the external genitals, frequent urination. The symptoms have been present for the last 7 months. The patient has irregular menstruation, once every 3-4 months. Over the last two years she has had hot flashes, sweating, sleep disturbance. Examination revealed no pathological changes of the internal reproductive organs. Complete blood count and urinalysis showed no pathological changes. Vaginal smear contained 20-25 leukocytes per HPF , mixed flora. What is the most likely diagnosis?

- A. Menopausal syndrome
- B. Cystitis
- C. Trichomonas colpitis
- D. Vulvitis
- E. Bacterial vaginosis

Test 2

A 25-year-old female patient complains about

Having amenorrhea for 3 years. She associates it with difficult labour complicated by massive hemorrhage. She also complains of loss of weight, hair fragility and loss, lack of appetite and depression. Objective examination reveals no pathological changes of uterus and its appendages. What is the disease pathogenesis?

- A. Hypoproduction of gonadotropin
- B. Hyperproduction of estrogens
- C. Hyperproduction of androgens
- D. Hypoproduction of progesterone
- E. Hyperproduction of prolactin

RECOMMENDED LITERATURE

- Oxford American Handbook of Endocrinology and Diabetes Boris Draznin, MD, PhD, Sol Epstein, MD (2011).
- Harrison's principles of internal medicine. (18th ed.). New York: McGraw-Hill Dayan CM, Daniels GH (1996)
- The endocrine system at a glance / Ben Greenstein, Diana Wood. – 2011 - 3rd ed.p.