

Difficulties in rare diseases diagnostics: a clinical case of Weber-Christian disease.

Speakers: 5th course student Ben Abdalla M.R.

Supervisers: prof. Yabluchansky M.I.

ass. prof. Golubkina E.A.,

ass. prof. Silenko I.Y



Introduction

- ❑ Diagnostics of rare diseases can be a real challenge for the practitioner; the problem may be not only lack of experience in the recognition of rare diseases, but also an inadequate professional vigilance.
- ❑ **A rare disease** is defined by the European Union as one that affects less than 5 in 10,000 of the general population. There are between 6,000 and 8,000 known rare diseases and around five new rare diseases are described in medical literature each week.
- ❑ 80% of rare diseases have a genetic component. Often rare diseases are chronic and life-threatening. Rare diseases can be single gene, multifactorial, chromosomal or non-genetic.



http://www.kbs-frb.be/uploadedImages/KBS-FRB/Files/Kaft_-_Logo/rare%20diseases.jpg

Panniculitis

Panniculitis – group of heterogeneous inflammatory diseases, characterized by lesions of subcutaneous fat layer of the skin with involvement in the process of musculoskeletal system and internal organs.

- ❑ There is no uniform concept of etiology and pathogenesis of panniculitis. A role in the development of panniculitis can play infections (viral, bacterial), trauma, hormonal and immune disorders, medications, diseases of the pancreas, cancer etc.
- ❑ The pathogenesis of panniculitis lie in disorders of lipid peroxidation. In the organs and tissues there is an accumulation of highly active intermediate products of oxidation. They inhibit the activity of certain enzymes and disrupt the permeability of cell membranes, which leads to degeneration of cell structures and cytolysis.

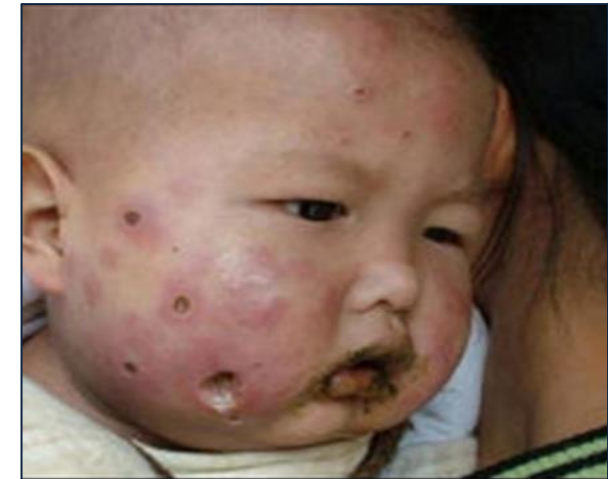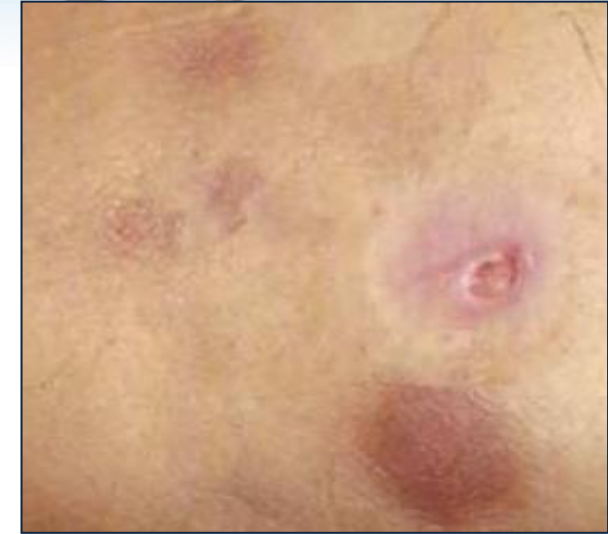Weber-Christian disease

Synonyms:

- ❑ Idiopathic nodular panniculitis;
- ❑ Relapsing Febrile Nodular Nonsuppurative Panniculitis
- ❑ Pfeiffer-Weber-Christian syndrome

Weber-Christian disease (WCD) is a rare disease from the group of diffuse diseases of connective tissue, which is characterized by subcutaneous nodules, inflammatory cells in the fat lobules, and systemic symptoms.

The incidence and prevalence is unknown; for example, a chart review of children and adolescents in Brazil over a 20-year period (1983-2002) found 35 pediatric and adolescent cases of panniculitis, with only 6 cases meeting criteria for Weber-Christian disease.



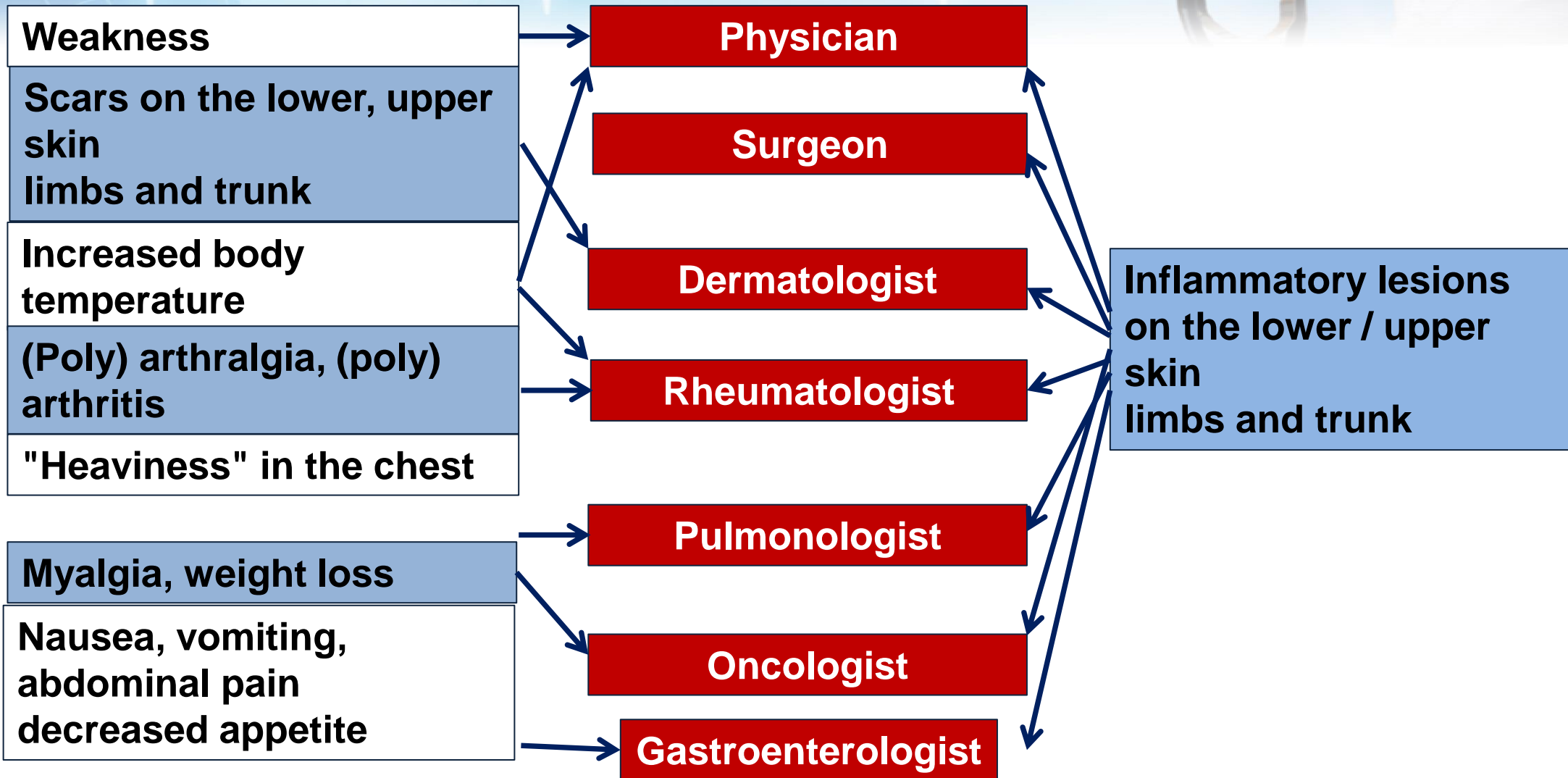
Weber-Christian disease: features

- ❑ Currently there is **no single concept of the etiology and pathogenesis** of this disease.
- ❑ Suggestive is immunopathologic nature of the disease with such provoking factors as injury/surgery, disorders of fat metabolism and endocrine system, liver and pancreas lesions.
- ❑ Weber-Christian disease occurs more often in women, who comprise approximately 75% of reported cases.
- ❑ Polysymptomatic presentation of the disease causes the referral of patients to various specialists before the diagnosis of Weber-Christian disease is made.
- ❑ There are **no uniform international diagnostic criteria** for Weber-Christian disease
- ❑ There is **no specific treatment** for Weber-Christian disease

Weber-Christian disease: complaints

- ❑ Patients with WCD present with cutaneous and systemic complaints. It is described as a relatively severe relapsing chronic condition.
- ❑ They describe crops of lesions that appear and resolve during a period of weeks to months. The lesions are often symmetric in distribution; the upper/lower limbs and trunk are most commonly involved. Individual nodules regress over the course of a few weeks.
- ❑ Systemic lesions in WCD may involve the lungs, heart, intestines, spleen, kidney, adrenal glands, and even orbits.
- ❑ Systemic symptoms of Weber-Christian disease most commonly include fever, malaise, nausea, vomiting, abdominal pain, weight loss, bone pain, myalgia, and arthralgia.

Referral to various specialists in WCD



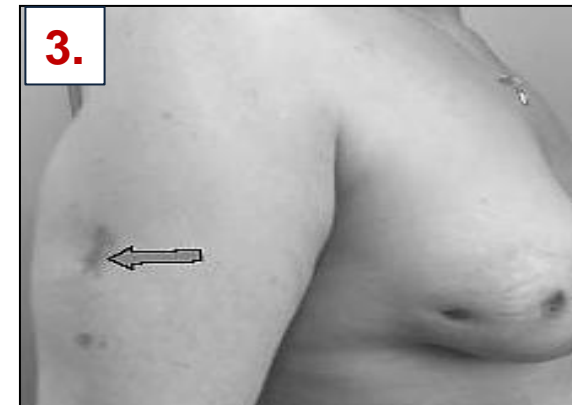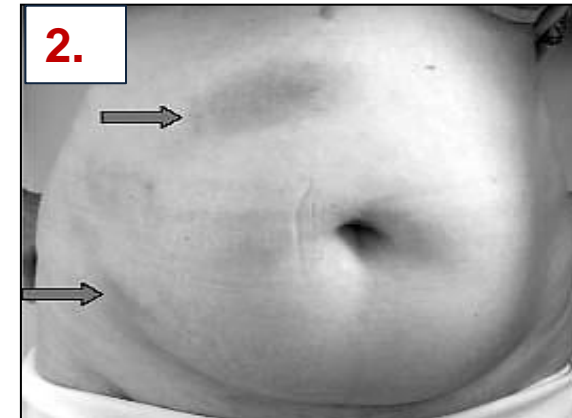
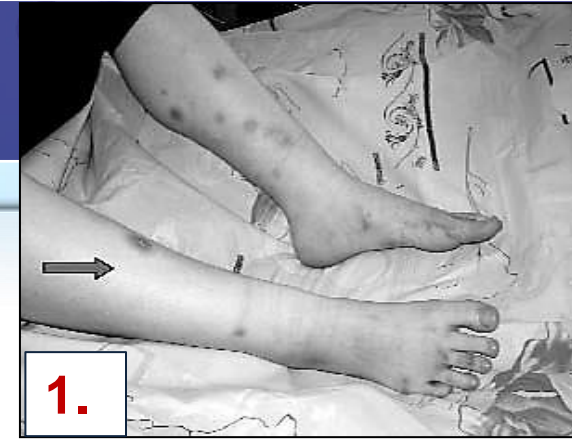
Local manifestations of WCD

- ❑ **Weber-Christian disease is most commonly characterized by erythematous, edematous, and tender subcutaneous nodules. The nodules are usually symmetric and measure approximately 1-2 cm; however, nodules may be much larger. The lesions commonly occur on the thighs and lower legs, and may also involve the arms, trunk, and face.**
- ❑ **Individual nodules usually resolve over a 2-week period, leaving an atrophic depressed scar.**
- ❑ **Occasionally, the epidermis overlying the nodules breaks down, and the lesion discharges a yellow or brown liquid oil. Such patients are often misdiagnosed with “abscess” or “phlegmon”, but the content discharging from the lesions appears to be nonpurulent.**

Local lesions classification

Due to Ukrainian Association of rheumatologists there are 3 main clinical forms of WCD:

1. **Nodular** – lesions are isolated from each other, do not coalesce, clearly demarcated from the surrounding tissue with normal skin color to bright pink color.
2. **Plaque** – nodules are merged in a dense lumpy conglomerate, color over it varies from pink to bluish-purple.
3. **Infiltrative** - characterized by the appearance of fluctuations in the area of separate lesions or conglomerates with red, purple or bluish-purple color.



Treatment of WCD

No uniformly effective therapy for Weber-Christian disease is known.

Due to Ukrainian association of rheumatologists can be used:

- ❑ **Corticosteroids** – prednisolone (methylprednisolone) 20-30mg/day;
- ❑ **DMARDs** - Hydroxychloroquine – 200mg BID.
- ❑ **Nonsteroidal anti-inflammatory agents** may reduce fever, arthralgias, and other signs of malaise.

Nonselective: diclofenac sodium 100-150 mg per day;

Selective:

Meloxicam – 7,5-15mg per day;

Celecoxib – 200 mg 1-2 times per day;

Corticosteroids and NSAIDS can be used topically in ointments.

Antibiotics (macrolides) may be used for the prevention of the infectious complications.

Prognosis of WCD

- ❑ The prognosis for patients with Weber-Christian disease widely varies.
- ❑ In patients with primarily cutaneous manifestations, the clinical course may be characterized by exacerbations and remissions of the cutaneous lesions with minimal systemic complaints for several years before the disorder resolves.
- ❑ Patients with severe visceral inflammation of the heart, lungs, intestines, spleen, kidney, or adrenal glands may not survive.

Our patient

- ❑ **Name: B.G.M.**
- ❑ **Sex: Female**
- ❑ **Age: 57 Years**
- ❑ **Location: Kharkiv**
- ❑ **Occupation: Not working**

Complaints

- ❑ The patient complains of a burning sensation and tightness of the skin in the area of the anterior abdominal wall, loin, hips; pain in the cervical, thoracic, lumbar regions of spine, joints of wrists, feet, knees with the mechanical rhythm of pain and morning stiffness for about 15 minutes, “crepitus” in the joints during movement and restriction of its motion; torso muscle pain.
- ❑ Also complains of recurrent headaches of diffuse nature, dizziness, fatigue, general weakness, periodical chest pain without irradiation provoked by stress, relieved in rest.
- ❑ Patients is concerned about progressive memory loss, periodical chills, feeling of a lump in the throat, difficulty in swallowing.

Anamnesis of present illness

From early childhood, the patient has acquired skin defects (extensive scarring), presumably due to past infectious lesions of the skin in the early neonatal period (in the age of 4 days). **In 2008 after surgery for uterine leiomyoma, the patient began to notice the appearance of a feeling of skin tightness in the area of these lesions, muscle aches, joint pain, aching, diffuse abdominal pain, periodical increase of temperature up to 37, 2C.** However, since 2012 the patient's condition began to deteriorate progressively - the feeling of skin tightness has intensified, **appeared painful nodules with bluish-purple staining of the skin with fluctuation over it in the area of the front wall of the abdomen, loin, hips;** memory worsened significantly, appeared pain in the area of thyroid gland projection, dizziness. The patient referred to the endocrinologist, neurologist, dermatologist and was sent for consultation to the genetic center, where **Werner syndrome** was suspected.

In 2013, she was consulted by rheumatologist and directed to the rheumatology department of Kharkiv City Hospital №28, where she was diagnosed with primary recurrent spontaneous nonsuppurative panniculitis (**Weber-Christian disease**); **she was treated with corticosteroids and NSAIDs with positive dynamics of her state – decreased temperature, diminished pain and skin changes.** Subsequently, the patient is held annually examinations and treatment in a specialized rheumatology department.

Anamnesis of life

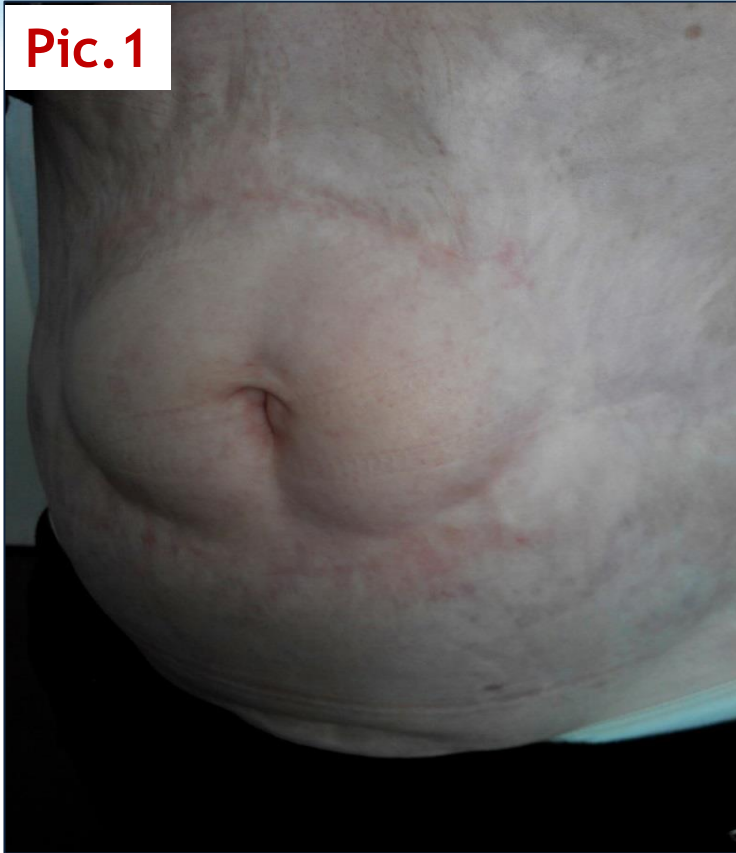- ❑ Patient is not working ,denies smoking, alcohol abuse;
- ❑ Menopause since 2008 (surgical menopause - hysterectomy, ovariectomy);
- ❑ According to the patient 30 yrs ago she was first diagnosed with autoimmune thyroiditis, hypothyroidism; constantly takes L-thyroxin (75-100mg)
- ❑ First was diagnosed with high blood pressure 7 years ago, constantly takes antihypertensive drugs (lisinopril);
- ❑ 16.Jul.2015- ischemic stroke in the basin of the left middle cerebral artery with right-sided hemiparesis – inpatient treatment (IT)– hospital #4.
- ❑ Apr 2016 –inpatient treatment with open-angle glaucoma 1a st, retinal angiopathy of both eyes of hypertensive type;
- ❑ June 2016 – surgery – inflamed right upper jaw granulomas in the area of 14,16, 17 teeth

Objective status

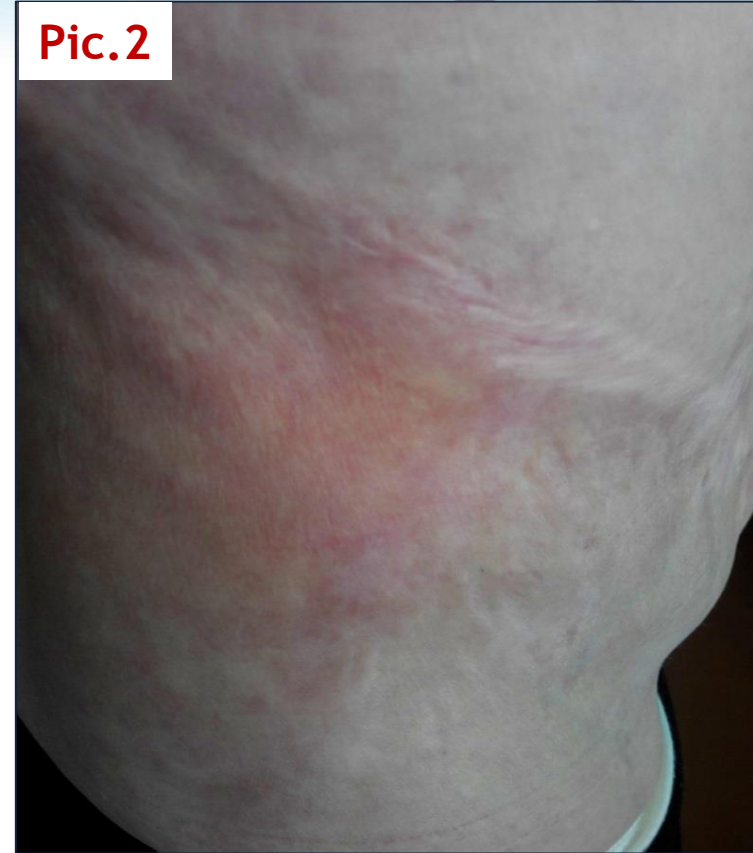- Height - 162cm, weight - 76 kg, **BMI = 29kg / m2**
- Skin: **pale with areas of vitiligo**; slightly dry, skin turgor preserved; on the front of the abdominal wall - **skin atrophy with elements of scarring and slight cyanosis**; in the right thigh - **skin scarring with purple-bluish coloration, slightly painful on palpation**.
- Visible mucous membranes are clean, moist; subcutaneous adipose tissue is developed moderately, distributed symmetrically.
- Musculo-skeletal system: **the outline of small joints of the hands, wrist, knee, ankle, foot joints is smoothed**. There are solitary Heberden nodes in the DIP and Bouchard nodes in the PIP of the hands; in the 1st MTP joints of the feet – signs of exostosis. On palpation joints are painless, with **crepitus on motion**.
- Thyroid gland is not enlarged;
- Lungs: resonance percussion sound, vesicular breathing over the lungs fields, RR-19'
- Heart borders extended to the left on 1 cm, heart tones are rhythmic, clear with HR 72 bpm. **BP sin 160/100 mm Hg, dext 160/102 mm Hg**, radial pulse is synchronous, rhythmic at 72 bpm.
- Abdomen: abdomen is painless on superficial and deep palpation in all regions. Liver at the costal margin, painless; spleen is not palpable. Pasternatskiy sign is negative on both sides. Urination is free, painless.

Objective status

Pic.1



Pic.2



- Pic 1.** On the front of the abdominal wall - skin atrophy with elements of scarring and slight cyanosis;
- Pic 2.** On the loin - skin scarring with purple-bluish color, slightly painful on palpation.

Plan of survey

- ☐ Full blood count, urinalysis
- ☐ Biochemical panel
- ☐ Serology
- ☐ Chest X-ray, X-ray of wrists, feet, MRI of spine
- ☐ Biopsy of skin – patient refused to do biopsy
- ☐ Densitometry
- ☐ Thyroid function tests
- ☐ Ultrasound of thyroid gland
- ☐ ECG
- ☐ EchoCG

Full blood count

Options	Results	Normal range
Hemoglobin, g/L	143	130,0 – 160,0
Erythrocytes $\times 10^{12}/l$	4,56	3,7-4,7
Color index	0,94	0,85 - 1,15
Leukocytes $\times 10^9/L$	9,5	4,0 - 9,0
ESR, mm/h	20	2-15
Stab neutrophils, %	2	1-6
Segmented neutrophils, %	61	47-72
Eosinophils, %	7	0,5-5,0
Basophils, %	0	1-1,0
Lymphocytes, %	32	19-37
Monocytes, %	4	3-11

Conclusion: leucocytosis, increased ESR, eosinophilia

Urine analysis

Options	Results	Normal range
Specific gravity	1,013	1,001-1,040
pH	6,0	5,0-7,0
Protein, g / l	Not detected	to 0.033
Glucose	Not detected	absent
Leucocytes, cells/hpf	1-3	6-8
Epithelium, cells/hpf	1-2	≤15-20
Bacteria	Not detected	absent

Conclusion: all parameters within the normal range

Biochemical panel – lipid profile

Options	Results	Normal range
Total cholesterol, mmol/l	4,16	3,0-5,2
Very low-density lipoprotein cholesterol (VLDL-C), mmol/l	0,31	<0,88
Low-density lipoprotein cholesterol (LDL-C)), mmol/l	2,57	<3,5
High-density lipoprotein cholesterol (HDL-C)), mmol/l	1,28	>0,9
Triglycerides), mmol/l	0,69	<1,95
Atherogenic coefficient	2,25	<3,0

Conclusion: all parameters within the normal range

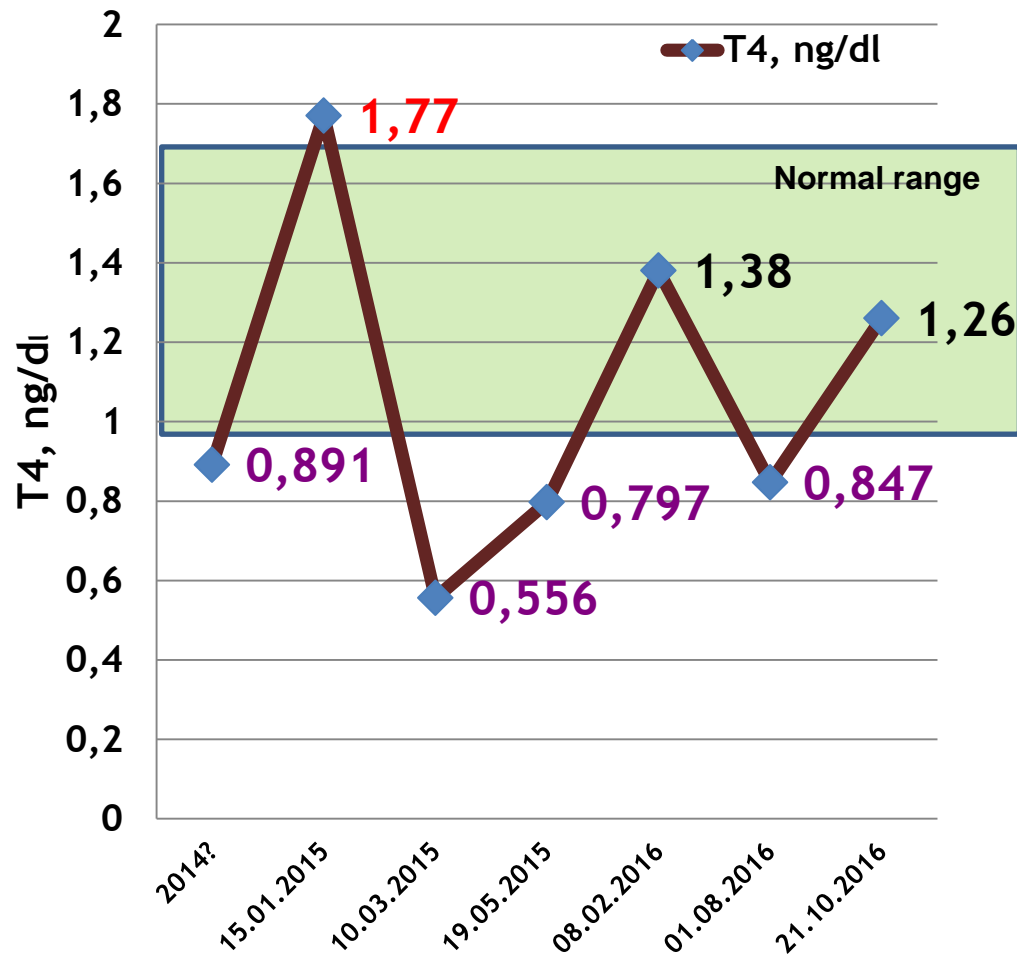
Biochemical panel

Options	Results	Normal range
FPG (fasting plasma glucose), mmol/l	3,6	3,3-5,5
Serum Ca, mmol/l	2,2	2,2-2,5
Ionised Ca, mmol/l	1,0	1,05-1,37
Alkaline phosphatase, U/l	205,0	<240
Serum P, mmol/l	1,0	0,8-1,4
Serum D3, ng/ml	31,319	30,0-100,0
CRP, mg/l	1,01	<5
TSH, mcMe/ml	4,0	0,27-4,2
T4, ng/dl	1,27	0,93-1,7

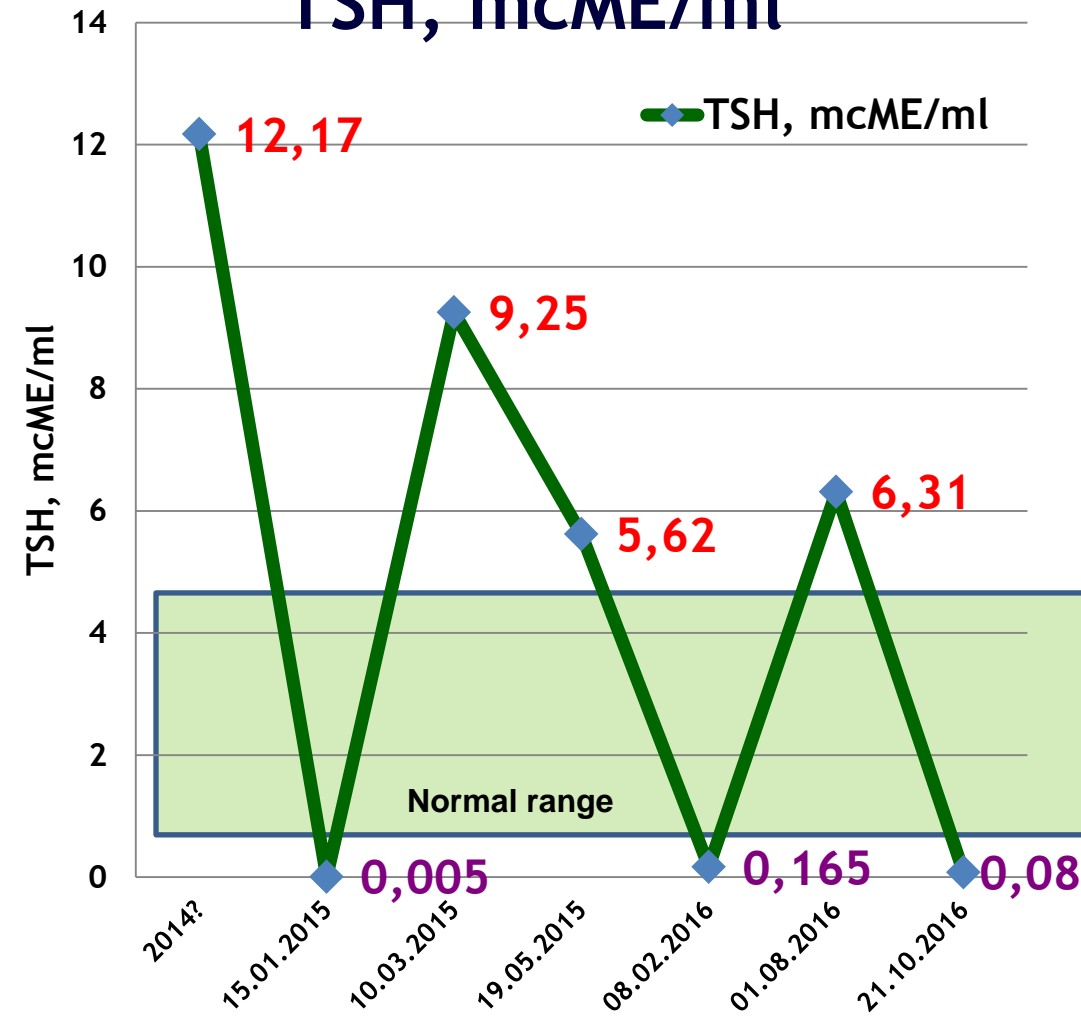
Conclusion: decreased ionised Ca

Dynamic changes of TSH, T4 during 2014-2016 yrs

Dynamic changes of T4, ng/dl



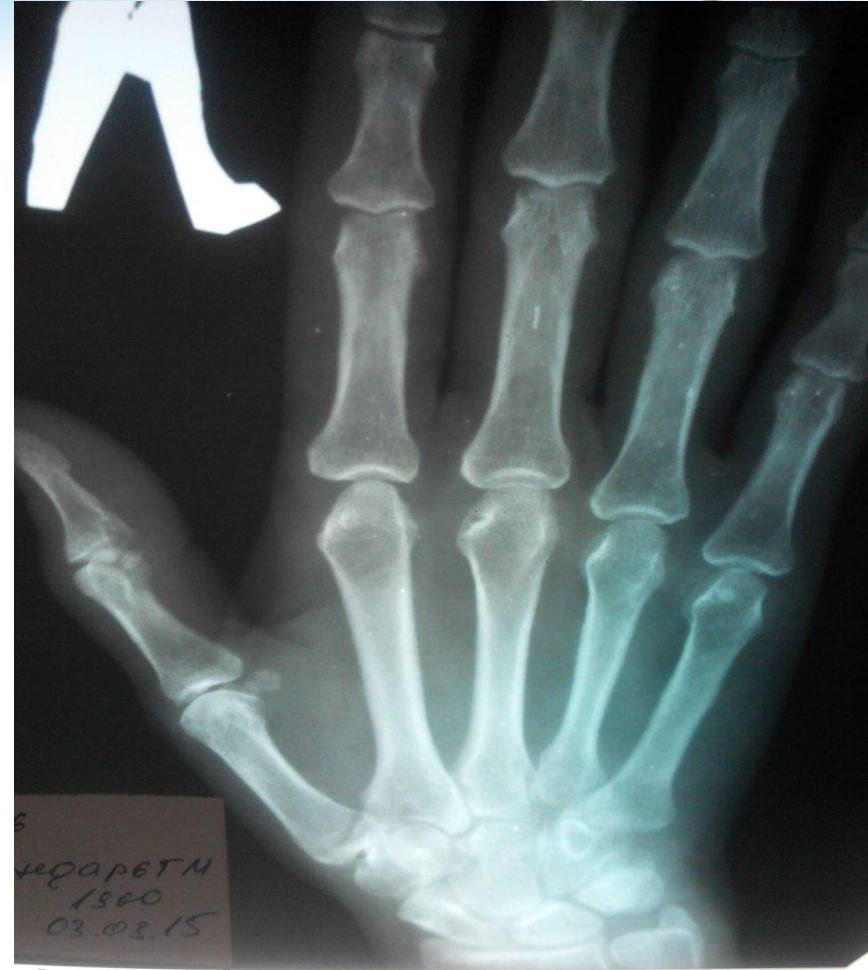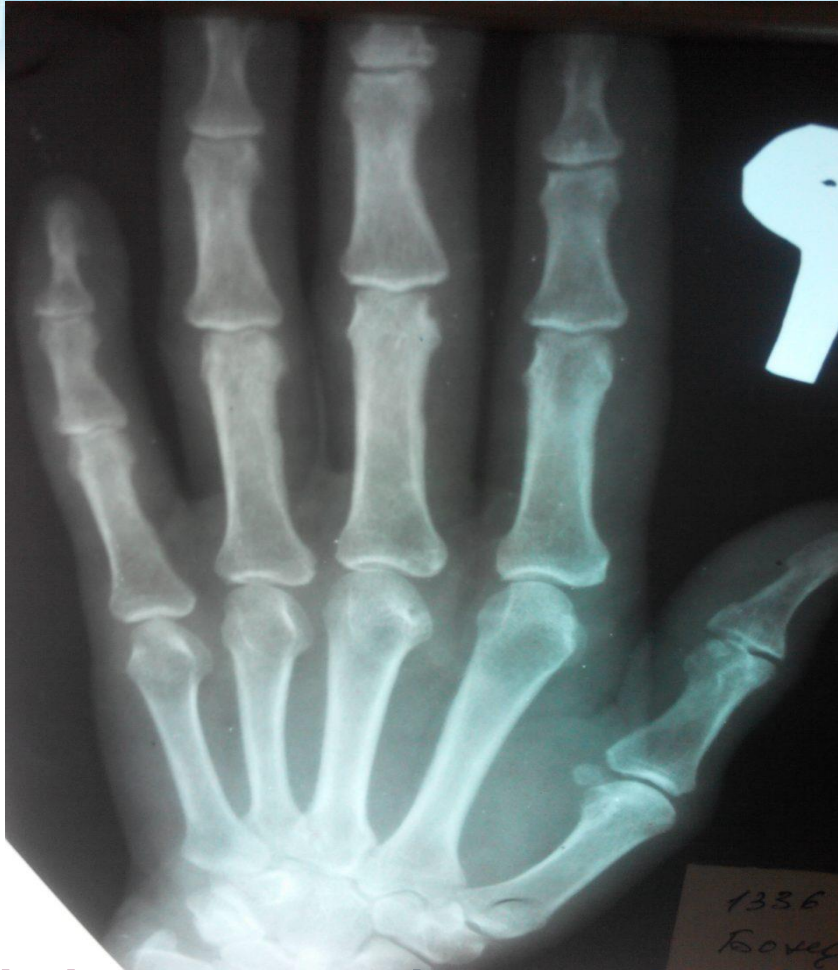Dynamic changes of TSH, mcME/ml



Serological testing

Options	Results	Notes
ANA (Anti-nuclear antibody)	positive	is common in most autoimmune diseases with high sensitivity but lacks specificity; also may be found in nonrheumatic autoimmune diseases, in various infections and malignancies.
RF (Rheumatoid factor)	negative	sensitive, specific for RA (70%), also may be seen in SLE, Sjogren's syndrome, etc. ~15% of the healthy population may have a low titer RF.
anti-ENA (Anti-extractable nuclear antigen)	negative	Consist of the Smith (Sm) antigen (highly specific for SLE), ribonuclear protein (RNP) or U1RNP (SLE plus systemic sclerosis), anti-SSA (Ro) and anti-SSB (La) (Sjögren's syndrome and may be seen in SLE).
anti-dsDNA (Anti-double stranded DNA)	positive 40	highly specific for SLE, however, some patients with other rheumatic diseases or chronic active hepatitis may have mildly or moderately elevated serum titers
anti-JO-1	negative	high specificity to the polymyositis, dermatomyositis
Anti-Chromatin	negative	Renal disease, drug-induced lupus
Anti-Scl70, Anti-Centromere	negative	specificity to systemic sclerosis

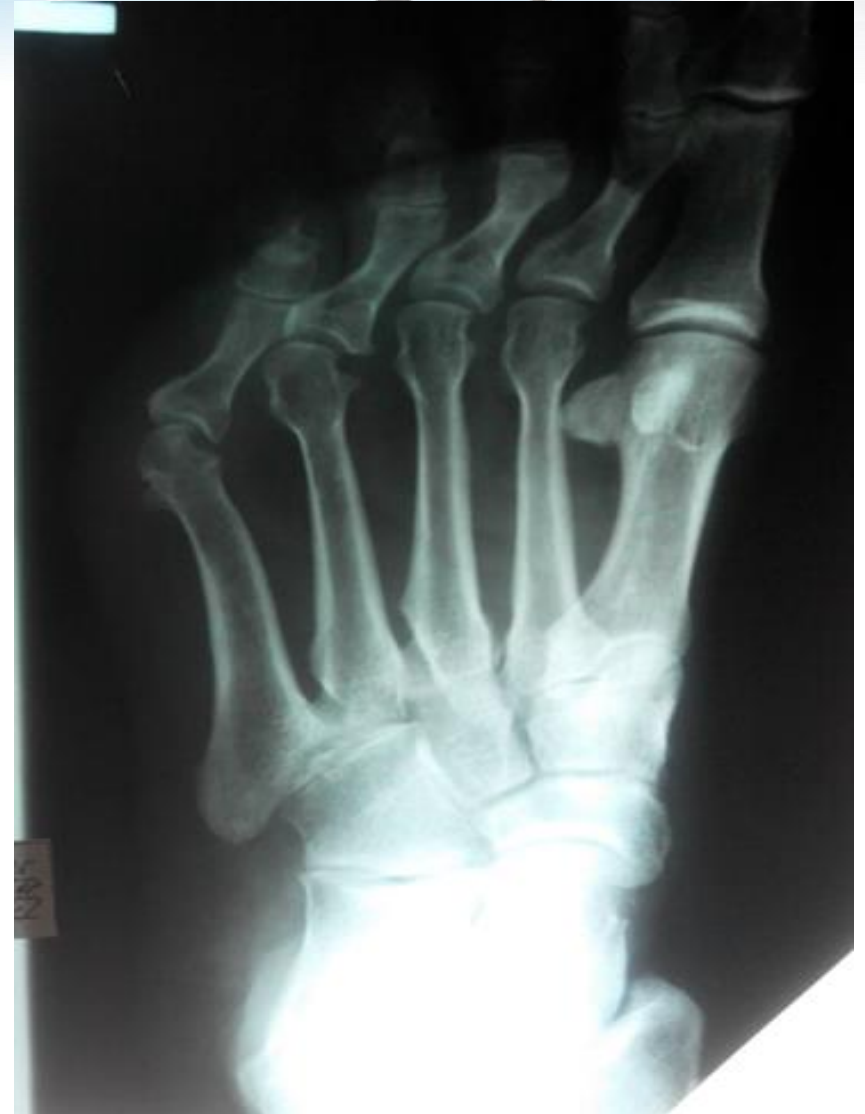X-ray of wrists



Description: assymetric narrowing of the interarticular space; subhondral sclerosis, presence of small (fine) sybchondral cysts, signs of osteoporosis, soft tissue enlargement

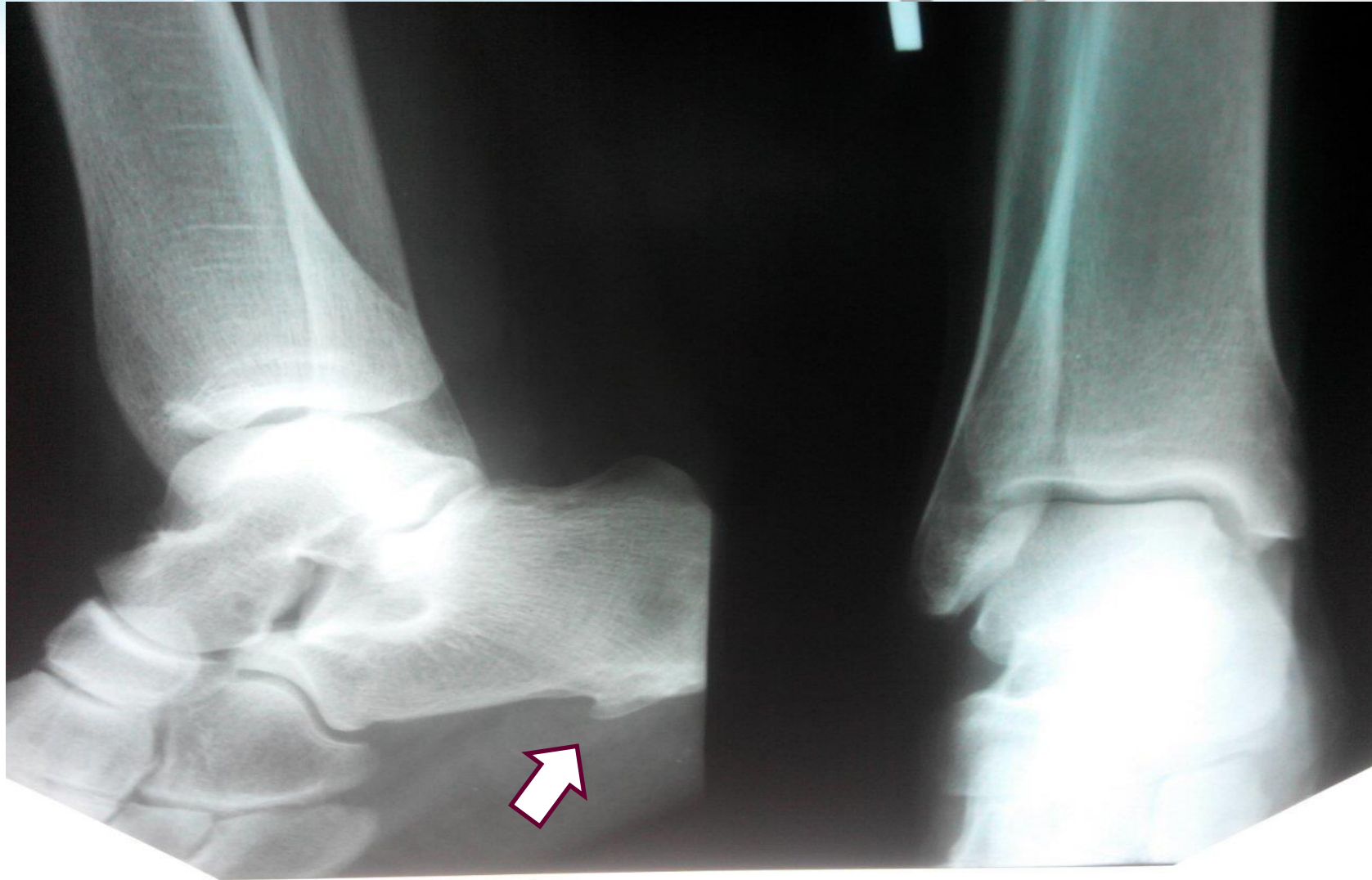X-ray of left foot

Description: assymetric narrowing of the interarticular space; subhondral sclerosis, presence of small (fine) sybchondral cysts, deformity in the area of PIP, DIP joints



X-ray of feet

Description:
assymetric
narrowing of the
interarticular
space;
subhondral
sclerosis,
presence of
osteophytes



Chest X-ray, MRI of spine, densitometry

- ❑ **Chest X-ray**: without pathological changes;
- ❑ **MRI of spine** - polysegmental vertebral osteochondrosis, spondylarthritis, spondylosis, disc protrusions at the level L3-L4, L5-S1.
- ❑ **Densitometry of forearm** – mineral density in distal region is decreased, osteopenia, T-score: – **1,8**;
- ❑ **Densitometry of spine** - mineral density of L1, L2, L3, L4 is decreased – significant osteopenia, total T score: - **2,4**.

Normal mineral density	T-score less than -1,0
Osteopenia	T-score between -1,0 and –2,5
Osteoporosis	T-score is -2,5 and below

Ultrasonography of thyroid gland

- ❑ Right lobe: 20*15*37 mm, volume 5,6 cm³ ;
- ❑ Left lobe: 19*13*36 mm, volume 4,4 cm³;
- ❑ Total volume: 10 cm³;
- ❑ Isthmus: 6 cm³;

Description: The thyroid gland is located low, mobile with irregular precise contours, the capsule is thickened, echogenicity is reduced, heterogeneous structure, lobularity, hyperechoic strands, vascular dilatation is not expressed; in the area of the isthmus on the right asymmetry is determined - area with reduced echogenicity 5 * 7 mm with precise contours, homogeneous structure. Parathyroid glands are normal, peripheral lymph nodes are not visualized.

Conclusion: diffuse-focal pathological changes of thyroid gland

ECG, EchoCG

ECG: sinus rhythm with HR - 74, horizontal position of electric axis of the heart, non-specific ST-T changes in left ventricular posterior wall;

EchoCG

Aorta: aorta and it's leaflets – stiffened, the valve opening of 2.8cm (1,5-2,2 cm);

- ☐ The left ventricle: posterior wall thickness in diastole **1,13** (0,6-1,1 cm), the interventricular septum – **1,12** (0,6-1,1 cm), ejection fraction - 62% (55-65% Teinholz).
- ☐ Mitral valve: opening amplitude -1,9 (1,9-2,8 cm);
- ☐ The diameter of the right ventricle 2,5 (3,0 cm).
- ☐ Anterior-posterior left atrial size 3,3 (4,0 cm)
- ☐ Tricuspid, pulmonary valve without pathological changes

Conclusion: Sclerotic changes in the walls of the aorta, signs of left ventricular hypertrophy.

Diagnostic criteria of WCD

Due to Ukrainian Association of rheumatologists diagnostic criteria for WCD are:

Clinical criteria	The acute (subacute) forming of moderately painful nodes in subcutaneous fat (solitary or conglomerates), mainly in the area of the torso, thighs, forearms.
	High or low-grade fever preceding the appearance of nodules
	Polyarthralgias
Laboratory criteria	Increased ESR, leucocytosis, eosinophilia
Histological criteria	Edema, foci of necrosis of fat lobules
	Cell infiltration with lymphocytes, plasma cells, histiocytes

Course of disease: acute, subacute, chronic;

Activity: 0 (absent), 1 (minimal), 2 (moderate), 3 (high).

Diagnosis of the patient

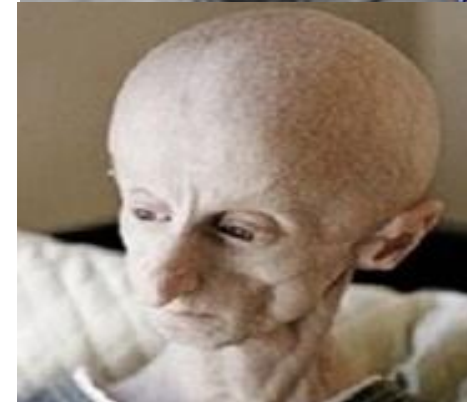- ❑ **Main:** Recurrent lobular nonsuppurative panniculitis (Weber-Christian disease), chronic course, activity of 1 st., with primary subcutaneous fat tissue lesion (infiltrative form). Primary polyosteoarthritis with lesions of small joints of wrists, wrist, ankle, knee, small joints of the feet. Spondyloarthritis. Insufficiency of the joint function I degree, Ro I. Osteopenia.
- ❑ *No conclusive data indicating the presence of Werner syndrome in our patient.*
- ❑ **Concomitant diagnosis:** Osteochondrosis with a lesion of the lumbo-sacral spine. Polysegmental unstable form. Instability of the vertebral-motor segments of L3-L4, L4-L5, L5-S1, herniated intervertebral disks of L4-L5, L5-S1.
Chronic autoimmune thyroiditis, diffuse-nodular form. Hypothyroidism, severe form, compensatory stage.
Arterial hypertension stage III (ischemic stroke 2015), grade 2. Retinal angiopathy of both eyes of hypertensive type, open-angle glaucoma of both eyes 1a degree.
Ischemic heart disease. Atherosclerotic cardiosclerosis.
CHF, stage IIa, with preserved left ventricular pump function (EF- 62%), III FC (NYHA).
CV Risk 4.

Werner syndrome

- ❑ WS (progeria of adults) is autosomal-recessive disease caused by the mutations at the *WRN* gene locus on chromosome 8;
- ❑ Symptoms typically start in the 20s. They include loss and graying of hair, hoarse high-pitched voice, and scleroderma-like skin changes, followed by bilateral ocular cataracts, type 2 diabetes mellitus, skin ulcers, hypogonadism, and osteoporosis in the 30s.
- ❑ A characteristic facial appearance, termed "bird-like" because of the pinched appearance at the bridge of the nose, evolves during the third or fourth decade.
- ❑ Patients usually have low weight.

Skin findings are as follows:

- ❑ Wrinkling and aging of the face, a scleroderma-like appearance with nose and lip atrophy, loss of subcutaneous fat complicated with deep, chronic ulcers around the ankles (highly characteristic), calluses, hyperkeratosis, and ulcerations on the soles present mainly over bony prominences, skin atrophy.



Criteria for the diagnosis of Werner s-me

Criteria by International Registry of Werner's syndrome group:

4 cardinal signs:

- ☐ Bilateral ocular cataracts (present in 99%)
- ☐ **Premature graying and/or thinning of scalp hair** (100%)
- ☐ Characteristic dermatologic pathology (96%)
- ☐ Short stature less than 160cm (95%)

Additional signs and symptoms:

- ☐ Thin limbs (present in 98%)
- ☐ Pinched facial features (96%)
- ☐ **Osteoporosis** (91%)
- ☐ Voice change (89%)
- ☐ Hypogonadism (80%)
- ☐ Type 2 diabetes mellitus (71%)
- ☐ Soft tissue calcification (67%)
- ☐ Neoplasm(s) (44%)
- ☐ **Atherosclerosis** (30%)

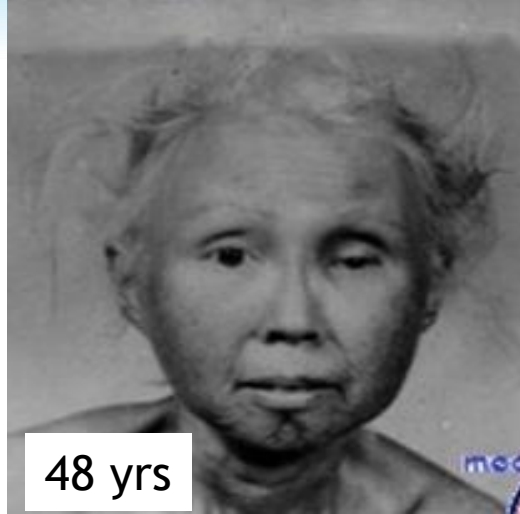- **Definite WS:** four cardinal signs and two additional signs;
- **Probable WS:** the first three cardinal signs and two additional signs;
- **Possible WS:** Either cataracts or dermatologic alterations and four additional signs;

Identification of biallelic *WRN* pathogenic variants on molecular genetic testing confirms the diagnosis if clinical features are inconclusive.

Werner syndrome?



15 yrs



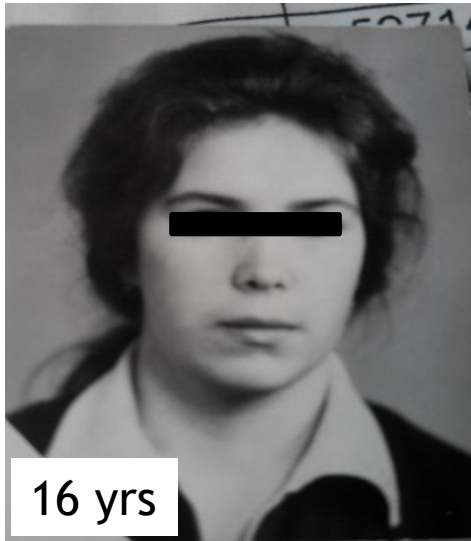48 yrs



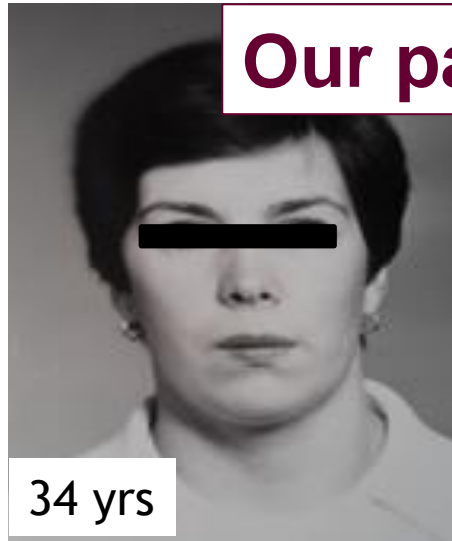
13 yrs



56 yrs

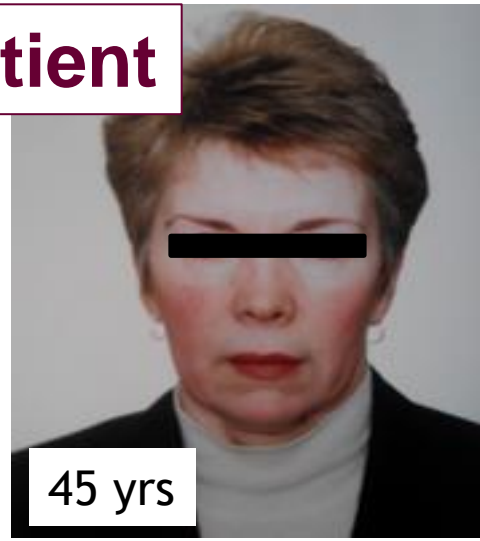


16 yrs

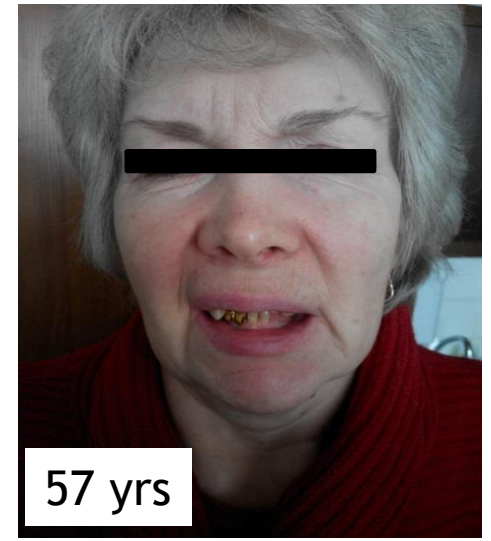

34 yrs

Our patient



45 yrs



57 yrs

Treatment and recommendations

- ❑ Recommendations to maintain healthy lifestyle, decrease sodium intake, lipid lowering diet, aerobic non strenuous exercises;
- ❑ Meloxicam 15mg per day - 10 days, and in the subsequent course of no more than 10 days in the event of pain
- ❑ Hydroxychloroquine (plakvinil) 0.2 g 2 time per day for a long time
- ❑ Glucosamine sulfate 1500mg per day for 3 months, after 6 months a second course may be given.
- ❑ Osteogenon (combined formulation with calcium and phosphorus) 2 tab twice daily for 6 months under the control of serum calcium and phosphorus
- ❑ Zolopent (pantoprazole), 40 mg once daily for 7 days
- ❑ L-thyroxin 100mg per day under control of thyroid hormones;
- ❑ Bisoprolol 5mg in the morning, lisinopril 10mg in the evening under blood pressure control;
- ❑ Aspirin 75mg once daily continuously;
- ❑ Repeat densitometry after 6 months, autoantibodies after 3 months;
- ❑ Repeat visit to rheumatologist, endocrinologist, neurologist after 3 months.

Conclusion

- ❑ Weber-Christian disease in our patient developed on the background of long course autoimmune thyroiditis with impaired function of the thyroid gland (hypothyroidism) and unstable hormonal status, after surgery (hysterectomy, ovariectomy) that exacerbated hormonal imbalance.
- ❑ Diagnosis of the disease Weber-Christian was made a few years after the onset of symptoms, which is due not only to the late referral of the patient for medical assistance, but also the weak medical vigilance in relation to rare diseases.
- ❑ This clinical case is an illustration of the fact that the key factors for the early diagnosis of rare diseases are a careful history taking, attentive and accurate approach to the patient, as well as a systematic analysis of laboratory and instrumental surveys.

Thank you for attention!



Questions?