


V. N. Karazin Kharkiv National University
Department Of Internal Medicine

ATRIAL FIBRILLATION AS A CONSEQUENCE
OF AN ATRIAL SEPTAL DEFECT

Performed:

Student of Vth course, gr. 522 Ali Fadel Al Mahafzah,
ass. prof. Rybchynskyi Stanislav

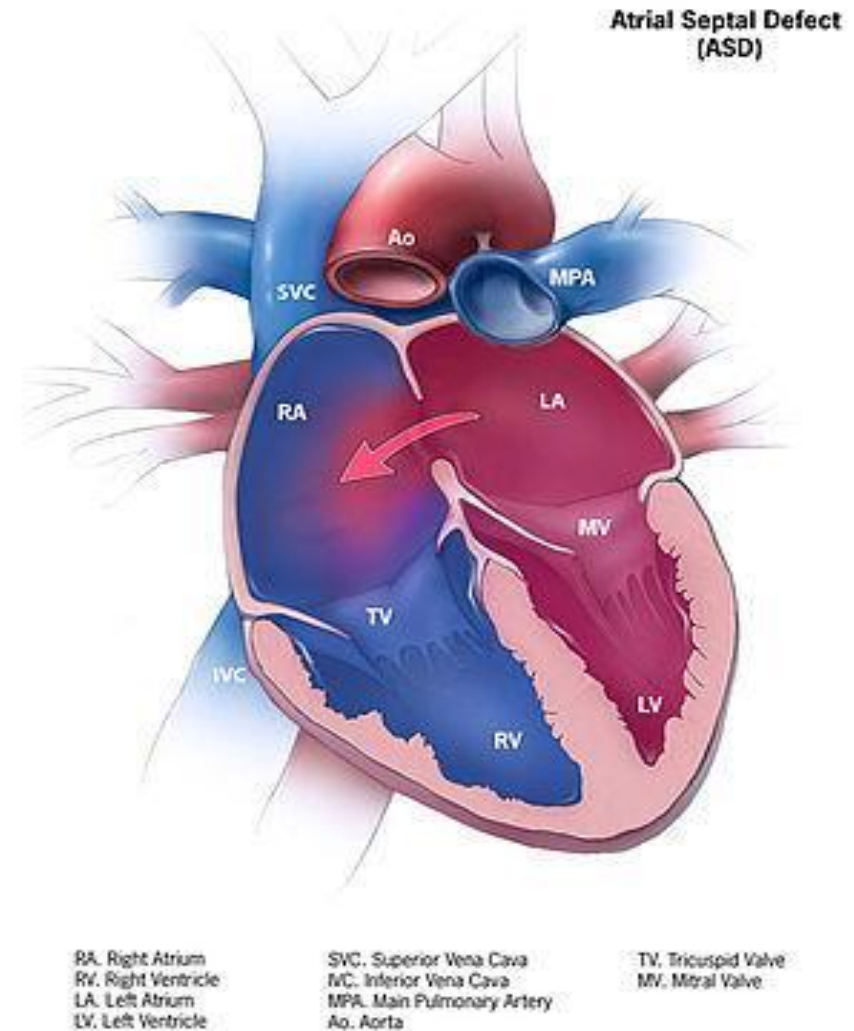


ATRIAL SEPTAL DEFECT (ASD)

What is it?

A "hole" in the wall that separates the top two chambers of the heart. This defect allows oxygen-rich blood to leak into the oxygen-poor blood chambers in the heart. ASD is a defect in the septum between the heart's two upper chambers (atria). The septum is a wall that separates the heart's left and right sides.

http://www.heart.org/HEARTORG/Conditions/CongenitalHeartDefects/AboutCongenitalHeartDefects/Atrial-Septal-Defect-ASD_UCM_307021_Article.jsp#.Wt4dDmG1nvc



THERE ARE FOUR MAJOR TYPES OF ATRIAL SEPTAL DEFECTS :

1. Ostium secundum atrial septal defect.
2. Ostium primum atrial septal defect.
3. Sinus venosus atrial septal defect.
4. Coronary sinus atrial septal defect.

ETIOLOGY

- Children with ASD:

Every child is born with an opening between the upper heart chambers. It's a normal fetal opening that allows blood to detour away from the lungs before birth. After birth, the opening is no longer needed and usually closes or becomes very small within several weeks or months.

Sometimes the opening is larger than normal and doesn't close after birth. In most children the cause isn't known. Some children can have other heart defects along with ASD.

- Adults with ASD:

It just was not diagnosed in Childhood.

PATHOPHYSIOLOGY

ASD affects the hemodynamic of the heart therefore these changes (right atrial and right ventricular volume overload) can lead to:

- Pulmonary artery hypertension, elevated pulmonary vascular resistance, and right ventricular hypertrophy .
- Atrial arrhythmias, such as supraventricular tachycardia (SVT), atrial flutter, or atrial fibrillation may also occur later.

(Ultimately, the increase in the pulmonary artery pressure and vascular resistance may result in a bidirectional atrial shunt with cyanosis during adulthood (Eisenmenger reaction)).

DEFINITION OF ATRIAL FIBRILLATION (AF)

AF is a supraventricular tachyarrhythmia characterized by chaotic electrical activity of the atria, a high heart rate (> 350 bpm) and an irregular rhythm of the ventricles (with no complete AV blockade), with ineffective atrial contractions associated with an increased risk of thromboembolism.

FORMS OF (AF)

CDX code: I48.0 -atrial fibrillation and flutter

- Paroxysmal (the rhythm is restored independently within 7 days).
- Persistent (episode lasting more than 7 days, when it is necessary to intervene to restore the sinus rhythm).
- Long-standing persistent(episode, take a year or more, then it is advisable to restore the sinus rhythm).
- Permanent(when it is impossible to restore the sinus rhythm, or it is impractical).

Bradysystolic (frequency of ventricular contractions less than 60 per minute) **

Tahisystolic (frequency of ventricular contractions more than 110 per minute) **

OUR PATIENT

- Man 69 year old.
- Resident of the city.
- Worker in a battery factory.
- Received in hospital: 22.01.18.

COMPLAINTS

- Palpitations.
- Irregular cardiac activity.
- Headache mainly associated with hypertension (blood pressure destabilization).
- Chest pain (pressing pain) around left rib cage (at changing of body position).
- Dyspnea (shortness of breath during everyday activities).
- Emotional stress.

ANAMNESIS MORBI

- In 2005, the patient was taken to the hospital in the City of Kharkov with the following complaints (dyspnea, fatigue, chest pain, palpitations); the tests showed that the patient suffered from congenital defects and was transferred to the clinic of Kyiv to undergo a Plastic surgery to repair the defect with Cardiopulmonary bypass (CPB) on the 05.10.05 the patient was successfully carried out. Subsequently treated as an outpatient.
- In July 2013, the first atrial fibrillation was recorded. After the examination, a decision has been made on preparing the patient to electrical cardioversion. It was noted for 3 times in the anamnesis;

ANAMNESIS MORBI

- 1st time on the 08.08.13 it was successfully performed to restore sinus rhythm.
- 2nd time was in May 2014, with a regular hospitalization, the atrial fibrillation in the patient was noted again and after the examination it was made a decision to carry out cardioversion in December 2014.
- 3rd time was in January 2015; in the last two times the sinus rhythm was successfully restored.
- However, after 4 months the arrhythmia recurred, the disease was diagnosed and treated (in order to prepare the patient, it was necessary to use the medicine Dabigatran 150 mg for electrical cardioversion).

ANAMNESIS VITAE

1. DM ,TBC and Botkin's disease are denied in the anamnesis.
2. Allergic history negative.
3. Operated for left-sided inguinal hernia.

PHYSICAL EXAMINATION

- State of moderate severity. Active position. The skin is normal. Peripheral lymph nodes are not enlarged.
- The thyroid gland is not clearly defined.
- The musculoskeletal system is without symptoms.
- Percussion above the lungs is a pulmonary sound. Auscultatory breathing is a vesicle, but a weakness has been observed in the lower part of the lung.
- The border of the heart shifted to the left. Irregular cardiac activity, cardiac tones are muffled. Accent II on the aorta.
- Pulse (68), HR (96) in (min), difference between them is 28. BP 140/100(mm Hg).
- The abdomen was soft, painless.
- The liver extends from the edge of the costal arch to 3-4 cm.
- Edema of the lower legs.
- Physiological functions without features.

BLOOD COUNT

Parameters	Result	Normal range
Hemoglobin, g/l	<u>123</u>	130 –160
Red blood cells	<u>3.94</u>	4.0 –5.0
Ht	<u>34.6</u>	40-48%
White blood cells	6.6	4 -9
ESR, mm/h	<u>20</u>	1 -10
Bands	5.13	1.06 –6%
Segments	67.3	47 –72%
Eosinophils	2.3	0.5 –5%
Monocytes	2.6	0.1 –3%
Lymphocytes	20.9	19 –37 %
Platelets	193	180-320

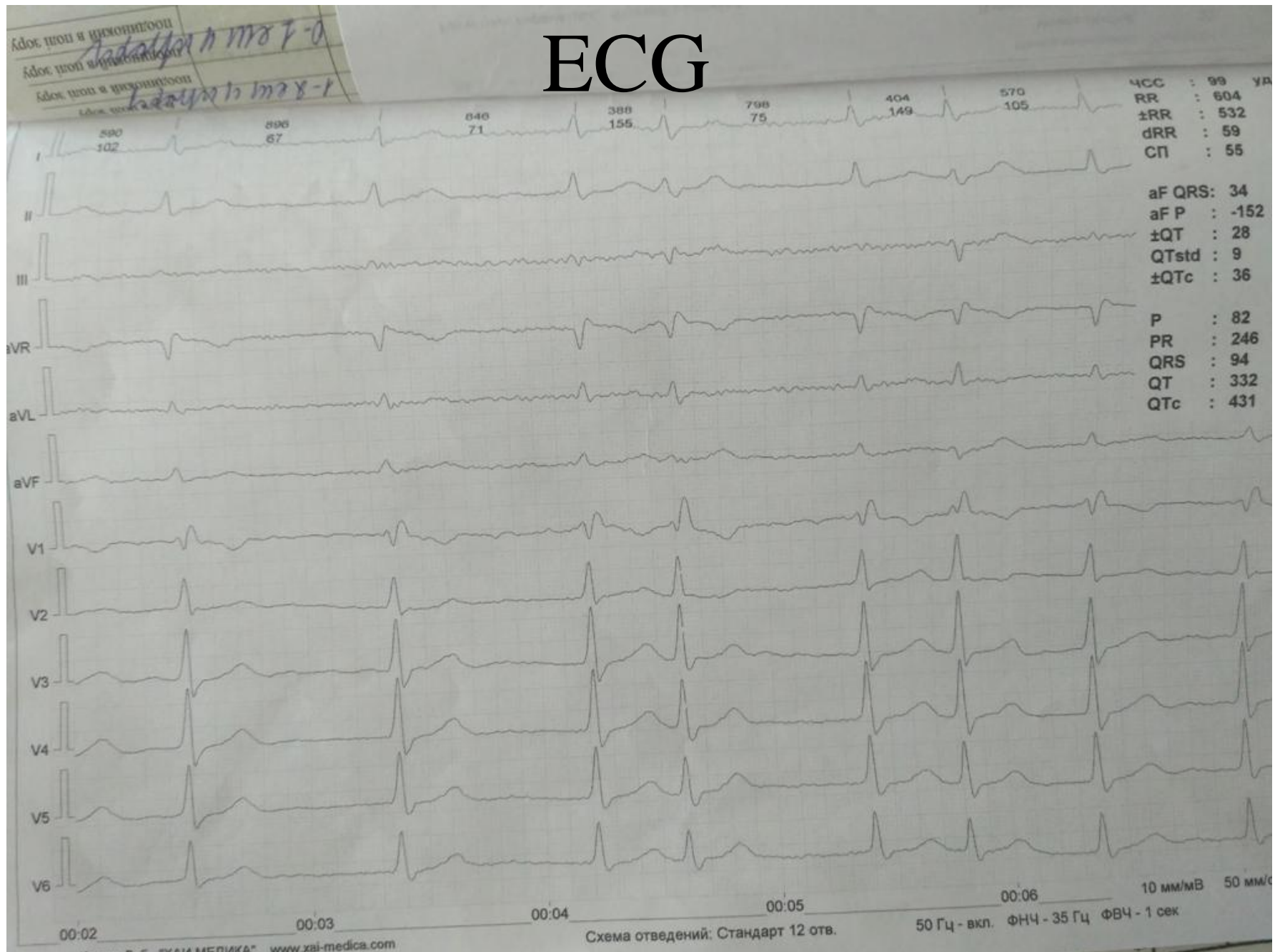
Conclusion: Decreased level of hemoglobin, RBC and Ht. Increased ESR

BIOCHEMISTRY TEST

Parameters	Result	Normal range
Total bilirubin, mkmol/l	18.2	1,7 –21
AST, U/l	18.6	< 37
ALT, U/l	14.5	< 41
Creatinine, mkmol/l	85	82 –106
Glucose, mmol/l	5.3	4.22 –5.5

Conclusion: Normal.

ECG



Conclusion: Atrial fibrillation, HR:96. Deviation from axis to the left. Incomplete blockade of the right leg of the Bundle branch.

ECHOCARDIOGRAPHY

- Sclerotic changes in the walls of the aorta, valves of the aortic and mitral valves.
- Myocardial hypertrophy of the left ventricle by concentric type
- Dilatation of both atrial cavities
- Signs of increasing pressure in the pulmonary artery PH (31 mmHg (WHO Group I))
- Mitral regurgitation of the 1st degree
- Tricuspid regurgitation of the 2nd degree

DIAGNOSIS

Arterial hypertension, II stage, 3 degree. Uncomplicated hypertensive crisis (12.07.17). Hypertensive heart. Congenital heart defect. Atrial septal defect. Plastic of the interatrial septum (05/10/2005). Constant form of atrial fibrillation, (electrical cardioversion 08/08/2013, 10/10/14, 16/01/2015), CHA2DS2-VASc-1 HAS-BLED 3. HF II A-B degree NYHA II FC with preserved systolic function of the left ventricle (EF-73%).

Concomitant anemia.

TREATMENT


The treatment was completed using the following medicines:

- Anticoagulant:
Rivaroxaban 20 mg
- Antiarrhythmic:
Nebivolol 5 mg
- For hypertension:
Valsartan 40 mg, Rosuvastatin 20 mg

As a medical recommendation we advise the patient to change his lifestyle to a healthy one by exercising, no alcohol consuming and no smoking.

DISCUSSION

Unfortunately, this defect was detected after the dilatation of both atrial cavities, but the surgery was able to reduce the risk of atrial septal defect.



THANK YOU FOR YOUR
ATTENTION

