

Approach to the Patient with Disease of the Cardiovascular System

LECTURE IN INTERNAL MEDICINE PROPAEDEUTICS

M. Yabluchansky, L. Bogun, L.Martymianova, O. Bychkova, N. Lysenko, N. Makienko
V.N. Karazin National University Medical School' Internal Medicine Dept.

Plan of the lecture

Approach to the Patient with Disease of the Cardiovascular System

- Interviewing of the patient
- Physical examination of the patient
- Instrumental methods
- laboratory methods

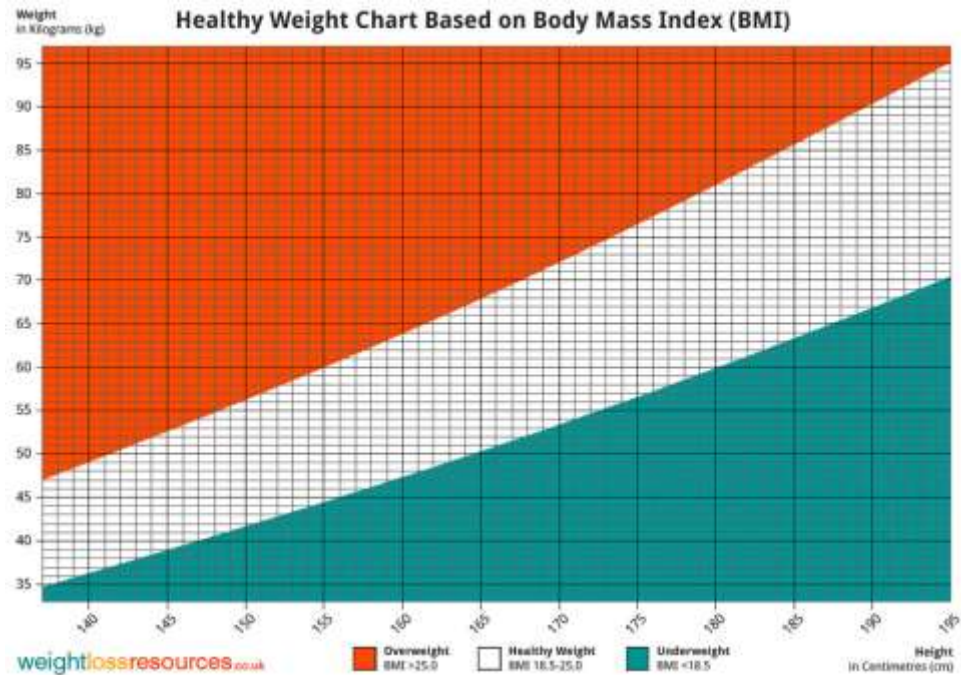
Interviewing of the patient: good questions to get started on the core interview

- What is your chief complaint?
- Tell me why you're here today
- Tell me about your injury
- What can I do to help you?
- Explain to me your understanding of your injury



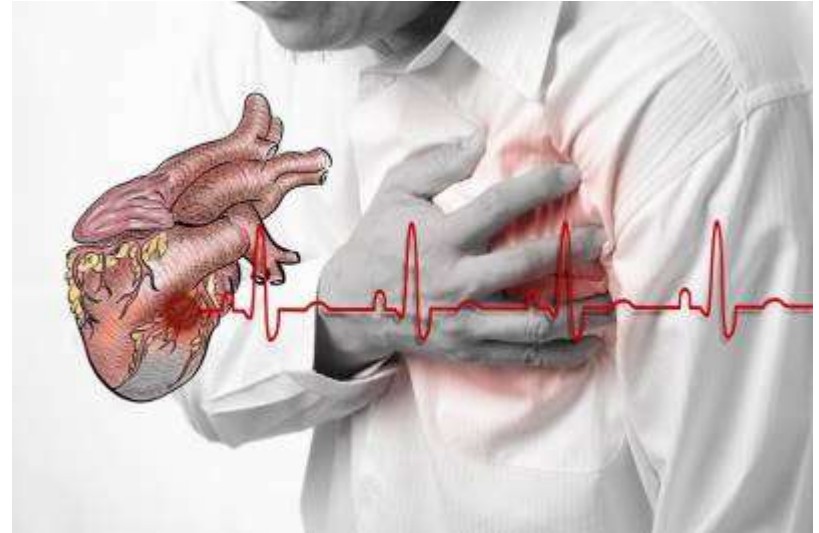Interviewing of the patient: patient profile

- Age
- Sex
- Race/Ethnicity
- Handedness
- Ht-Wt-BMI-Body type
- Primary language
- Barriers to learning
- Learning preference
- Unique rehabilitation goals



Interviewing of the patient: chief complaint

- The medical evaluation of chief complaint of a person with suspected heart disease begins with an interview about the patient's major (chief) complaint
- The process begins from asking specific questions about the complaint
- Very often the patient's chief complaint is the chest pain



Interviewing of the patient: chief complaint

| Pain (Chest) | Cardiac | Pleuritic | Traumatic |
|--|--|--|--|
| D Description: <ul style="list-style-type: none"> Can you describe the pain to me? (You need to determine it's nature.) Is it there all the time? Does it come and go? Have you ever had this pain before? What was it that time? | <ul style="list-style-type: none"> Heavy Tight Squeezing Drill | <ul style="list-style-type: none"> Sharp Catching Stabbing | <ul style="list-style-type: none"> Sharp Catching Stabbing |
| O Onset: <ul style="list-style-type: none"> When did it start? What were you doing at the time? Did it come only suddenly or slowly? | <ul style="list-style-type: none"> Gradual (Angina) Sudden (UA/Infarct) With Exercise (Angina) At Rest (UA/Infarct) | <ul style="list-style-type: none"> Gradual (Infection) Sudden (Pneumothorax) | <ul style="list-style-type: none"> Gradual (post trauma) Sudden (post trauma) |
| L Location: <ul style="list-style-type: none"> Take one finger and point to the pain? "Does it extend anywhere else?" If well localised palpate and visualize | <ul style="list-style-type: none"> Poorly localised Chest to back to jaw Rarely changes with palpation | <ul style="list-style-type: none"> Well localised Usually chest wall Usually changes with palpation / ventilation | <ul style="list-style-type: none"> Well defined Usually chest wall Changes with palpation / ventilation |
| O Other Signs and Symptoms: <ul style="list-style-type: none"> "Do you feel nauseous?" (If yes) "Have you vomited?" "Do you feel SOB?" "Have you noticed palpitations?" "What came first, the discomfort or the (OSs)?" | <ul style="list-style-type: none"> SOB % Diaphoresis % Palpitations % | <ul style="list-style-type: none"> SOB (on exertion) Chest infection (prodromal) | <ul style="list-style-type: none"> SOB (on exertion) |
| R Relief: <ul style="list-style-type: none"> "Have you taken anything for the discomfort?" (If yes) "Has it helped?" "Does it usually?" "Does taking a deep breath make the pain better, worse or no different?" "Does moving make the pain better, worse or no different?" | <ul style="list-style-type: none"> Relieved with Nitrates (Angina) Unrelieved with Nitrates (UA/Infarct) Poor relief with NSAIDS Poor relief with position | <ul style="list-style-type: none"> Unrelieved with Nitrates Mild relief with NSAIDS Some relief with position | <ul style="list-style-type: none"> Unrelieved with Nitrates Mild relief with NSAIDS Some relief with position |

Types of chest pain

Interviewing of the patient: other chief complaints

- Shortness of breath
- Dizziness
- Blackout spells
- Palpitations (a sensation of skipped, forceful, or fast heartbeats)
- Weakness
- swelling of the legs
- etc.



Interviewing of the patient: specific questions for set of chief complaints

Each of chief complaints will prompt a series of specific questions that will help arrive at a preliminary single diagnosis, or a group of different diagnoses



Interviewing of the patient: example of specific questions in chief complaint' chest pain

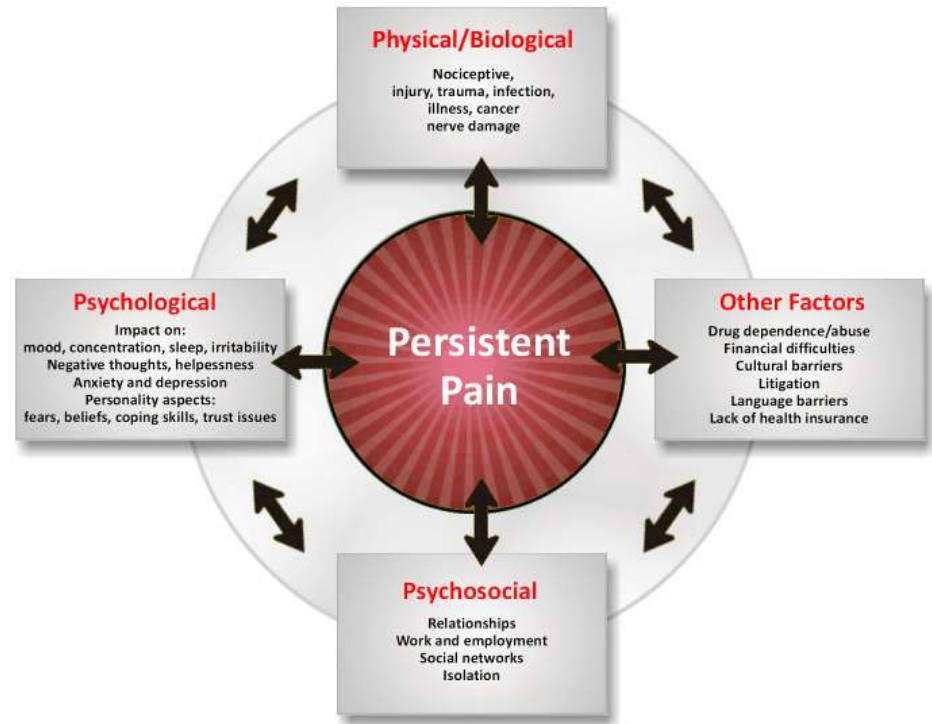
- Character
- Location
- Severity
- Timing
- Duration
- Radiation (shoulder, arms, jaw, back or other parts of the body)
- Provocation
- Relieving conditions
- When did it first start?
- How often does it occur?
- What brought it on?
- Were there associated symptoms (shortness of breath, sweating, dizziness, weakness, nausea, vomiting, etc.)?
- Is it becoming more frequent with time?
- Are the symptoms lasting longer?
- Do they appear at rest or has it awakened the patient from a sound sleep?

Interviewing of the patient: quality of chest pain

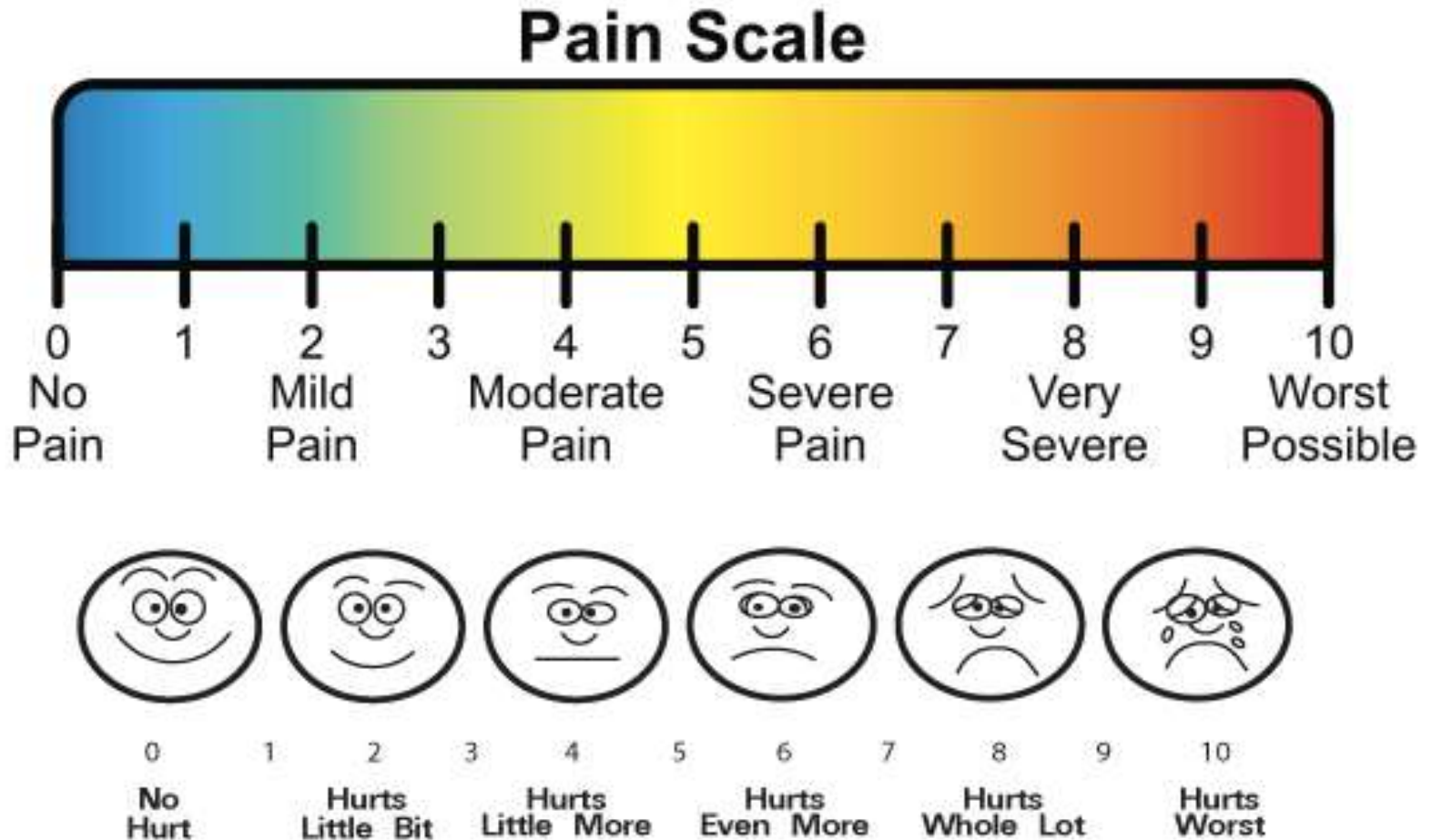
- Squeezing - A band-like sensation is felt around the chest
- Tightness - There is a sensation of a knot being present in the center of the chest
- Pressure - A sensation of a lump in throat or a heavy weight on the chest
- Chest Constriction - The “Levine sign” is displayed by a patient suffering from chest pain caused by a myocardial infarction
- The patient typically presses a clenched fist against the chest to illustrate the sensation of pressure and constriction in the chest
- Burning - Infarction pain is often mistaken for heartburn or indigestion, especially in women.

Interviewing of the patient: factors that influence pain

- Physical stress
- Cold
- Emotional stress
- Sexual intercourse
- Smoking
- Meals
- Sleeping problems



Interviewing of the patient: Visual Analog and Numerical Pain Rating Scales



Interviewing of the patient: list of possible complaints

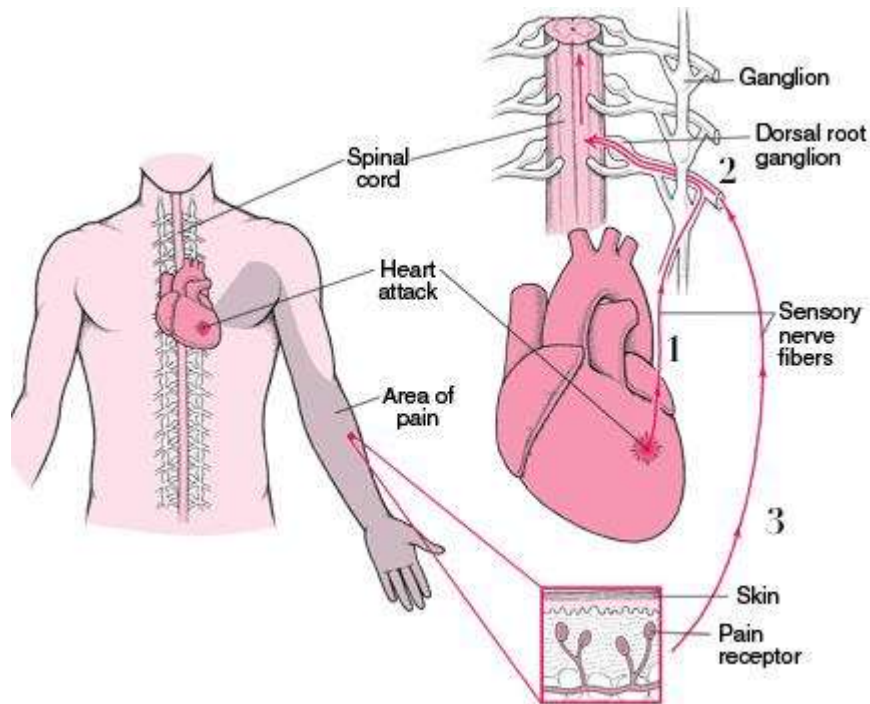
More specific

- Pain in the heart region
- Palpitation
- Dyspnea
- Cardiac asthma
- Cough
- Hemoptysis
- Edema
- Syncope
- Irritability
- Numbness/tingling
- Skin changes
- Leg swelling

More nonspecific

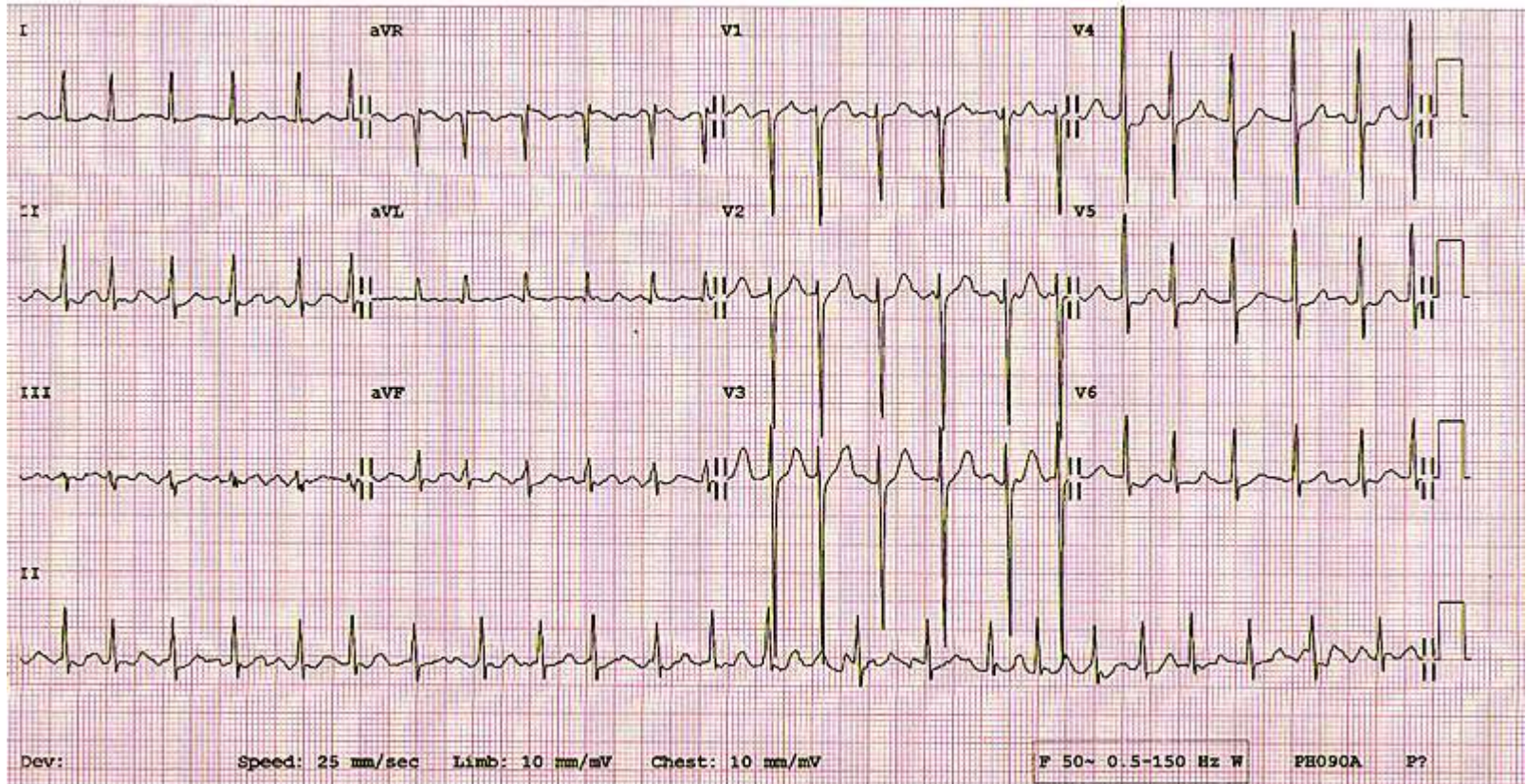
- Fever
- Sweatiness
- Weight loss
- Fatigue
- Headache
- Dizziness
- Sleeplessness
- Deranged vision and hearing
- Voice changes
- Dysphagia
- Dyspepsia
- Thirst
- Pain in the abdomen
- Pain in the joints

Interviewing of the patient: pain in the heart region



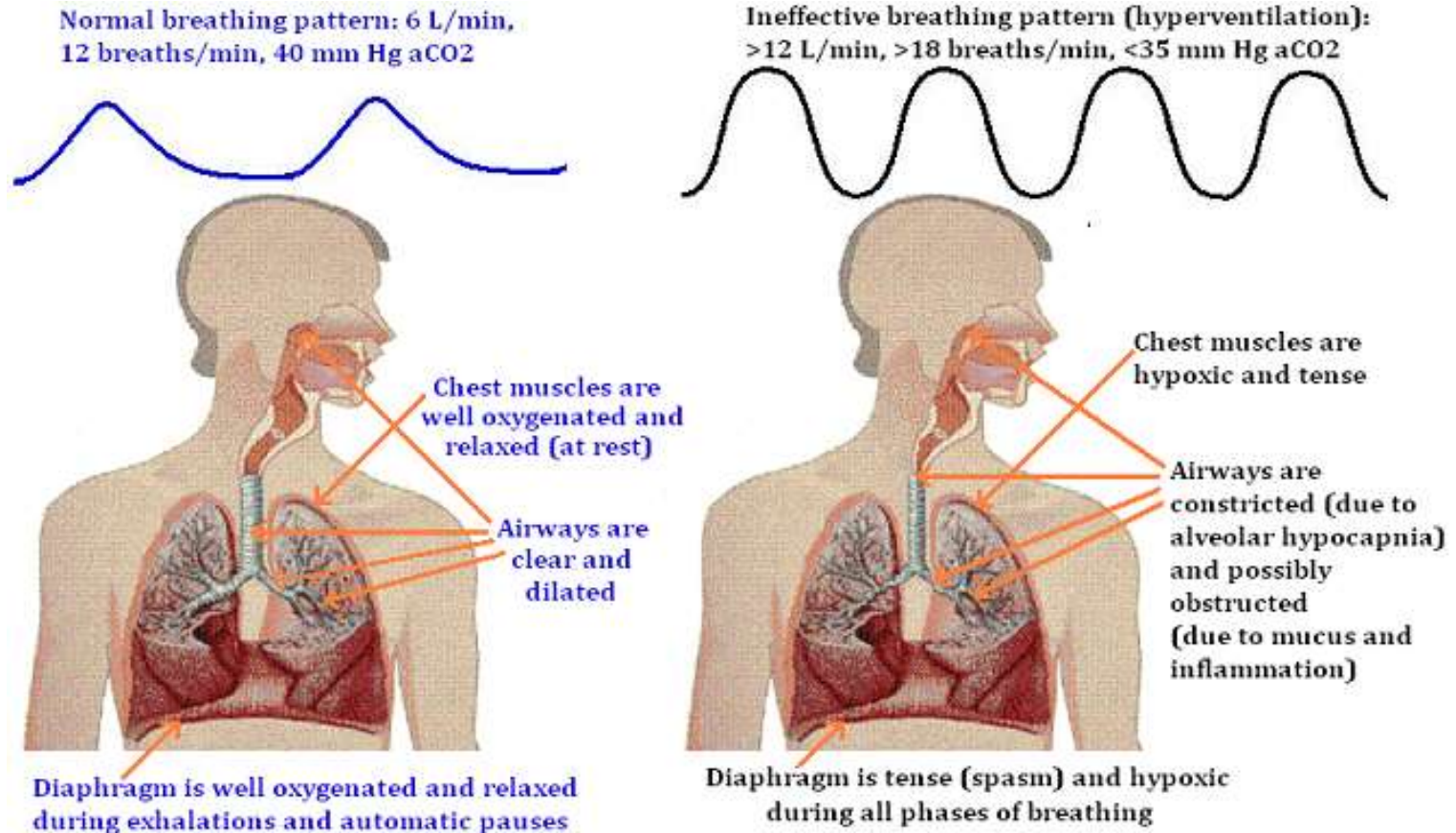
Pain or discomfort that occurs in an area of heart muscle

Interviewing of the patient: palpitation




The feelings of having rapid, fluttering or pounding heart.

Interviewing of the patient: dyspnea



The sensation of difficult or uncomfortable breathing

Interviewing of the patient: dyspnea



Wheezing, coughing or shortness of breath due to congestive heart failure

Interviewing of the patient: cardiac asthma



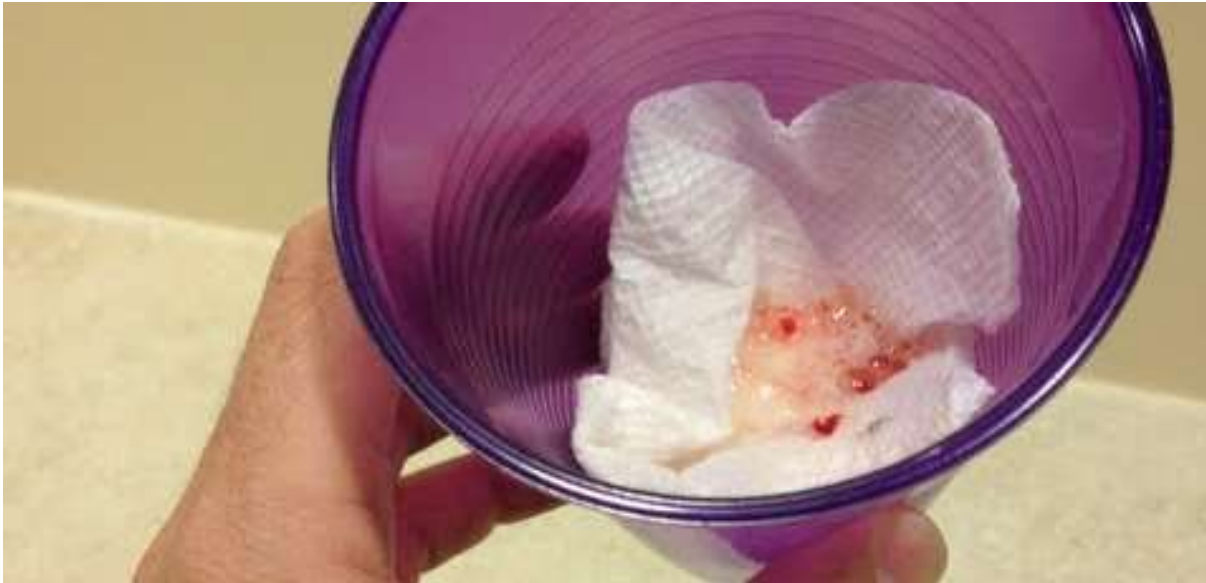Breathing difficulty associated with congestive heart failure

Interviewing of the patient: cough



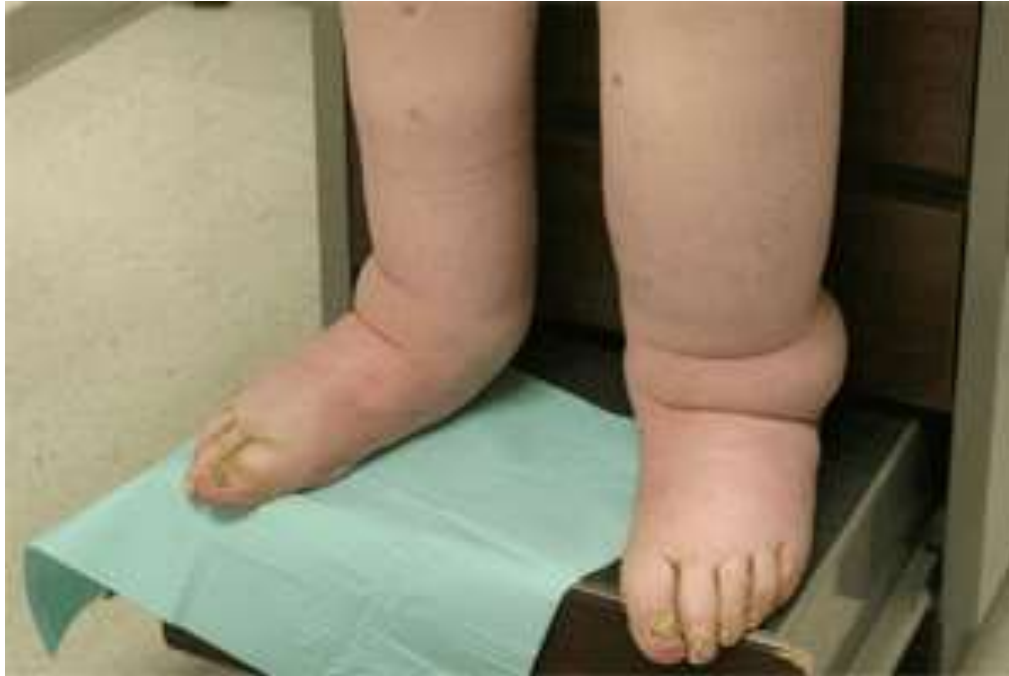Persistent coughing can be a symptom of heart failure

Interviewing of the patient: hemoptysis



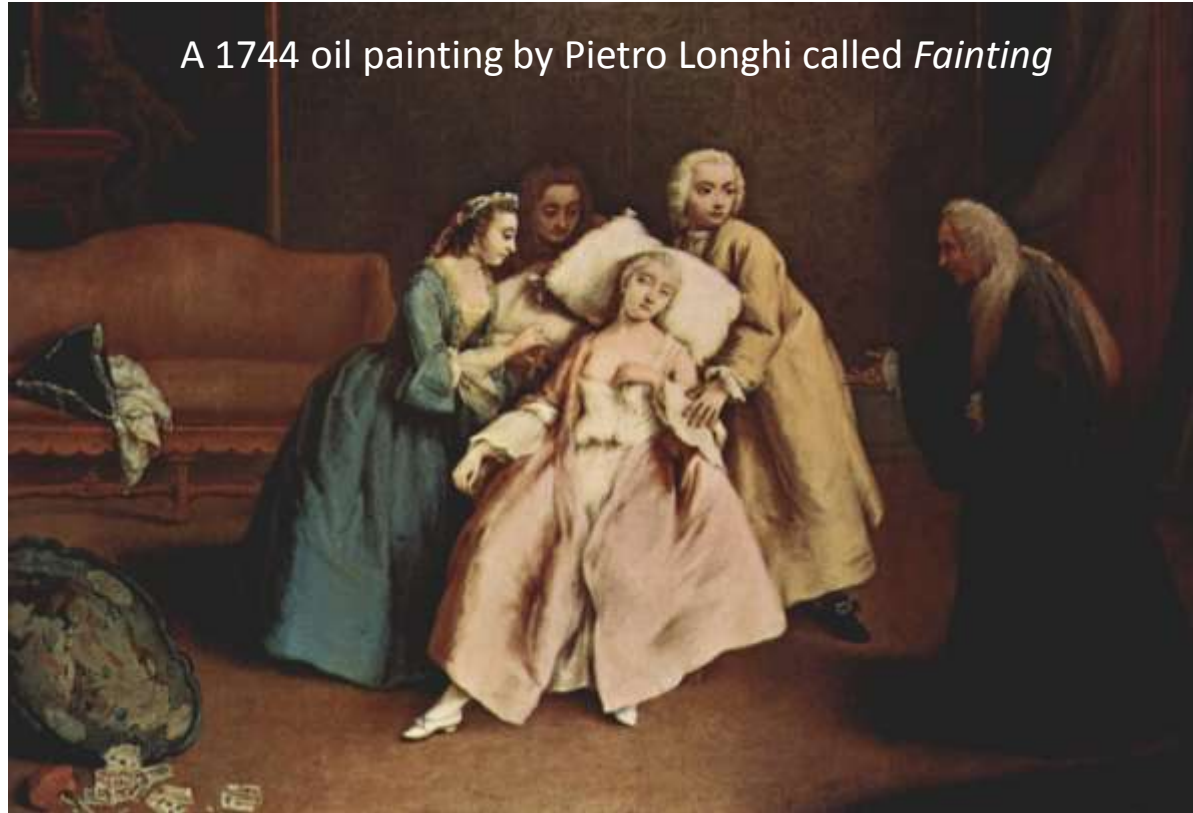- Hemoptysis is the act of coughing up blood or blood-stained mucus from the bronchi, larynx, trachea, or lungs
- The most common of these is left ventricular systolic heart failure

Interviewing of the patient: edema



Cardiogenic edema an accumulation of serum fluid from blood plasma in the interstitial tissues as a result of congestive heart failure

Interviewing of the patient: syncope



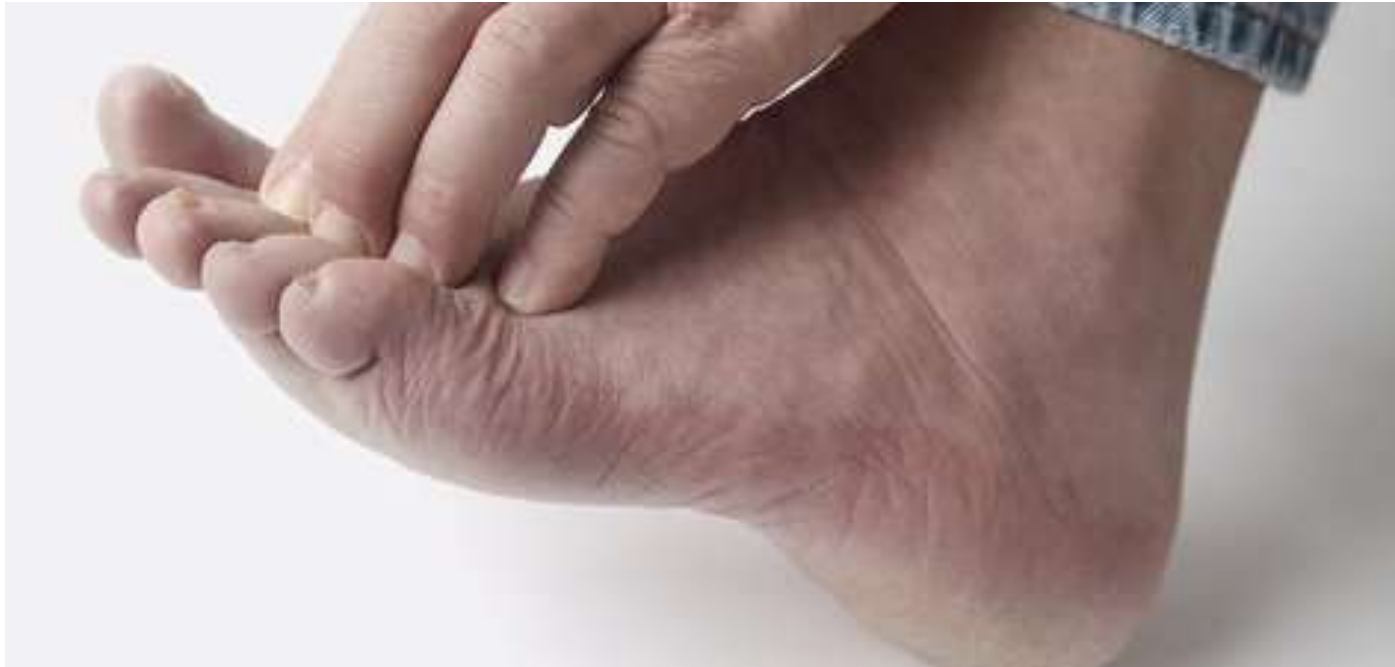A short loss of consciousness and muscle strength, characterized by a fast onset, short duration, and spontaneous recovery

Interviewing of the patient: irritability



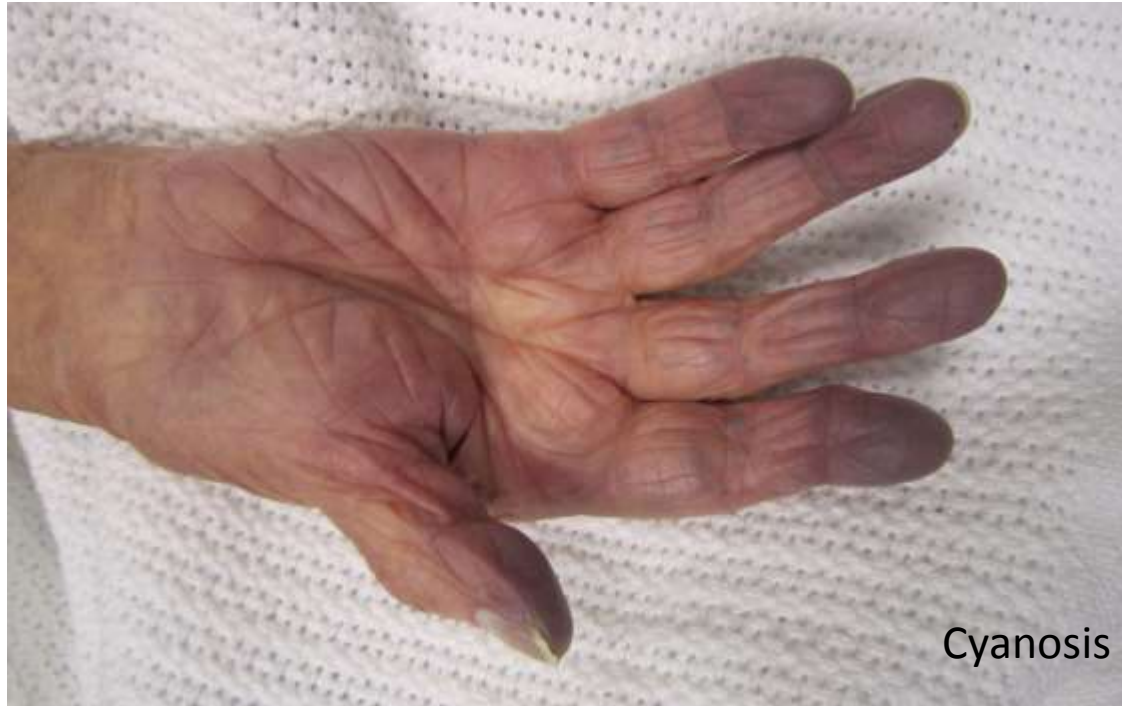An excitation response to stimuli

Interviewing of the patient: numbness/tingling



Numbness and tingling are unusual prickling sensations that can happen in any part of human body, but they are generally noticed in hands, feet, arms, and legs

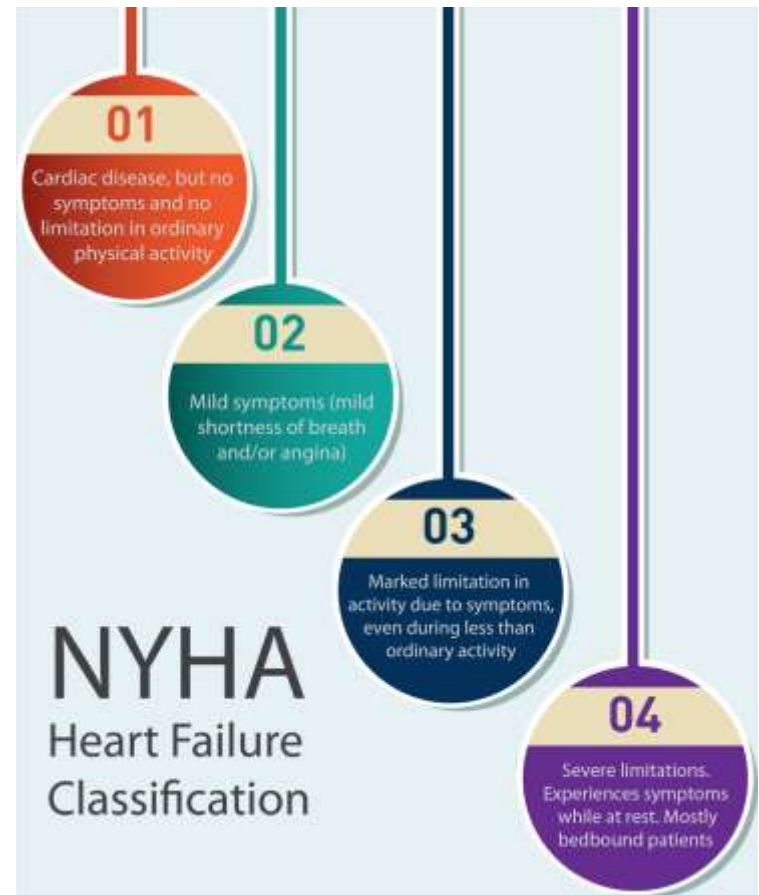
Interviewing of the patient: skin changes



Symptoms caused by heart **failure**

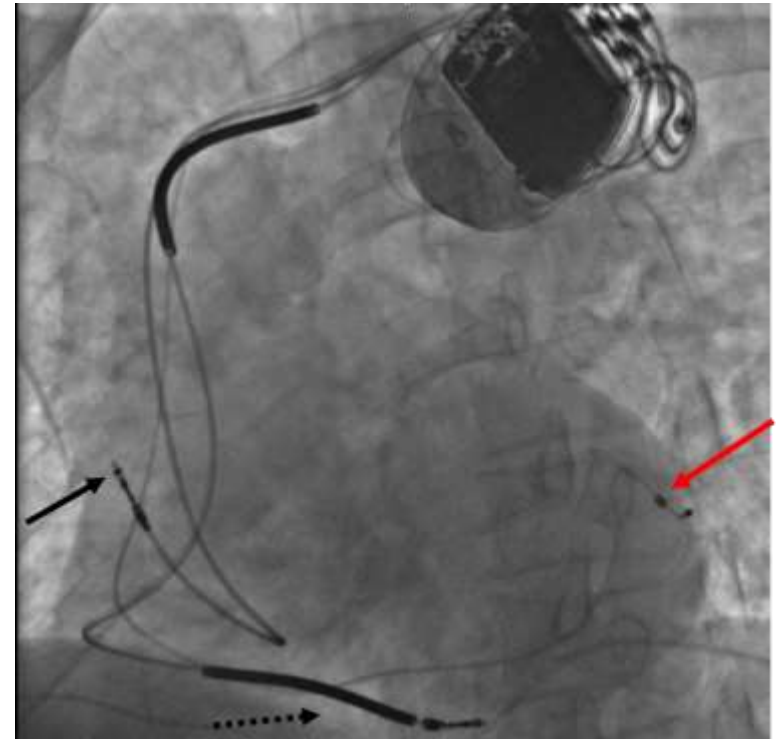
Interviewing of the patient: past medical history

The past medical history will include questions about conditions such as diabetes, high blood pressure, elevated cholesterol levels, prior surgery, asthma, stroke, cancer, allergies, etc.



Interviewing of the patient: prior or current treatment

- Medications
- Cardiac surgery
- Injections
- Chiropractic
- Exercise/PT (Physical Therapy)
- ER (Emergency Room)
- Massage therapy



Interviewing of the patient: previous treatment and present status

- Previous Treatment
 - What?
 - Where?
 - When?
 - By whom?
- Present Status
 - Better vs. same vs. worse



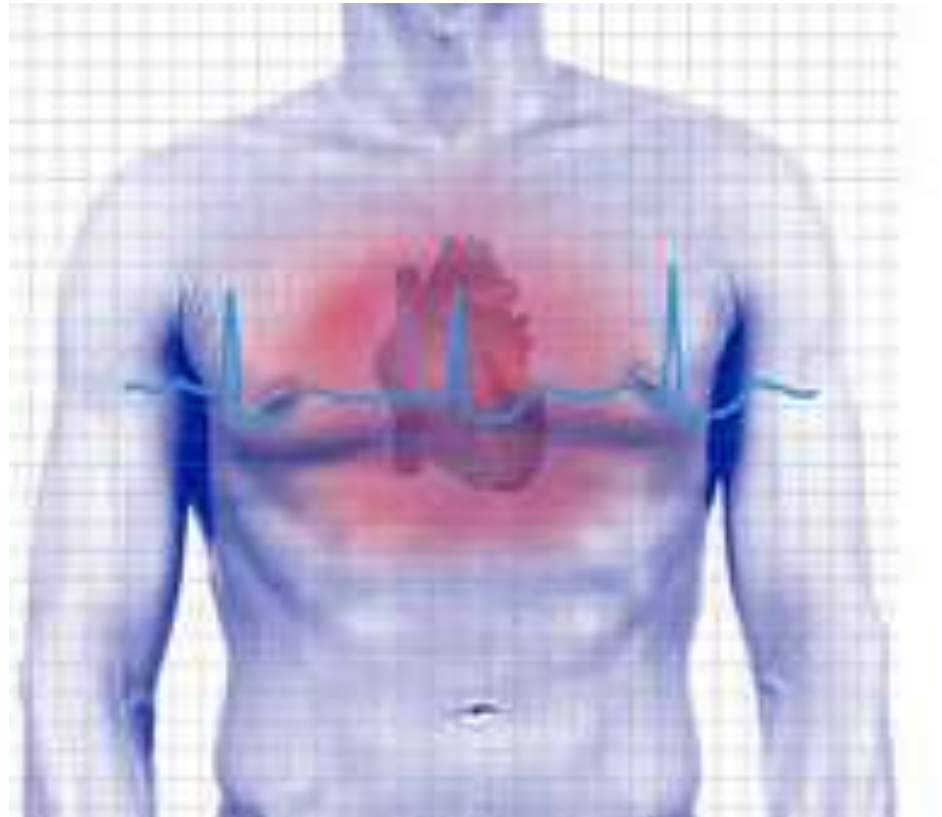Interviewing of the patient: family history

- Certain cardiac illnesses may occur in more than one member of a family
- The physician will inquire about the health of the patient's parents, brothers, sisters and children



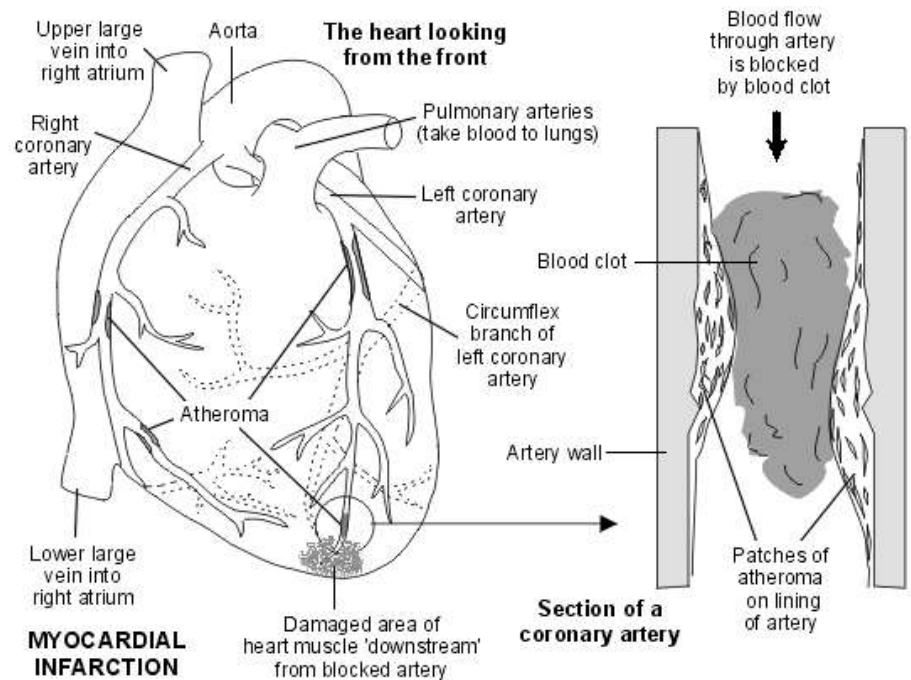
Interviewing of the patient: social history

- High-risk behaviors
 - Alcohol, tobacco, or drug abuse
 - Depression
 - Violence/abuse
 - Diet
 - Anorexia/bulimia
 - Sedentary lifestyle
- Signs of any of the above behaviors may warrant referral to a secondary provider



Interviewing of the patient: why take a medical history?

- Up 90% of conditions can be accurately diagnosed or recognized by conducting a thorough medical history and listening carefully to the patient's response(s)
- Determines the necessary tests and measures you should prioritize for your objective examination



Interviewing of the patient: review of systems

- The "laundry list" of symptoms related to various organs of the body
- A series of questions helps seek out information that the patient may have neglected to provide the physician
- Review of systems helps to identify the patient's problem, or exclude different parts of the differential diagnosis



Interviewing of the patient: systemic enquiry

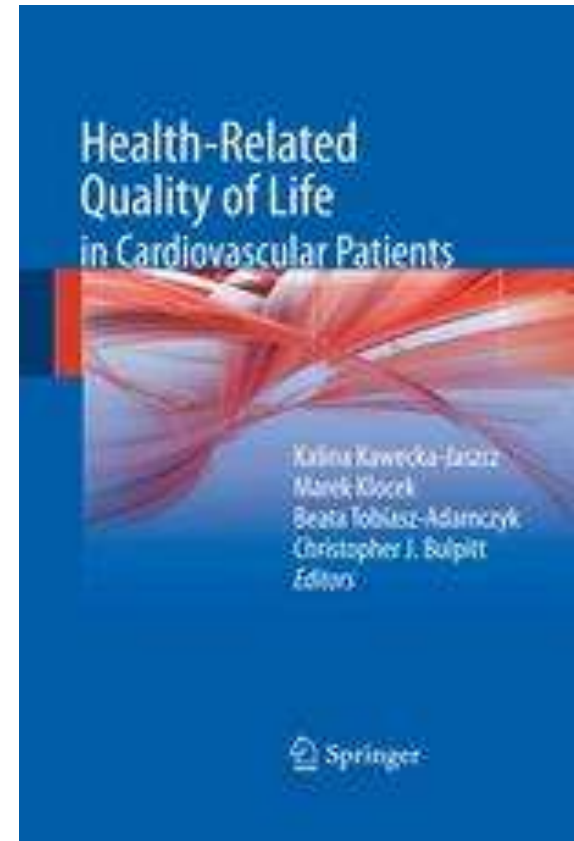
- General: fever, weight loss, loss of appetite, lethargy
- Respiratory system: shortness of breath, cough, hemoptysis, wheeze, chest pain
- Gastrointestinal system: nausea and vomiting, hematemesis, dysphagia, heartburn, jaundice, abdominal pain, change in bowel habit, rectal bleeding, tenesmus (sensation of incomplete bowel emptying)
- Genito-urinary system: dysuria (pain on passing urine), frequency, terminal dribbling, urethral discharge
- Gynecological system: pelvic pain, vaginal bleeding, vaginal discharge, LMP
- Neurological system: headaches, dizziness, loss of consciousness, fits, faints, funny turns, numbness, tingling, weakness, problems speaking, change in vision

Interviewing of the patient: short form-36 (SF-36)

- The Short Form-36 (SF-36) is a 36 item questionnaire which measures Quality of Life (QoL) across eight domains, which are both physically and emotionally based
- The eight domains are as follows: physical functioning; role limitations due to physical health; role limitations due to emotional problems; energy/fatigue; emotional well-being; social functioning; pain; general health
- A single item is also included that identifies perceived change in health, making the SF-36 a useful indicator for change in QoL over time and treatment

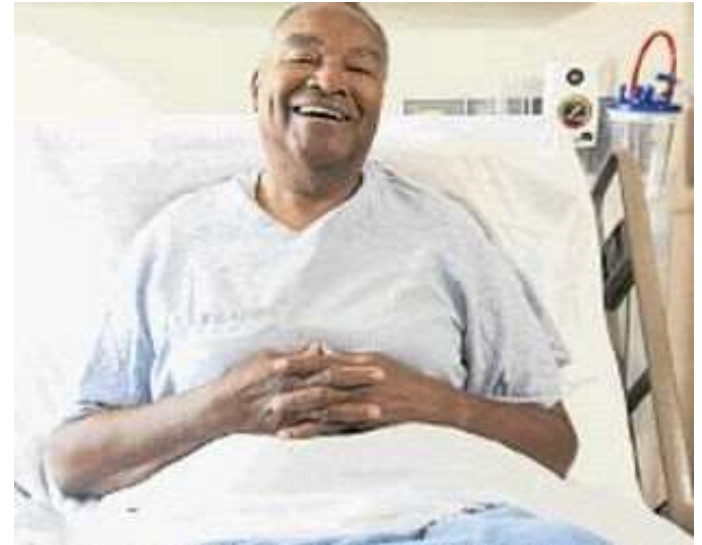Interviewing of the patient: functional status

- Quality of Life Scales
 - The Short Form-36 ([SF36](#))
 - Sickness Impact Profile Sickness Impact Profile
- Region Specific Disability Indices
 - [DASH \(Disabilities of Arm-Shoulder-Hand\)](#)
 - Oswestry Pain Indices (Neck or Back)
 - LEFS – Lower Extremity Functional Scale
- Disease Specific Scales



Physical examination of the patient: positioning

- The patient is positioned in the supine position tilted up at 45 degrees if can tolerate this
- The level of the jugular venous pressure (JVP) should only be commented on in this position as flatter or steeper angles lead to artificially elevated or reduced level respectively
- Lighting should be adjusted so that it is not obscured by the examiner who will approach from the right hand side of the patient as is medical custom



Physical examination of the patient: general inspection

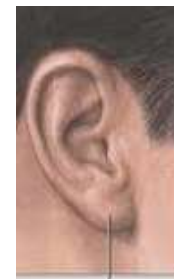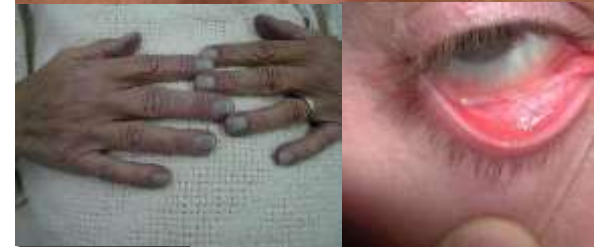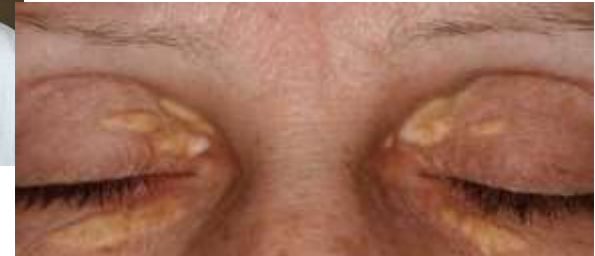- Inspect the patient status whether he or she is comfortable at rest or obviously short of breath
- Inspect the neck for increased jugular venous pressure (JVP) or abnormal waves
- Any abnormal movements such as head bobbing
- There are specific signs associated with cardiac illness and abnormality however, during inspection any noticed cutaneous sign should be noted

Physical examination of the patient: hands inspection

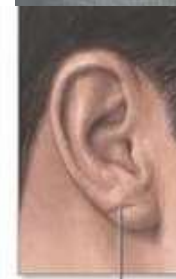- Temperature (warm, cool, clammy, dry)
- Skin turgor for hydration
- Janeway lesion (infective endocarditis)
- Osler's node (painful, red, raised lesions found on the hands and feet, are caused by immune complex deposition)
- Splinter hemorrhage, Quincke's pulsation, any deformity of the nail (Beau's lines, clubbing), peripheral cyanosis

Physical examination of the patient: head inspection

- The malar flush of mitral stenosis
- The eyes for corneal arcus and surrounding tissue for xanthlasma
- Conjunctiva pallor a sign of anemia
- The mouth for hygiene
- The mucosa for hydration and pallor or central cyanosis
- The ear lobes for Frank's sign



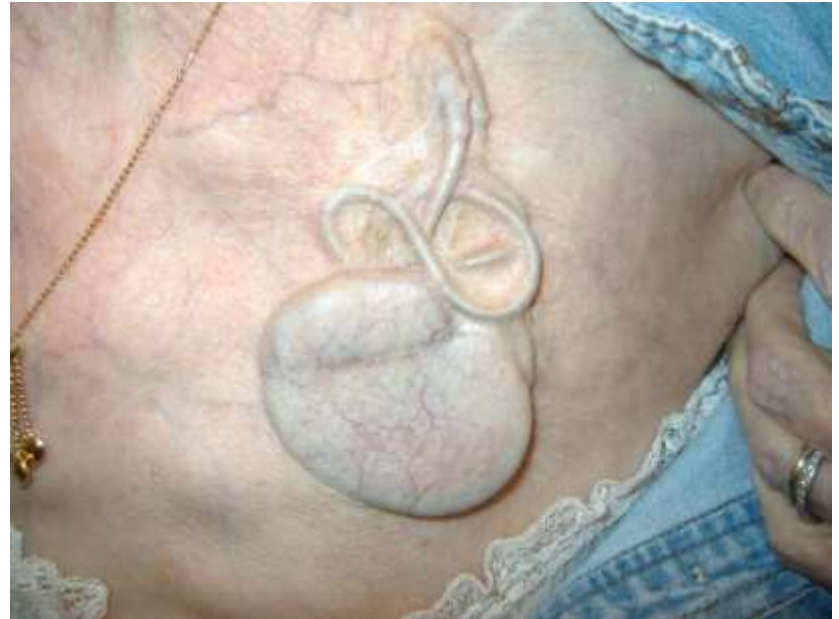Normal ear lobe



Ear lobe crease

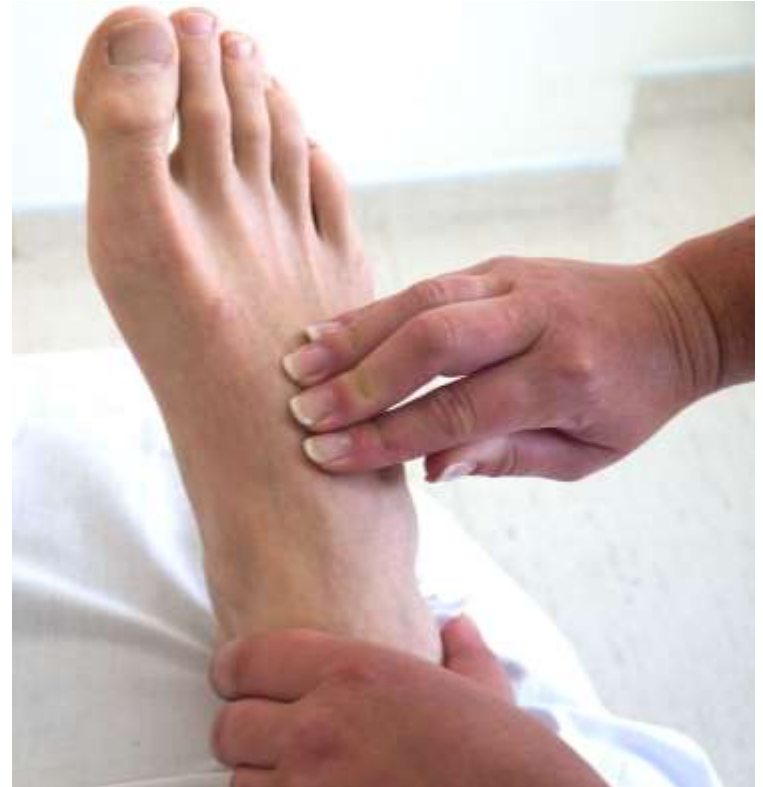Physical examination of the patient: precordial inspection

- Visible pulsations
- Apex beat
- Masses
- Scars
- Lesions
- Signs of trauma and previous surgery
- Permanent Pacemaker
- Precordial bulge



Physical examination of the patient: pulses (radial, brachial, carotid) palpation

- Rate
- Rhythm
- Pulse pressure -требуется измерения АД
- Regularity (regular, regularly irregular, irregularly irregular)
- Consistency of the strength to assess for pulsus alternans
- Slow rising (parvus, tardus)
- Jerky (hypertrophic cardiomyopathy)
- Traube's pistol shot femoral pulse



Physical examination of the patient: precordial palpation

- The valve areas are palpated for abnormal pulsations (palpable heart murmurs known as *thrills*) and precordial movements (known as *heaves*)
- The apex beat is found approximately in the 5th left intercostal space in the mid-clavicular line
 - The apex beat can be impalpable for a variety of reasons including obesity, emphysema, effusion and rarely dextrocardia
 - The apex beat is assessed for size, amplitude, location, impulse and duration
 - There are specific terms to describe the sensation such as tapping, heaving and thrusting

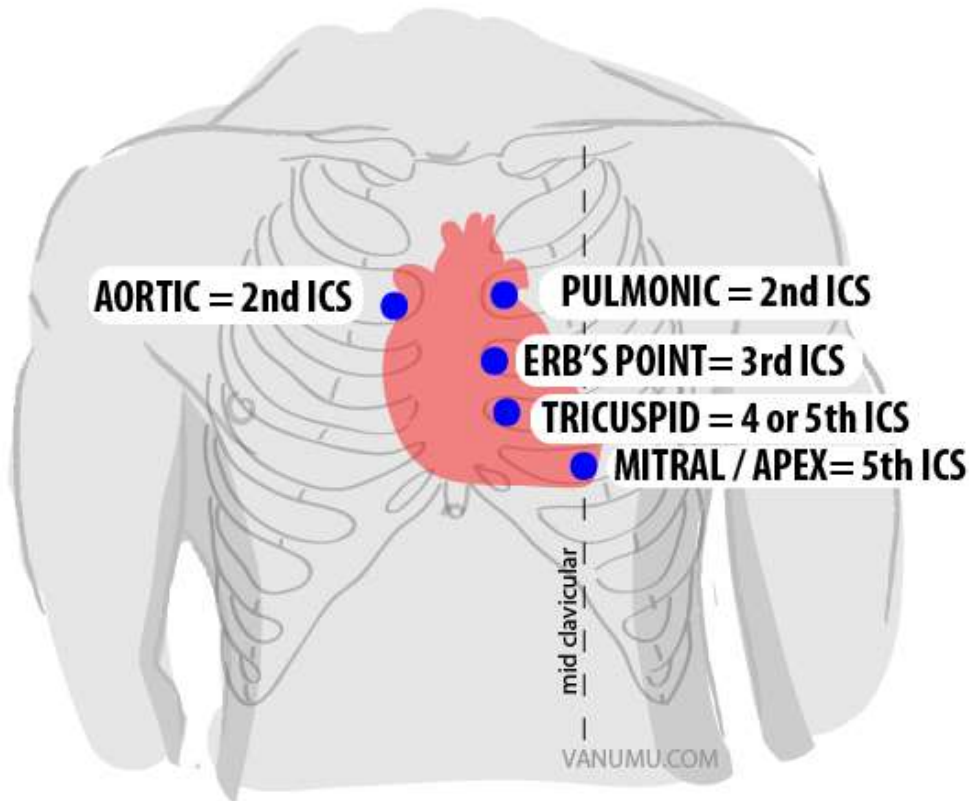
Physical examination of the patient: cardiac percussion: a lost art?

- There was a time when cardiac percussion was considered a useful addition in the clinical evaluation of the patient with heart disease
- This skill has been largely lost with the advent of new imaging techniques such as X-ray and echocardiography, both of which are more accurate in defining cardiac size and borders and detecting the presence and extent of pericardial fluid
- When used in isolation, cardiac percussion is prone to error but when used in clinical context with other findings, it could still be an invaluable bedside tool in differentiating tamponade from acute massive pulmonary embolism until confirmation with echocardiography

Physical examination of the patient: heart auscultation

- Auscultation is usually performed with the patient sitting up or reclined at about 45°
- Sites for auscultation
 - Mitral valve area: at the apex beat, as the left ventricle is closest to the thoracic cage
 - Tricuspid valve area: inferior right sternal margin is the point closest to the valve in which auscultation is possible
 - Pulmonary artery valve area: left second intercostal space close to the sternum is where the infundibulum is closest to the thoracic cage
 - Aortic valve area: right second intercostal space close to the sternum is where the ascending aorta is nearest to the thoracic cage
- The best place to hear the heart valves is not necessarily directly over the anatomical site

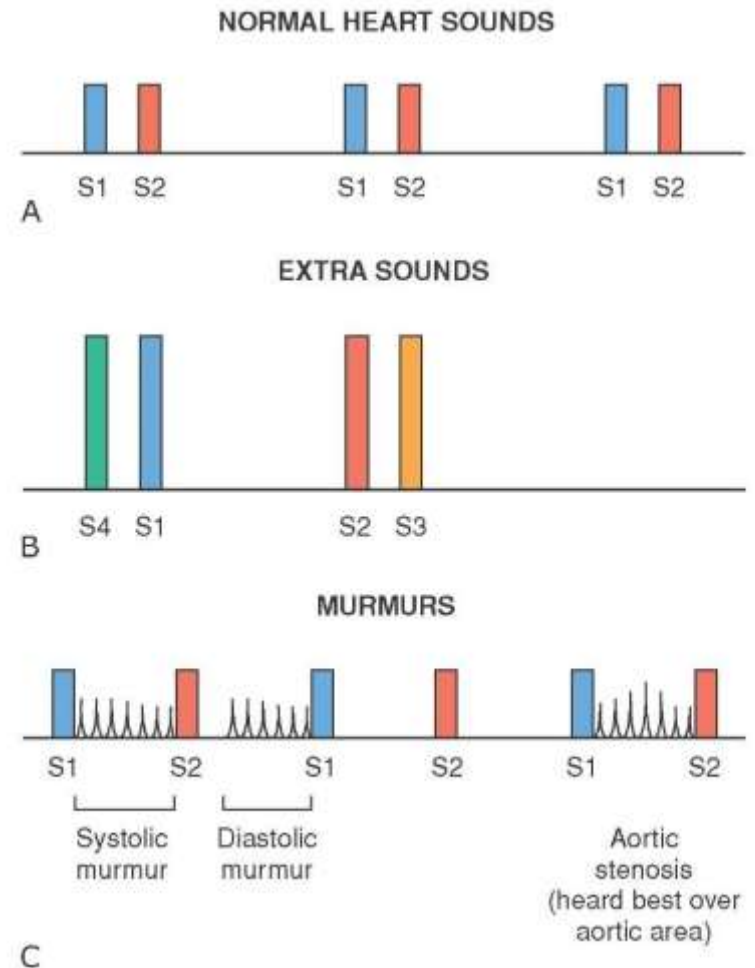
Physical examination of the patient: sites of the heart auscultation



- All People Eat Turkey Meat is the mnemonic I was taught to remember the points of auscultation of the heart
- All = Aortic
- People = Pulmonic
- Eat = Erb's Point
- Turkey = Tricuspid
- Meat = Mitral

Physical examination of the patient: normal heart sounds in auscultation

- Normal heart sounds are the noises generated by the beating heart and the resultant flow of blood through it, the sounds reflect the turbulence created when the heart valves snap shut
- In healthy adults, there are two normal heart sounds (lub, adub (dup)), that occur in sequence with each heartbeat
- These are the first heart sound (S_1) and the second heart sound (S_2), produced by the closing of the atrioventricular valves and semilunar valves

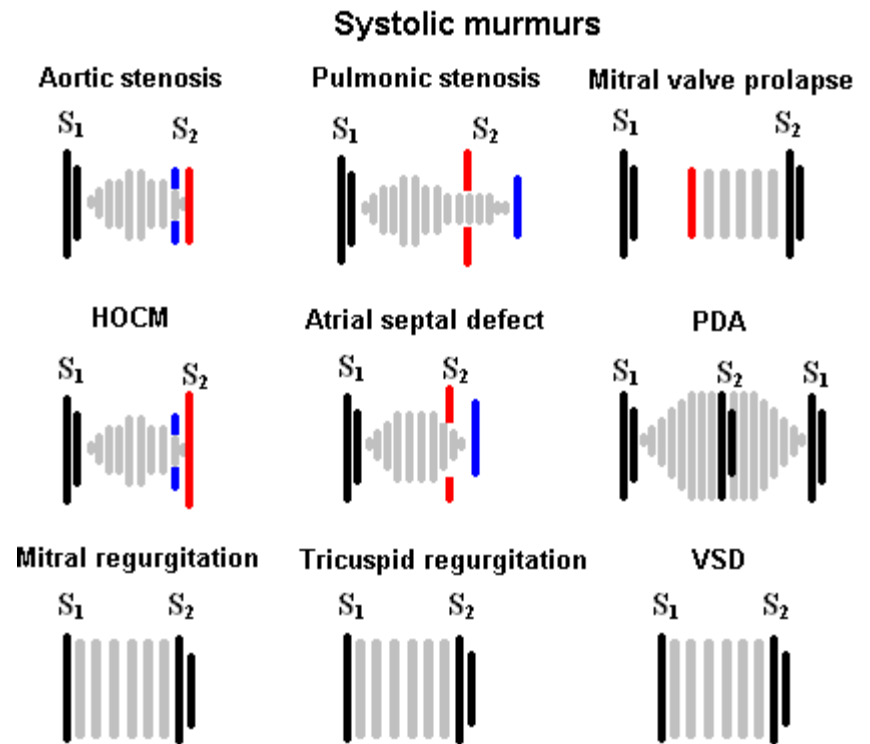


Physical examination of the patient: changes of normal heart sounds in auscultation

- The first sound may be split if there is pacing that triggers the right ventricle before the left or if mitral valve closure is delayed by high left atrial pressure or atrial myxoma
- The sounds may be softer than normal where there is severe mitral regurgitation, immobility from calcification, severe aortic regurgitation or left bundle branch block
- Prolapsed mitral valve or significant mitral stenosis may cause a loud M1
- Normally A2 and P2 are so close that they are heard as a single sound although they may split slightly on deep inspiration as P2 is delayed
- Beat to beat variation in the intensity of S2 occurs with complete or incomplete heart block if there is A-V dissociation
- P2 is delayed and will accentuate splitting in pulmonary hypertension, pulmonary stenosis and right bundle branch block
- Ectopic beats and pacing will delay A2 and cause 'reverse splitting' of the sound

Physical examination of the patient: other heart sounds in auscultation

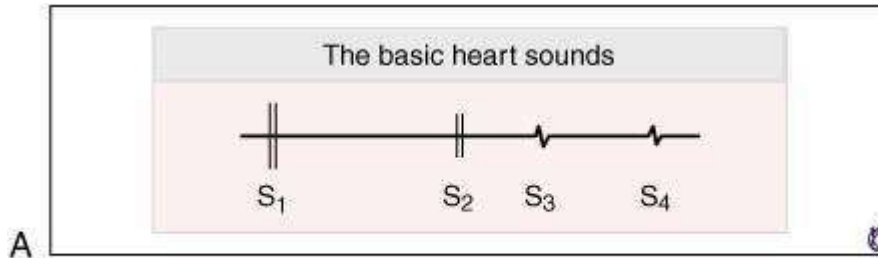
- Heart murmurs
- Adventitious (respiratory atc.) sounds
- Gallop rhythms S_3 and S_4 (may be heard in young or athletic people, ordinary are a signs of serious cardiac problems like heart failure as well as pulmonary edema)



Physical examination of the patient: heart murmurs in auscultation

- Heart murmurs are generated by turbulent blood flow , which may occur inside or outside the heart
- Murmurs may be physiological (benign) or pathological (abnormal)
- Abnormal murmurs can be caused by stenosis restricting the opening of a heart valve, resulting in turbulence as blood flows through it
- Abnormal murmurs may also occur with valvular insufficiency (regurgitation), which allows backflow of blood when the incompetent valve closes with only partial effectiveness
- Different murmurs are audible in different parts of the cardiac cycle, depending on the cause of the murmur

Physical examination of the patient: 3rd & 4th sounds in auscultation



Copyright © 2005 by Elsevier Inc.

- A 3rd sound in heart failure produces a cadence like a galloping horse ('gallop rhythm')
- A 4th sound occurs in ventricular hypertrophy, ischaemic heart disease, mitral stenosis, dilated cardiomyopathy, hyperdynamic circulation, arrhythmia, heart block just before the 1st and is an abnormal sound of the A-V valves opening as the atria contract
- An atrial myxoma can 'plop' during atrial systole and cause a late diastolic sound

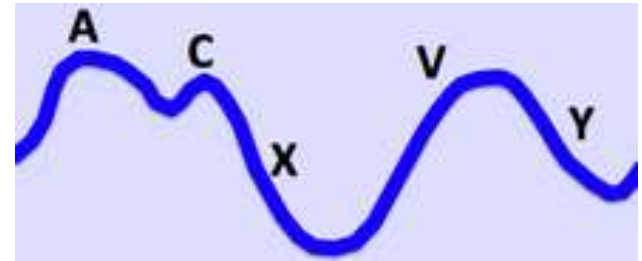
Physical examination of the patient: Levine's scale of heart sounds and murmurs graduation in auscultation

- I - lowest intensity, difficult to hear even by experts
- II - low intensity, but usually audible to all listeners
- III - medium intensity, easy to hear even by inexperienced listeners, but without a palpable thrill
- IV - medium intensity with a palpable thrill
- V - loud intensity with a palpable thrill. Audible even with the stethoscope placed on the chest, with the edge of the diaphragm
- VI - loudest intensity with a palpable thrill. Audible even with the stethoscope raised above the chest

Physical examination of the patient: jugular venous pressure

- The jugular venous pressure (JVP, sometimes referred to as *jugular venous pulse*) is the indirectly observed pressure over the venous system via visualization of the internal jugular vein
- JVP can be useful in the differentiation of different forms of heart and lung disease
- Classically three upward deflections and two downward deflections of the JVP:
 - The upward deflections are the "a" (atrial contraction), "c" (ventricular contraction and resulting bulging of tricuspid into the right atrium during isovolumetric systole) and "v" = atrial venous filling
 - The downward deflections of the wave are the "x" (the atrium relaxes and the tricuspid valve moves downward) and the "y" descent (filling of ventricle after tricuspid opening).

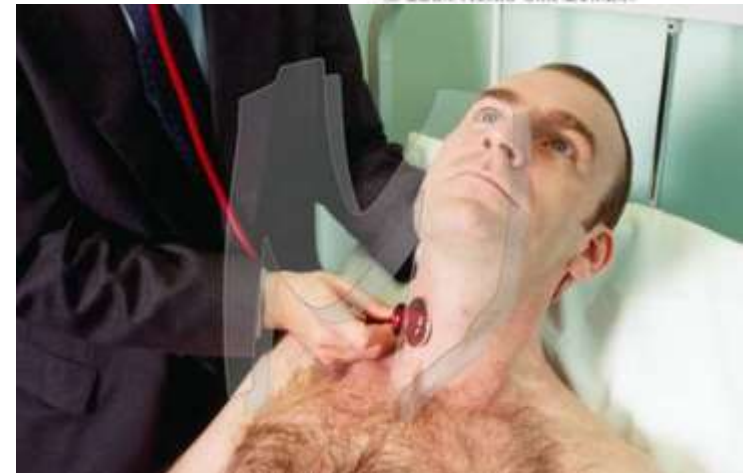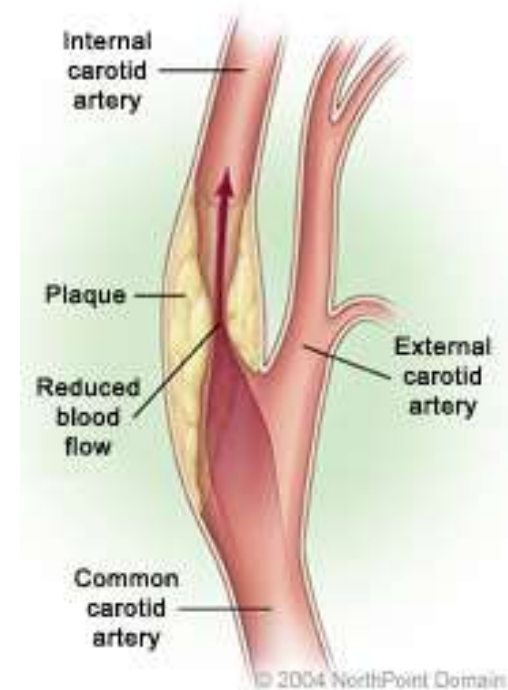
Physical examination of the patient: jugular venous pressure waveform



- The "a" wave corresponds to right **A**trial contraction and ends synchronously with the carotid artery pulse
- The "c" wave corresponds to right ventricular contraction causing the tri**C**uspid valve to bulge towards the right atrium
- The "x" descent follows the 'a' wave and corresponds to atrial rela**X**ation and rapid atrial filling due to low pressure
- The "v" wave corresponds to **V**enous filling when the tricuspid valve is closed and venous pressure increases from venous return - this occurs during and following the carotid pulse
- The "y" descent corresponds to the rapid empt**Y**ing of the atrium into the ventricle following the opening of the tricuspid valve

Physical examination of the patient: carotid bruit

- A carotid bruit is a systolic sound heard over the carotid artery area during auscultation
- Many carotid bruits are discovered incidentally in an otherwise asymptomatic
- Any bruit must be evaluated by ultrasound or imaging patient



Physical examination of the patient: ankle brachial pressure index

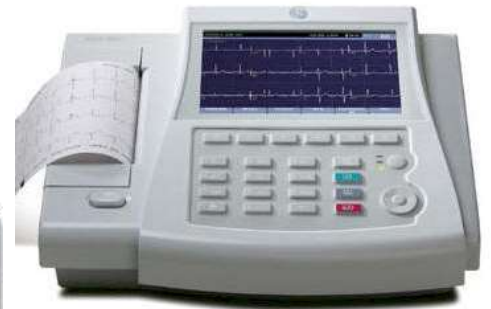
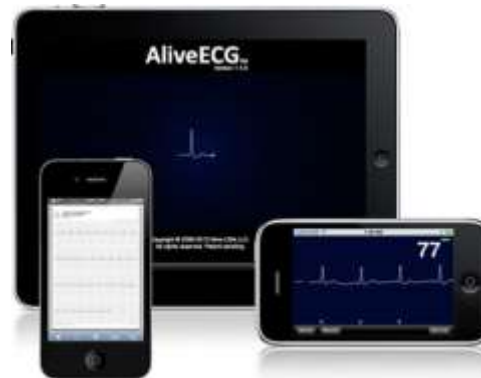- The ankle brachial pressure index (ABPI or ankle brachial index (ABI) is the ratio of the blood pressure in the lower legs to the blood pressure in the arms. Compared to the arm, lower blood pressure in the leg is an indication of blocked arteries (peripheral artery disease or PAD)
- The ABI is calculated by dividing the systolic blood pressure at the ankle by the systolic blood pressures in the arm

| ABI Value | Interpretation | Recommendation |
|------------------|----------------------------------|------------------------------|
| Greater than 1.4 | Calcification / Vessel Hardening | Refer to vascular specialist |
| 1.0 - 1.4 | Normal | None |
| 0.9 - 1.0 | Acceptable | |
| 0.8 - 0.9 | Some Arterial Disease | Treat risk factors |
| 0.5 - 0.8 | Moderate Arterial Disease | Refer to vascular specialist |
| Less than 0.5 | Severe Arterial Disease | Refer to vascular specialist |

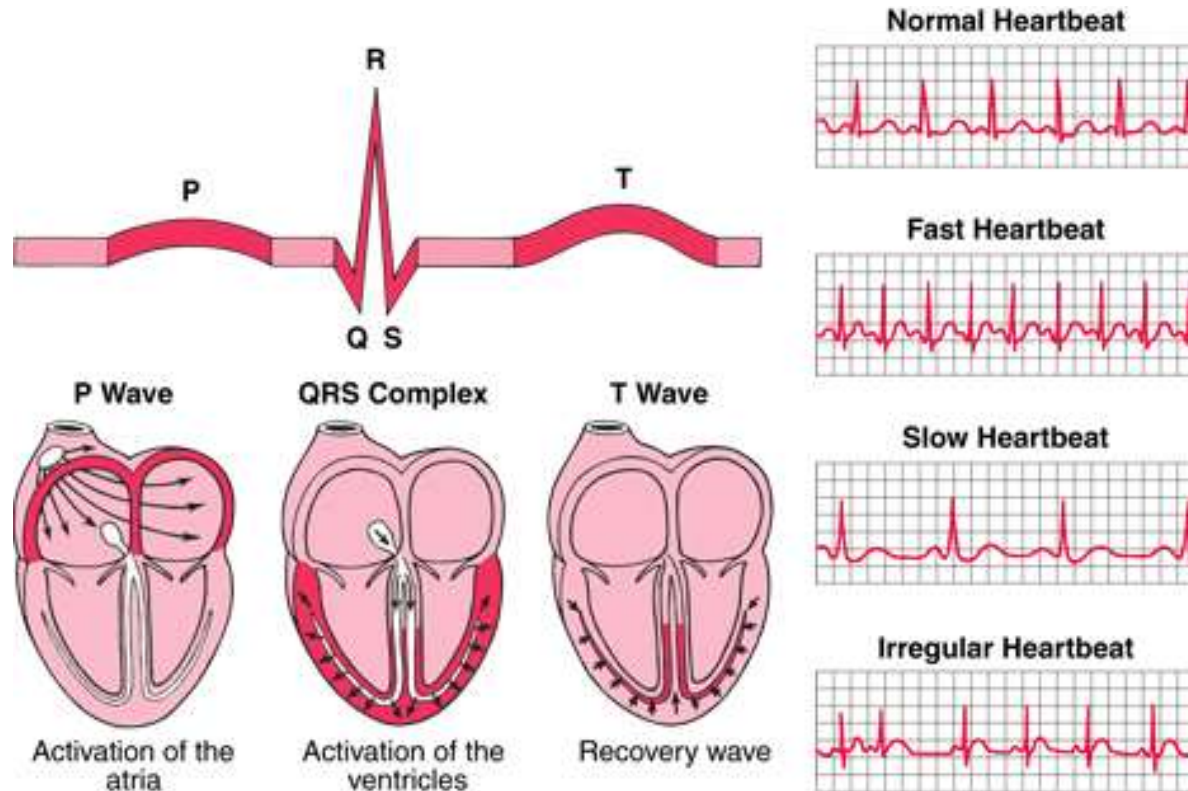
Instrumental methods: electrocardiography (ECG definition & targets)

- ECG is a test that records the electrical activity of the heart
- An ECG is used to measure:
 - Any damage to the heart
 - How fast heart is beating and whether it is beating normally
 - The effects of drugs or devices used to control the heart (such as a pacemaker)
 - The size and position of heart chambers
- The accuracy of the ECG depends on the condition being tested
- A heart problem may not always show up on the ECG
- Some heart conditions never produce any specific ECG changes

Instrumental methods: electrocardiography (devices in historical portrait)



Instrumental methods: electrocardiography (records examples)

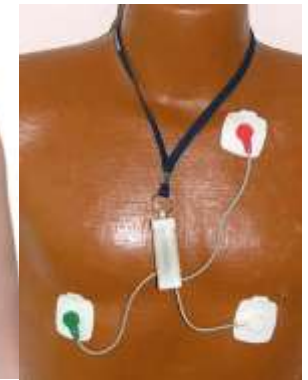
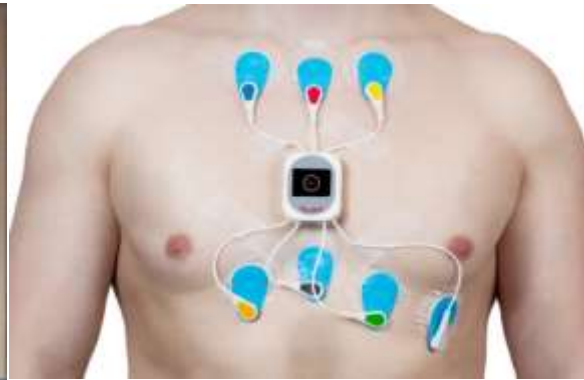
Instrumental methods:

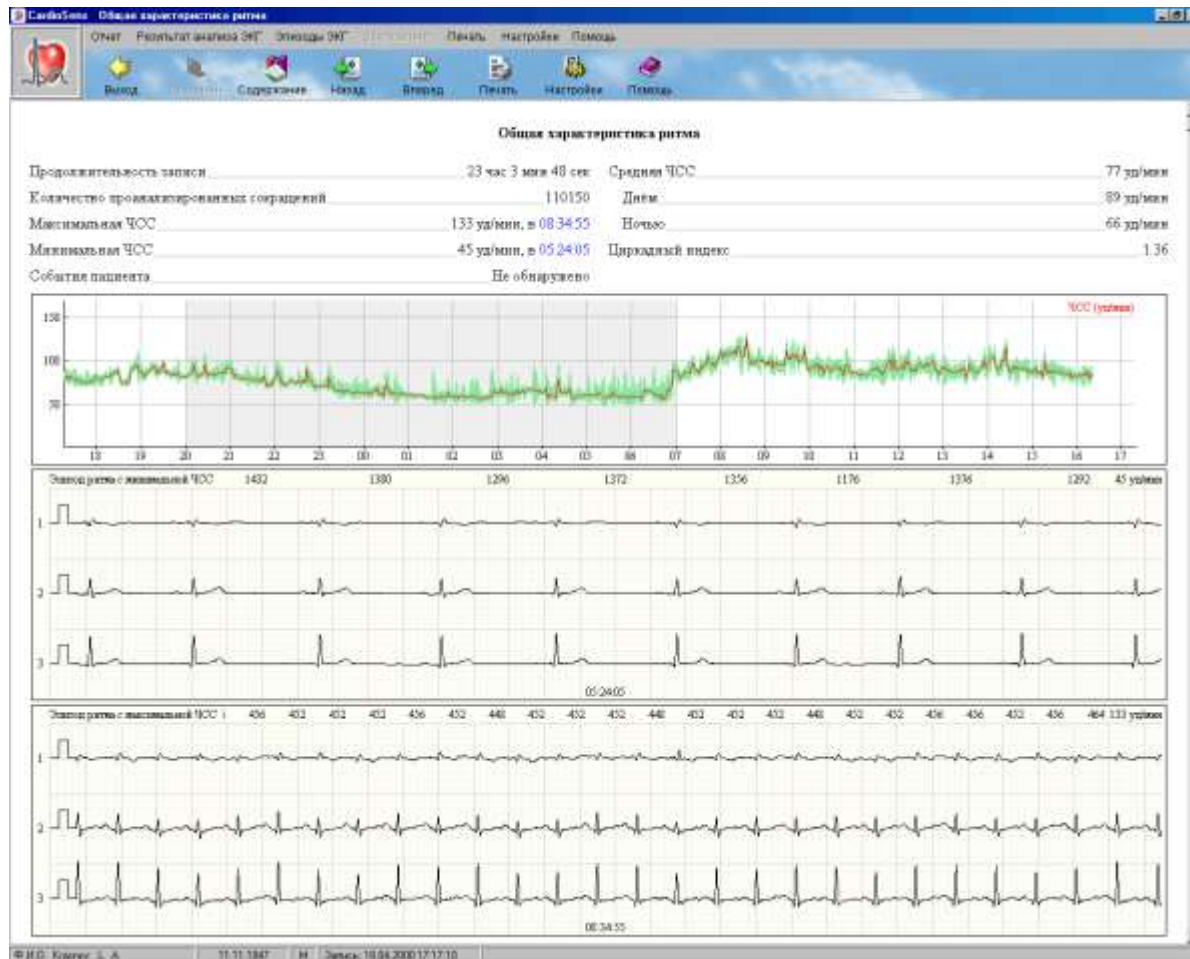Ambulatory electrocardiogram (Holter Monitor)

- The Holter monitor is a type of ECG used to monitor the ECG tracing continuously for a period of 24 hours or longer
- The Holter monitor used for suspected frequent rhythm abnormalities, especially ones the wearer may not recognize by symptoms:
 - Atrial fibrillation or flutter
 - Multifocal atrial tachycardia
 - Palpitations
 - Paroxysmal supraventricular tachycardia
 - Reasons for fainting
 - Slow heart rate (bradycardia)
 - Ventricular tachycardia
 - Chronomedicine

Instrumental methods: Holter Monitor (devices in historical portrait)



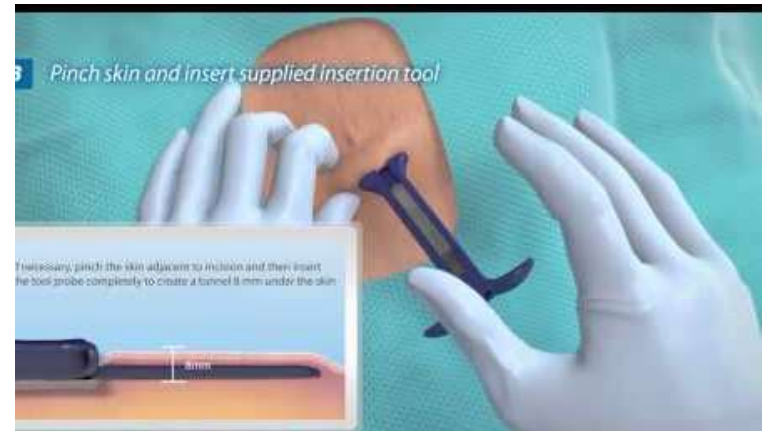
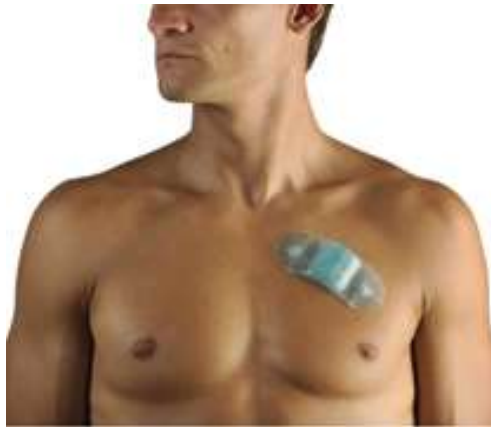Instrumental methods: Holter Monitor (records examples)



Instrumental methods: Event monitor (definition & targets)

- An Event monitor records short term EKG rhythm patterns, generally storing the last 2 to 5 minutes, adding in new and discarding old data, for 1 to 2 weeks or more
- When the wearer presses a button on the monitor, it quits discarding old and continues recording for a short additional period
- These monitors are used for suspected infrequent rhythm abnormalities, especially ones the wearer does recognize by symptoms

Instrumental methods: Event monitor (devices)



Instrumental methods: Event monitor (report examples)

| Transtelephonic Report | | Pacific Monitoring 8010 Fairwinds Road Ste. 200 Los Angeles, CA 90047 USA Tel: 213-44112 |
|---|--|--|
| PATIENT INFORMATION ID : 0000000000 Name : Yasmin Tawse Technician : Date of Birth : Jan 1, 2011 Medications : Indications : Diagnosis : | | EVENT INFORMATION Event ID : 0000000000-remote_0000 Event Receive Date : 2011-05-25 12:48:10.0 Event Record Date : 2011-05-25 12:48:10.0 Event Type : Receive Technician : 0000000000 Symptoms : Interpretations : |
| PHYSICIAN INFORMATION Name : MD Address : | | |
|  <div style="float: right; font-size: small;"> Page 1 of 1 Lead II Record 00 Date 05-25-2011 Time 12:48:10 </div> | | |
| Symptoms : Interpretations : Sinus Rhythm Record Date : 2011-05-25 12:48:10.0 Comments : | | |
|  <div style="float: right; font-size: small;"> Page 1 of 1 Lead II Record 00 Date 05-25-2011 Time 12:48:10 </div> | | |
| Symptoms : Interpretations : Sinus Rhythm Record Date : 2011-05-25 12:48:10.0 Comments : | | |
|  <div style="float: right; font-size: small;"> Page 1 of 1 Lead II Record 00 Date 05-25-2011 Time 12:48:10 </div> | | |
| Symptoms : Interpretations : Sinus Rhythm Record Date : 2011-05-25 12:48:10.0 Comments : | | |

Trans: 05-25-2011 10:55:00 EEP Page 1 © Copyright BioVital Inc

| Transtelephonic Report | | Pacific Monitoring 8010 Fairwinds Road Ste. 200 Los Angeles, CA 90047 USA Tel: 213-44112 |
|--|--|--|
| PATIENT INFORMATION ID : 0000000000 Name : Yasmin Tawse Technician : Date of Birth : Jan 1, 2011 Medications : Indications : Diagnosis : | | EVENT INFORMATION Event ID : 0000000000-remote_0000 Event Receive Date : 2011-05-26 11:27:40.0 Event Record Date : 2011-05-26 11:27:40.0 Event Type : Receive Technician : 0000000000 Symptoms : Interpretations : |
| PHYSICIAN INFORMATION Name : MD Address : | | |
|  <div style="float: right; font-size: small;"> Page 1 of 1 Lead II Record 00 Date 05-26-2011 Time 11:27:40 </div> | | |
| Symptoms : Interpretations : Sinus Rhythm Record Date : 2011-05-26 11:27:40.0 Comments : Sinus Rhythm | | |

Trans: 05-26-2011 10:55:00 EEP Page 1 © Copyright BioVital Inc

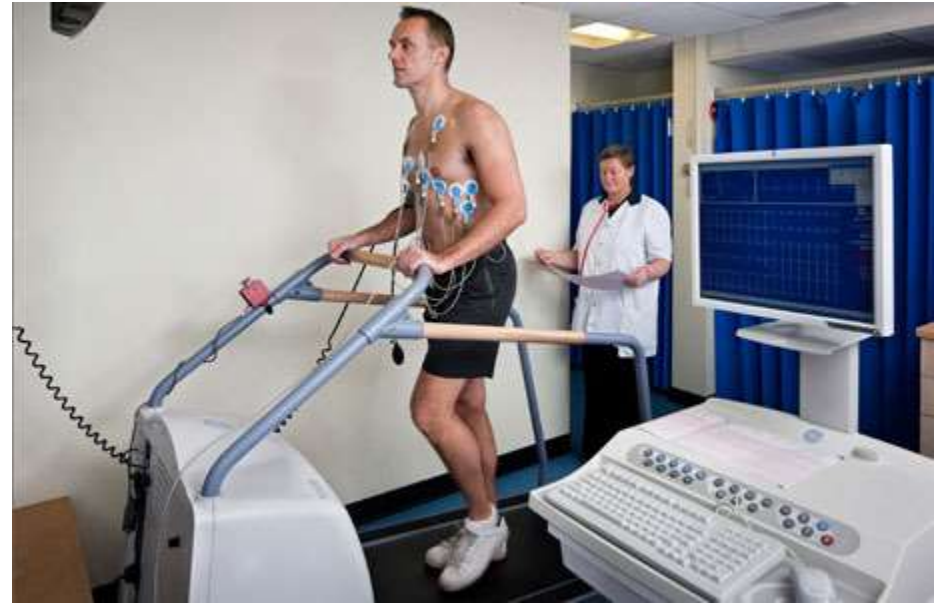Instrumental methods: Cardiac stress test (definition & targets)

- A test used to measure the heart's ability to respond to external stress in a controlled clinical environment
- The stress response is induced by exercise or drug stimulation
- Cardiac stress tests compare the coronary circulation while the patient is at rest with the same patient's circulation observed during maximum physical exertion, showing any abnormal blood flow to the heart's muscle tissue (the myocardium)
- The results can be interpreted as a reflection on the general physical condition of the test patient
- This test can be used to diagnose ischemic heart disease, and for patient prognosis after a heart attack (myocardial infarction)

Instrumental methods: Cardiac stress test (stress ECG)

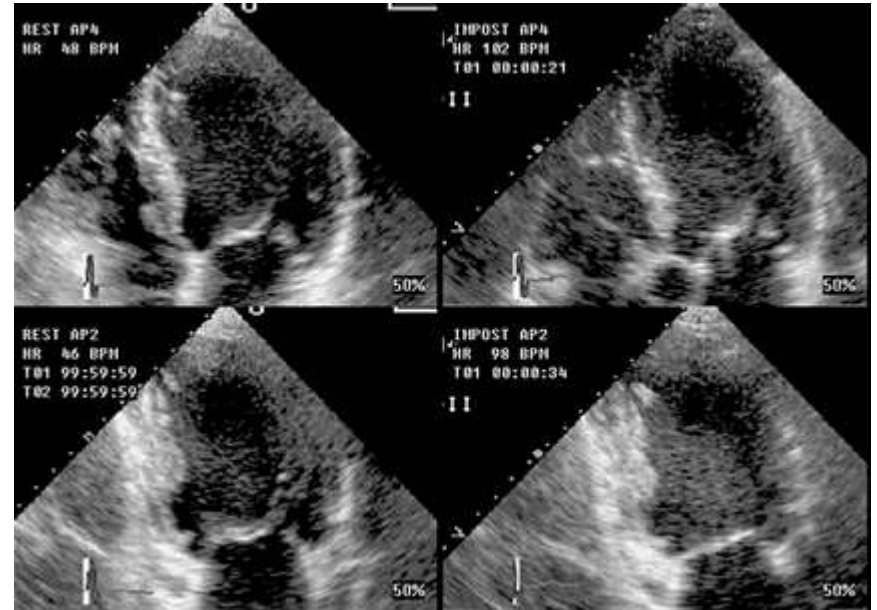
An exercise ECG is done to:

- find the cause of unexplained chest pain or pressure
- decide which treatments are best for a person with angina
- evaluate the patient's ability to tolerate exercise
- find the cause of symptoms that occur during exercise or activity
- evaluate the efficacy of anti-anginal and antiarrhythmic therapy



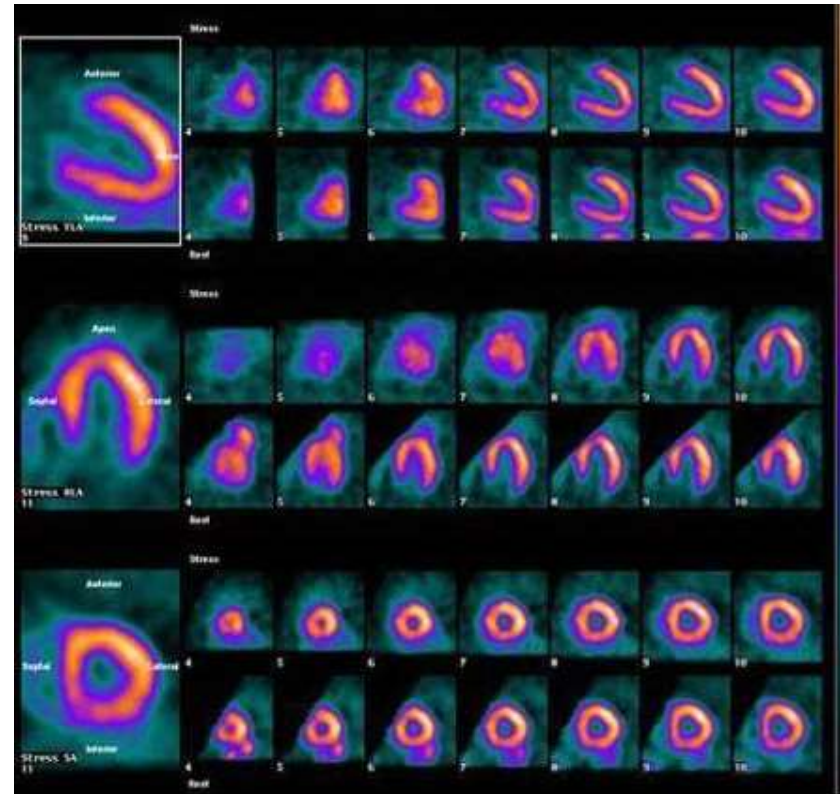
Instrumental methods: Cardiac stress test (stress echocardiography)

- Cardiac stress test may be accompanied by echocardiography
- The echocardiography is performed both before and after the exercise so that structural differences can be compared
- The patient is subjected to stress in the form of exercise or chemically induced stress (usually dobutamine)
- This is used to detect obstructive coronary artery disease



Instrumental methods: Cardiac stress test (nuclear stress test)

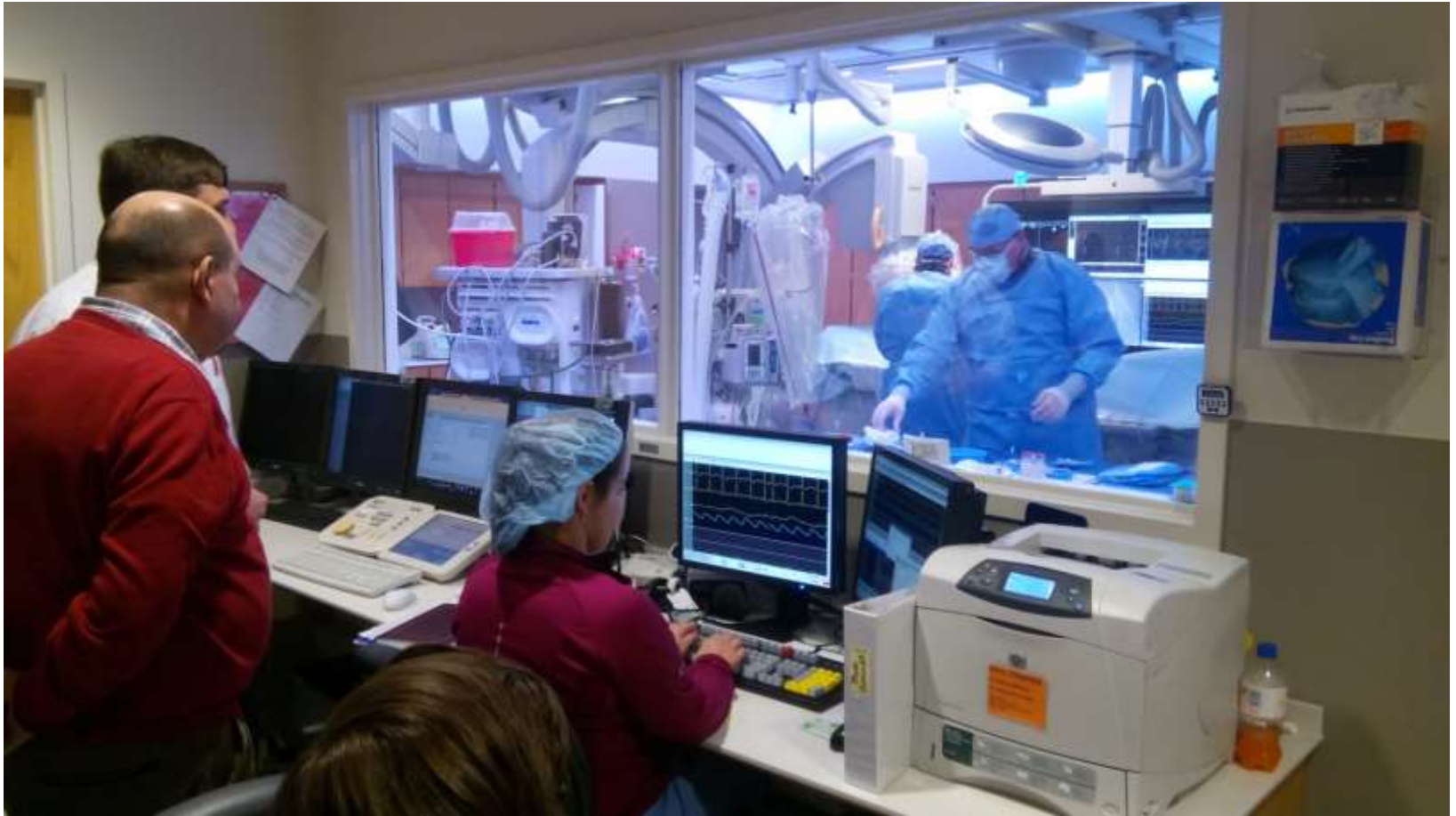- A test measures blood flow to patient's heart at rest and stress as a result of exertion or medication
- The test provides images that can show areas of low blood flow through the heart and damaged heart muscle



Instrumental methods: Electrophysiology study (definition & targets)

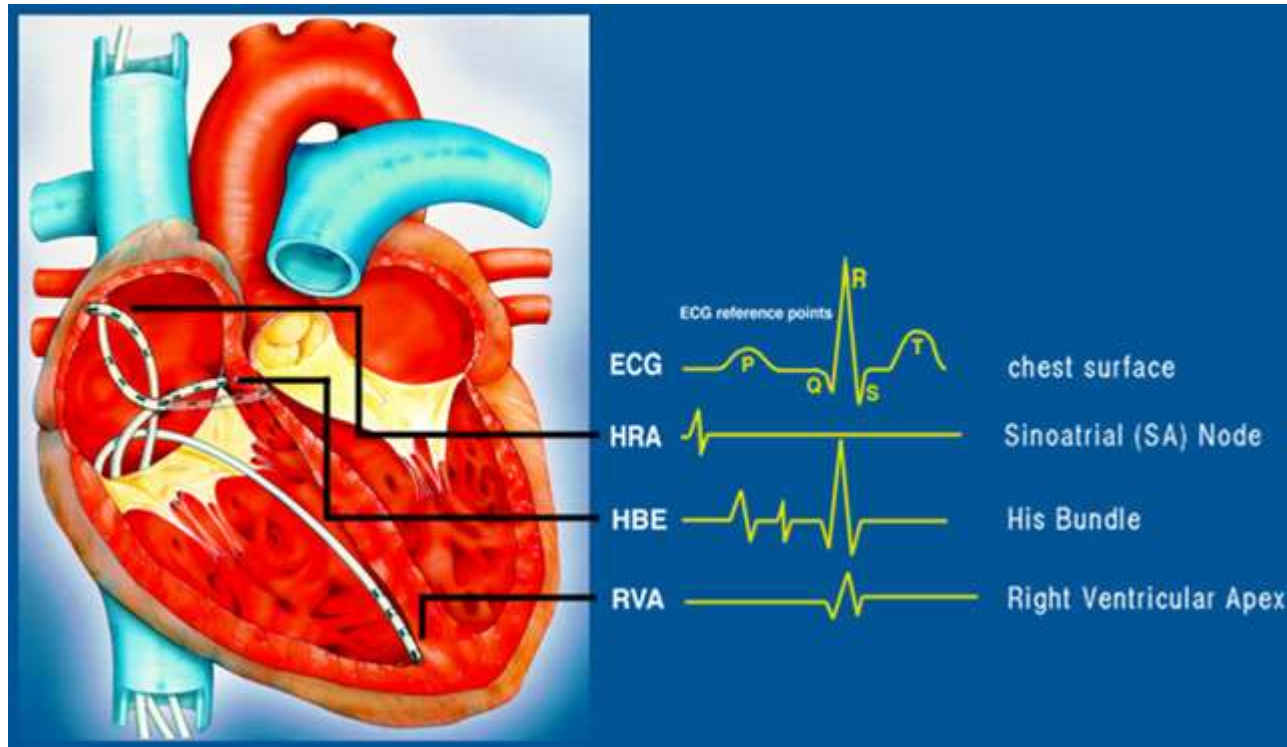
- A minimally invasive procedure that tests the electrical conduction system of the heart
- During electrophysiology study (EPS), sinus rhythm as well as supraventricular and ventricular arrhythmias of baseline cardiac intervals is recorded
- The EPS is indicated to investigate the cause, location of origin, and best treatment for various abnormal heart rhythms
- This type of study is performed by an electrophysiologist and using a single or multiple catheters situated within the heart through a vein or artery

Instrumental methods: Electrophysiology study (Laboratory)



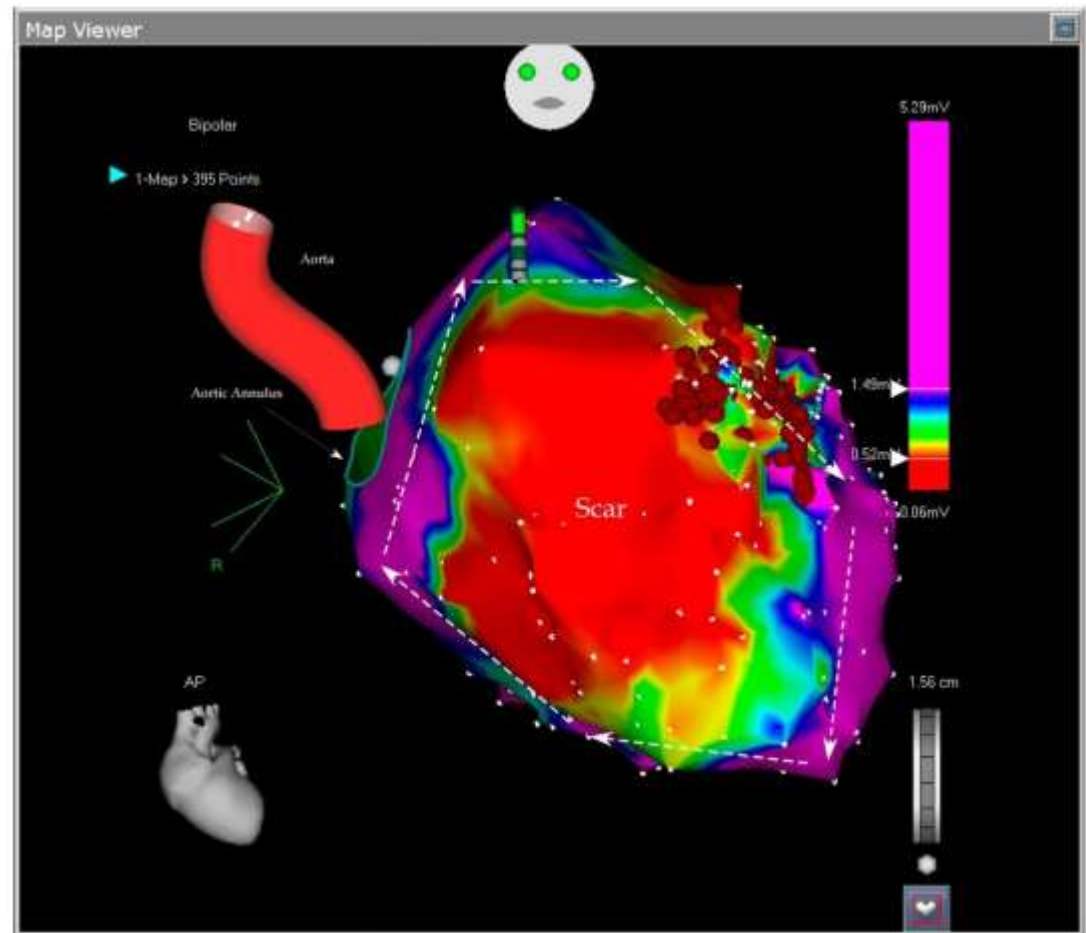
University Mississippi Medical Center

Instrumental methods: Electrophysiology study (technique)



Instrumental methods: Electrophysiology study (results' example)

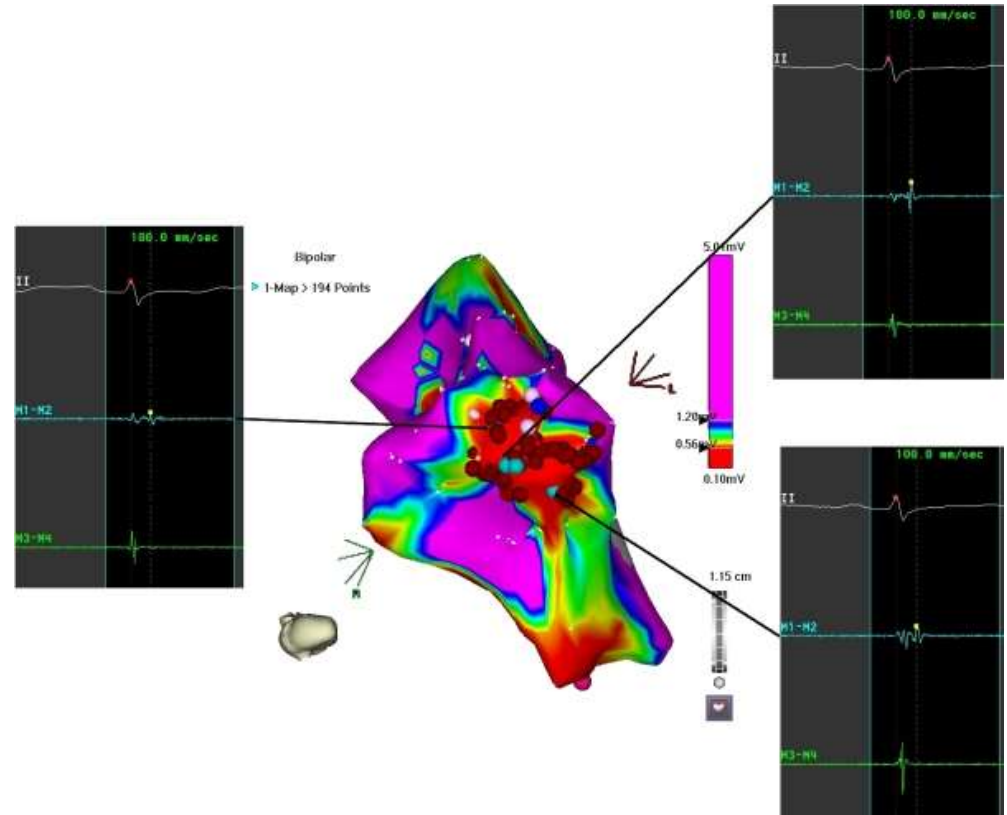
The picture shows
the antero-
posterior projection
of the enlarged left
ventricle with a
large scar on almost
all the anterior wall



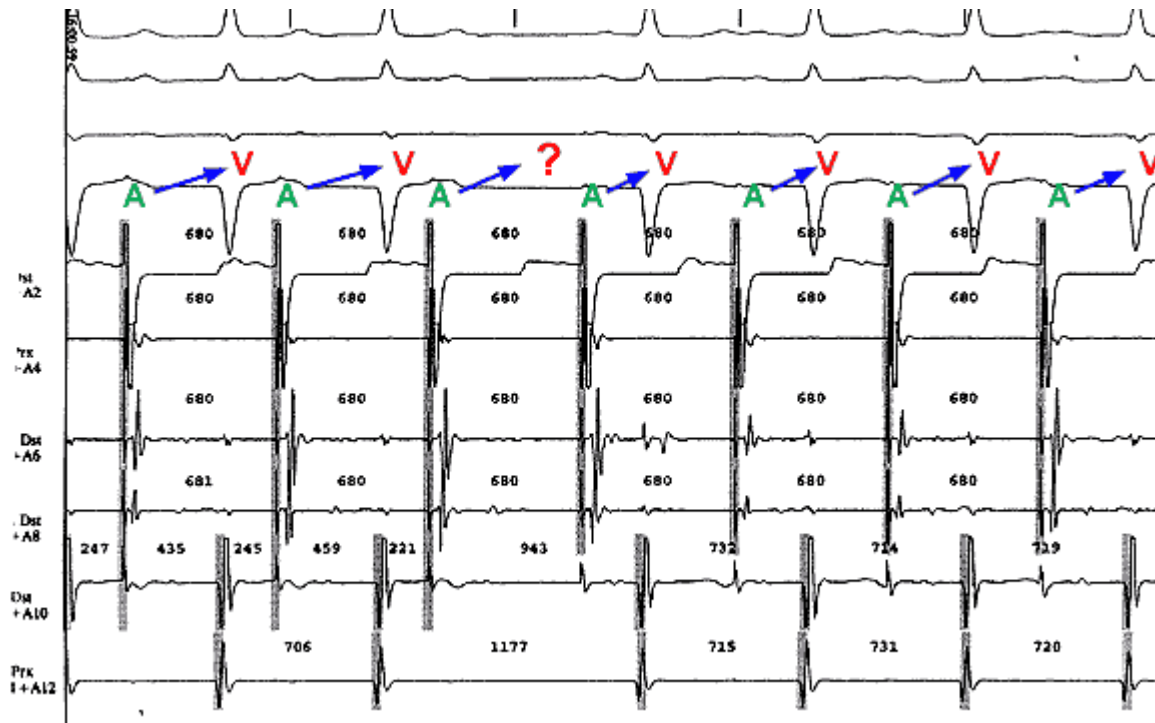
Instrumental methods: Electrophysiology study (results' example)

Voltage map of the right ventricle rotated to show the scar in the apex

Representative signals from three regions within the scar show double potentials with the second component occurring well beyond the end of the QRS



Instrumental methods: Electrophysiology study (results' example)

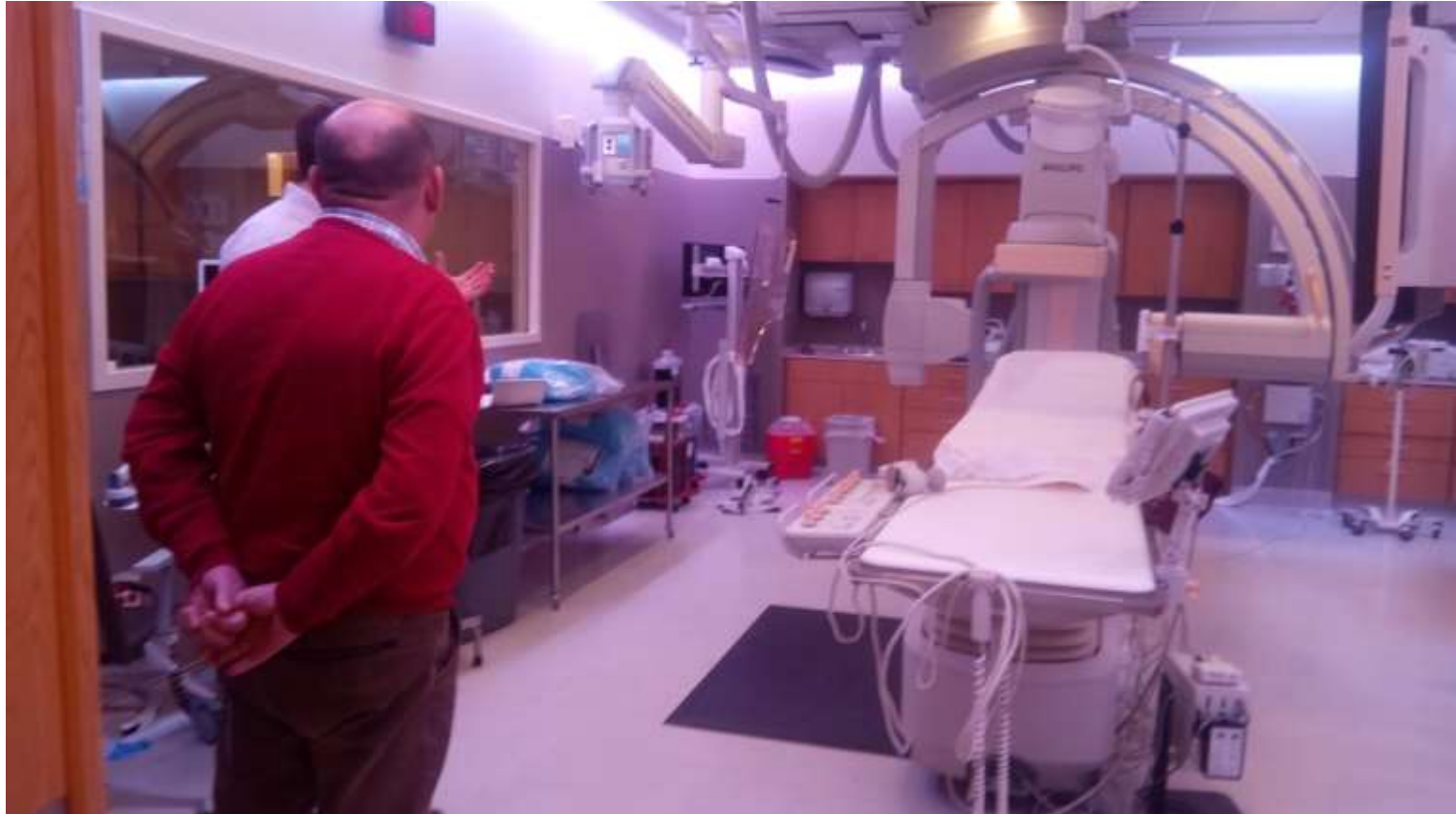

This image demonstrates how the Wenckebach cycle length appears during an EPS. The right atrium is being paced on the "RA Dst" channel. The time between A and V increases until the ventricular signal is blocked due to repolarization of the ventricle as indicated by the T wave. The Wenckebach cycle length (600ms) is a significantly abnormal interval

Instrumental methods: Coronary catheterization (definition & targets)

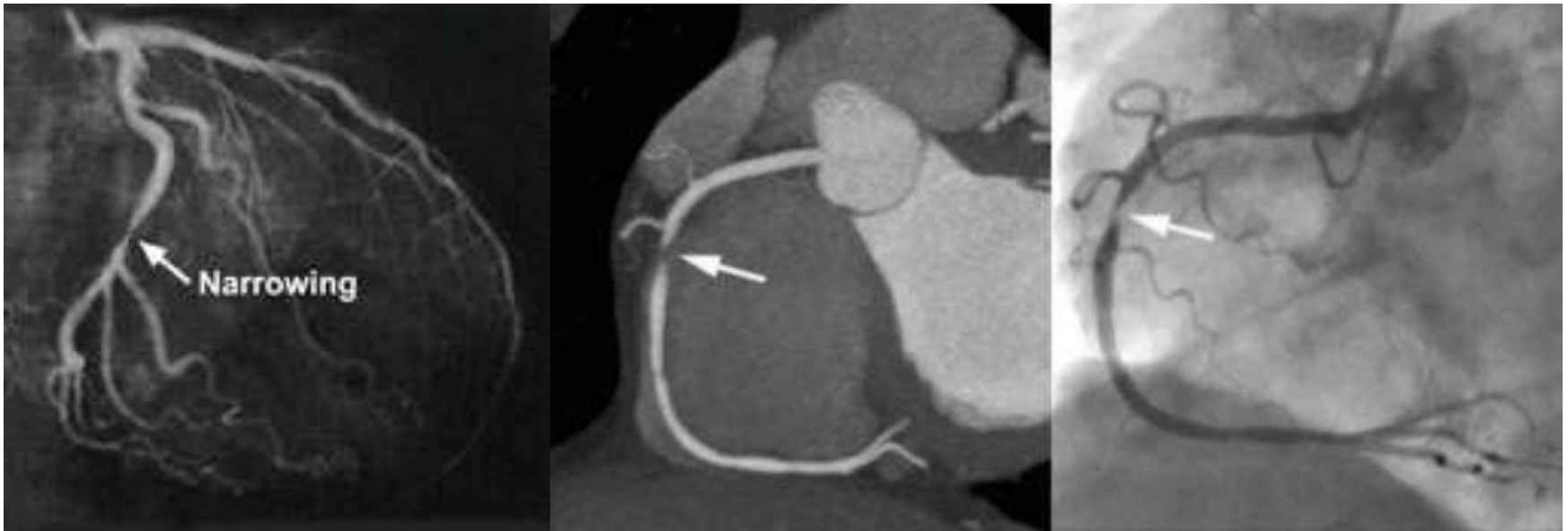- Cardiac catheterization (cardiac cath, coronary angiogram) is an invasive imaging procedure that tests for heart disease by allowing doctor to "see" the inside of the arteries and how well patient's heart is functioning
- During the test, a long, narrow tube, called a catheter, is inserted into a blood vessel in patient's arm or leg and guided to heart
- Contrast dye is injected through the catheter so that X-ray movies of patient's valves, coronary arteries, and heart chambers can be created

Instrumental methods: Coronary catheterization (device)



University Mississippi Medical Center

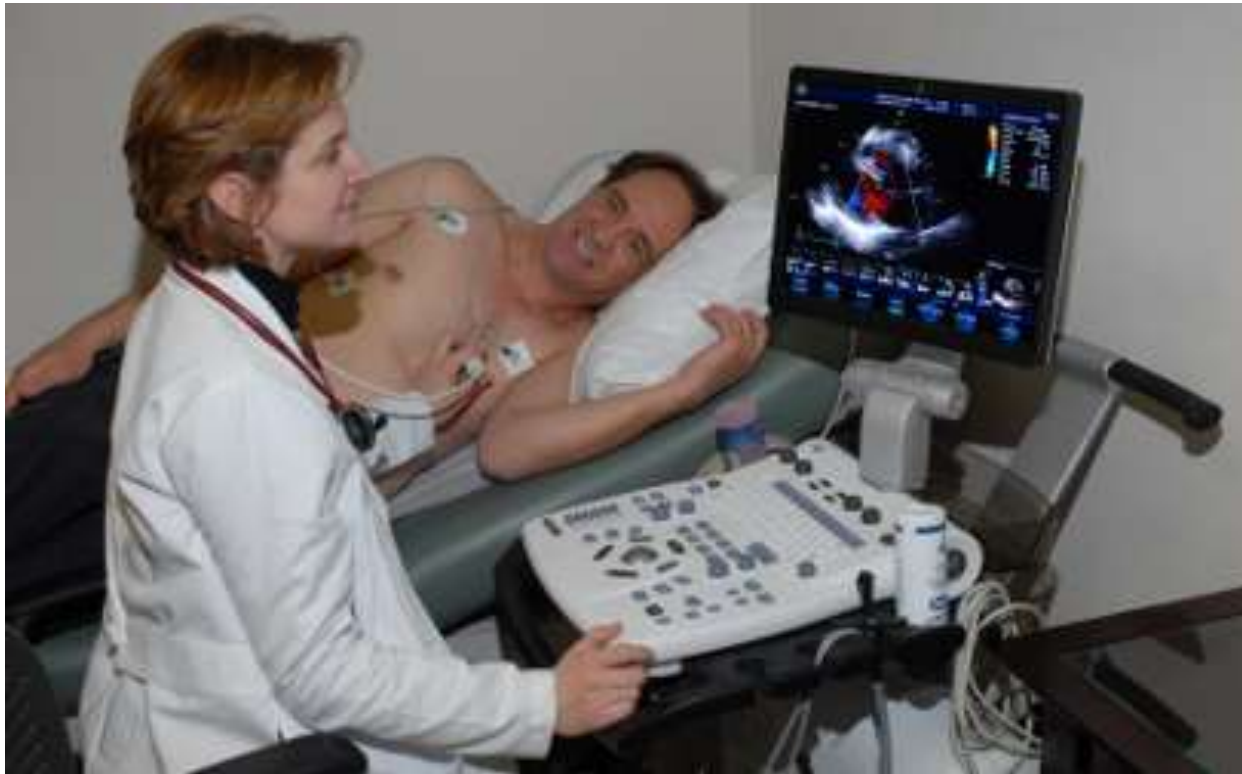Instrumental methods: Coronary catheterization (angiograms)



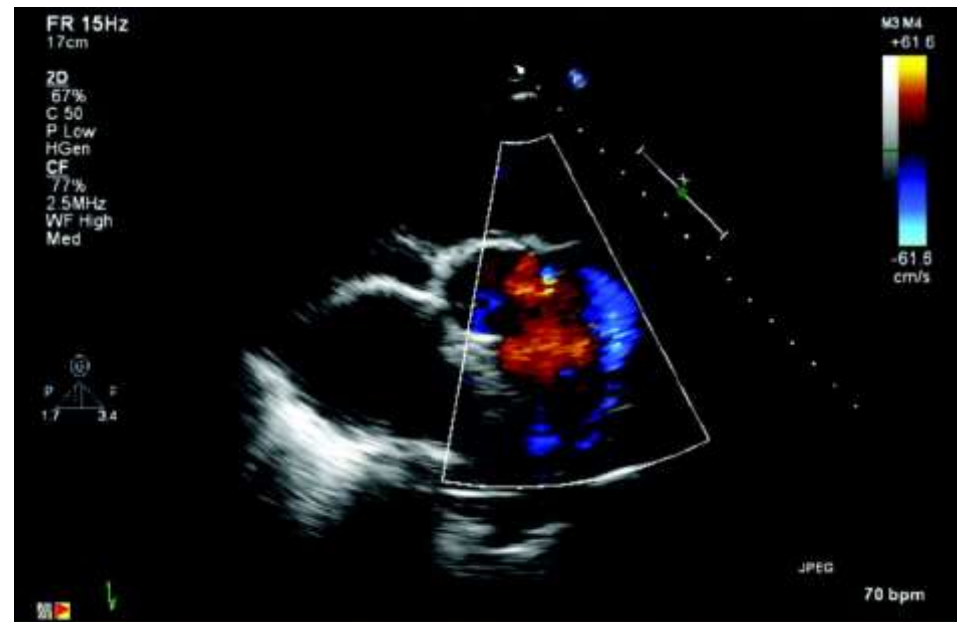
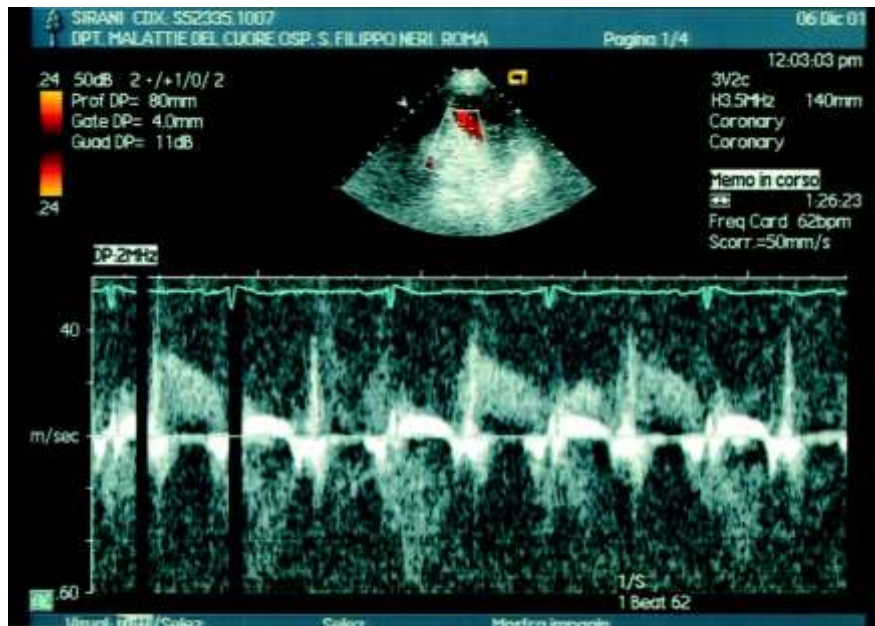
Instrumental methods: Transthoracic echocardiogram (definition & targets)

Transthoracic echocardiogram uses ultrasonic waves for continuous heart chamber and blood movement visualization. In recent times, it has become one of the most commonly used tools in diagnosis of heart problems, as it allows non-invasive visualization of the heart and the blood flow through the heart, using a technique known as Doppler.

Instrumental methods: Transthoracic echocardiogram (device)



Instrumental methods: Transthoracic echocardiogram (results example)

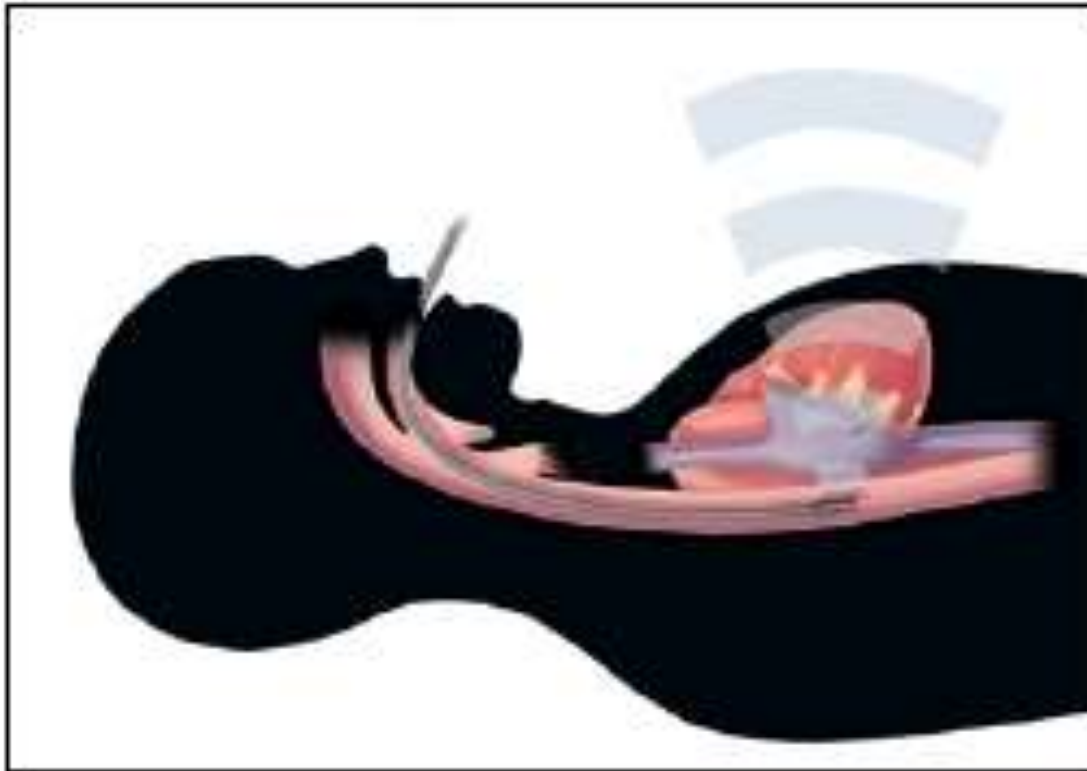

Instrumental methods: Transoesophageal echocardiogram (definition & targets)

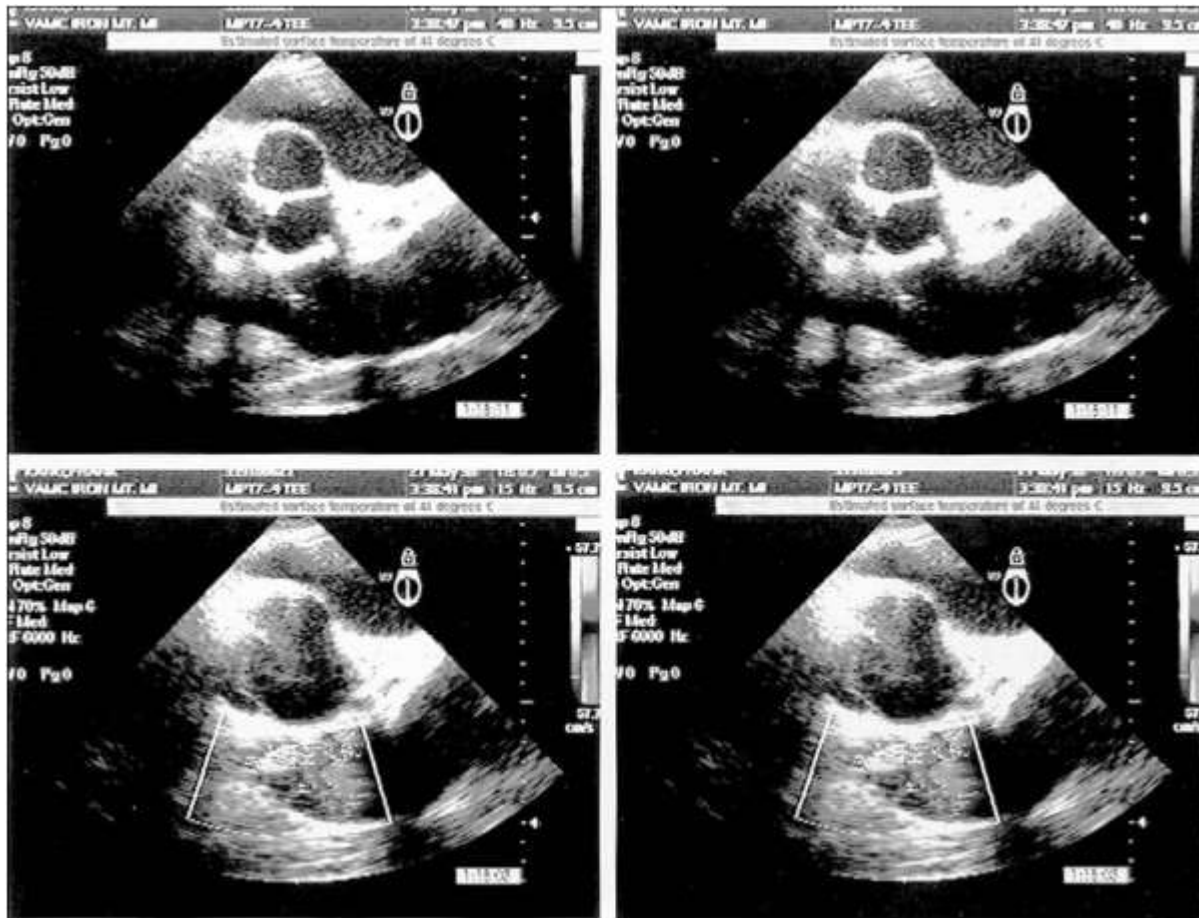
Transoesophageal echocardiogram uses a specialized probe containing an ultrasound transducer at its tip is passed into the patient's esophagus. It is used in diagnosis of various thoracic defects or damage, i.e. heart and lung imaging

Transoesophageal echocardiogram has some advantages and disadvantages over thoracic or intravascular ultrasound

Instrumental methods: Transoesophageal echocardiogram (method)



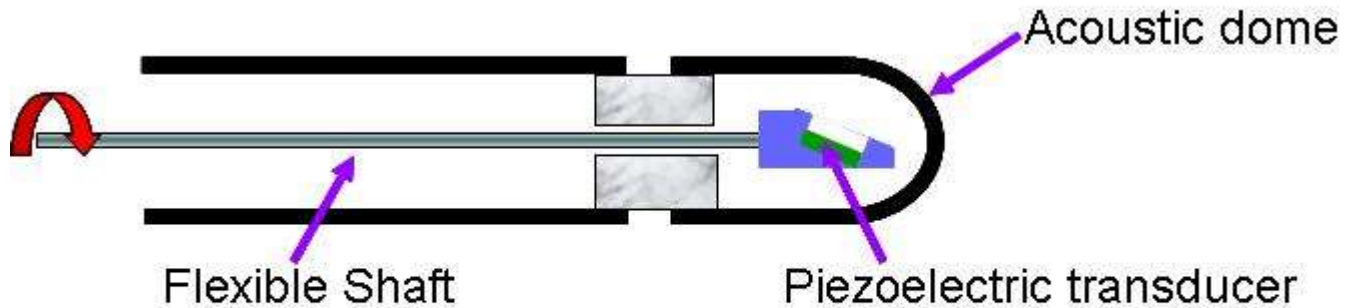
Instrumental methods: Transoesophageal echocardiogram (result example)



Instrumental methods: Intravascular ultrasound (definition & targets)

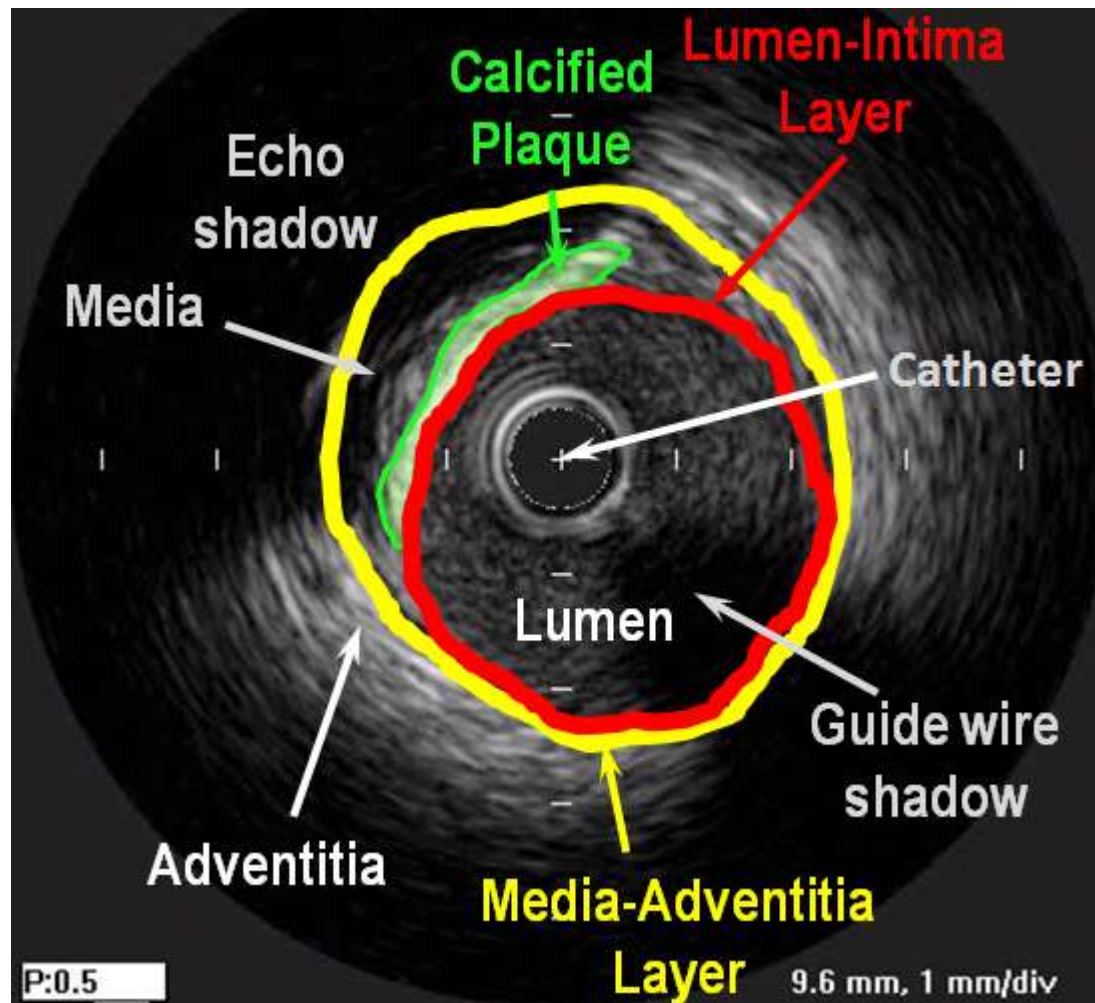
Intravascular ultrasound, also known as a percutaneous echocardiogram is an imaging methodology using specially designed, long, thin, complex manufactured catheters attached to computerized ultrasound equipment to visualize the lumen and the interior wall of blood vessels

Instrumental methods: Intravascular ultrasound (method)



- Principle of intravascular echo element with mechanically rotating element in a catheter

Instrumental methods: Intravascular ultrasound (result example)

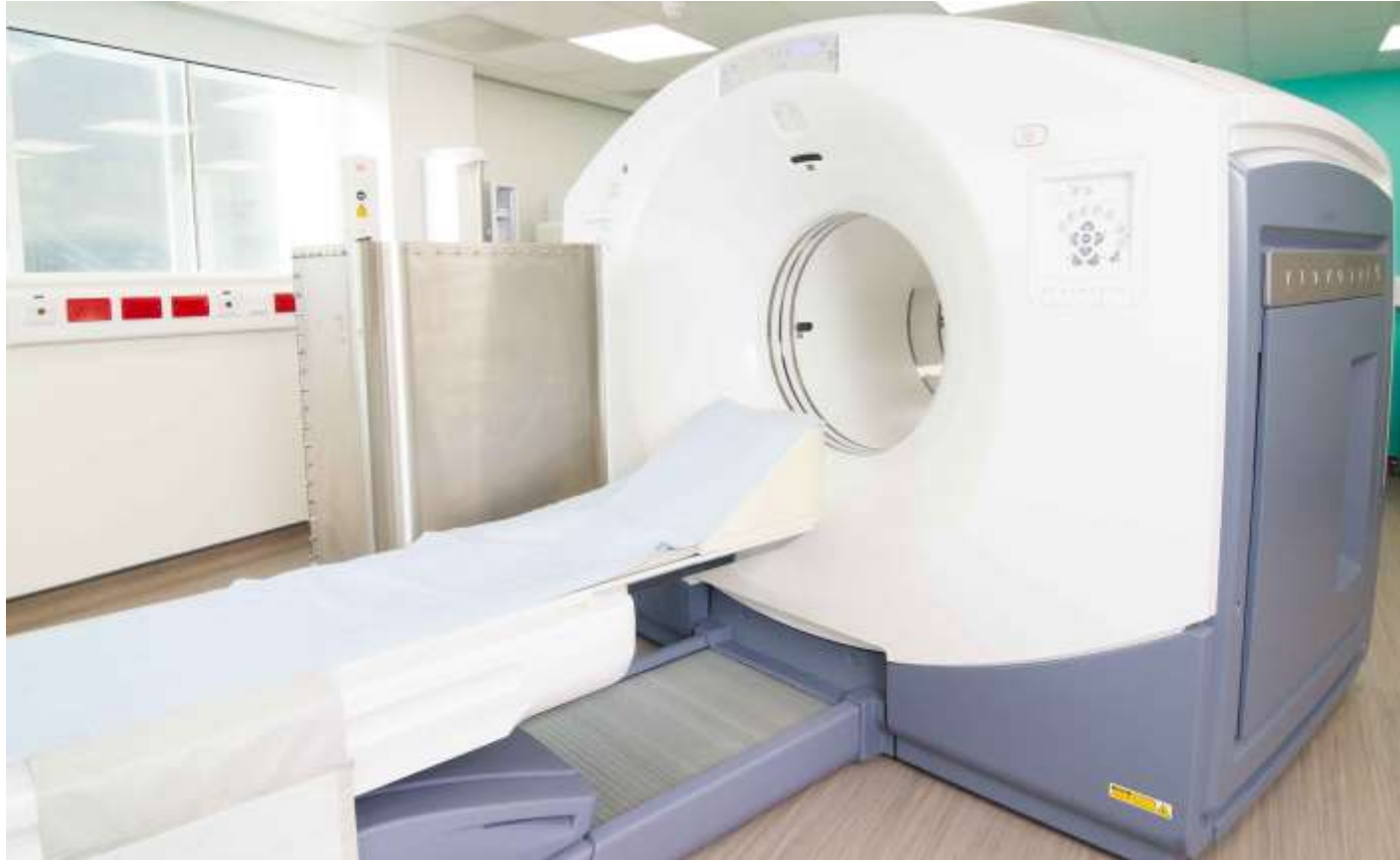

Instrumental methods: Positron emission tomography (definition & targets)

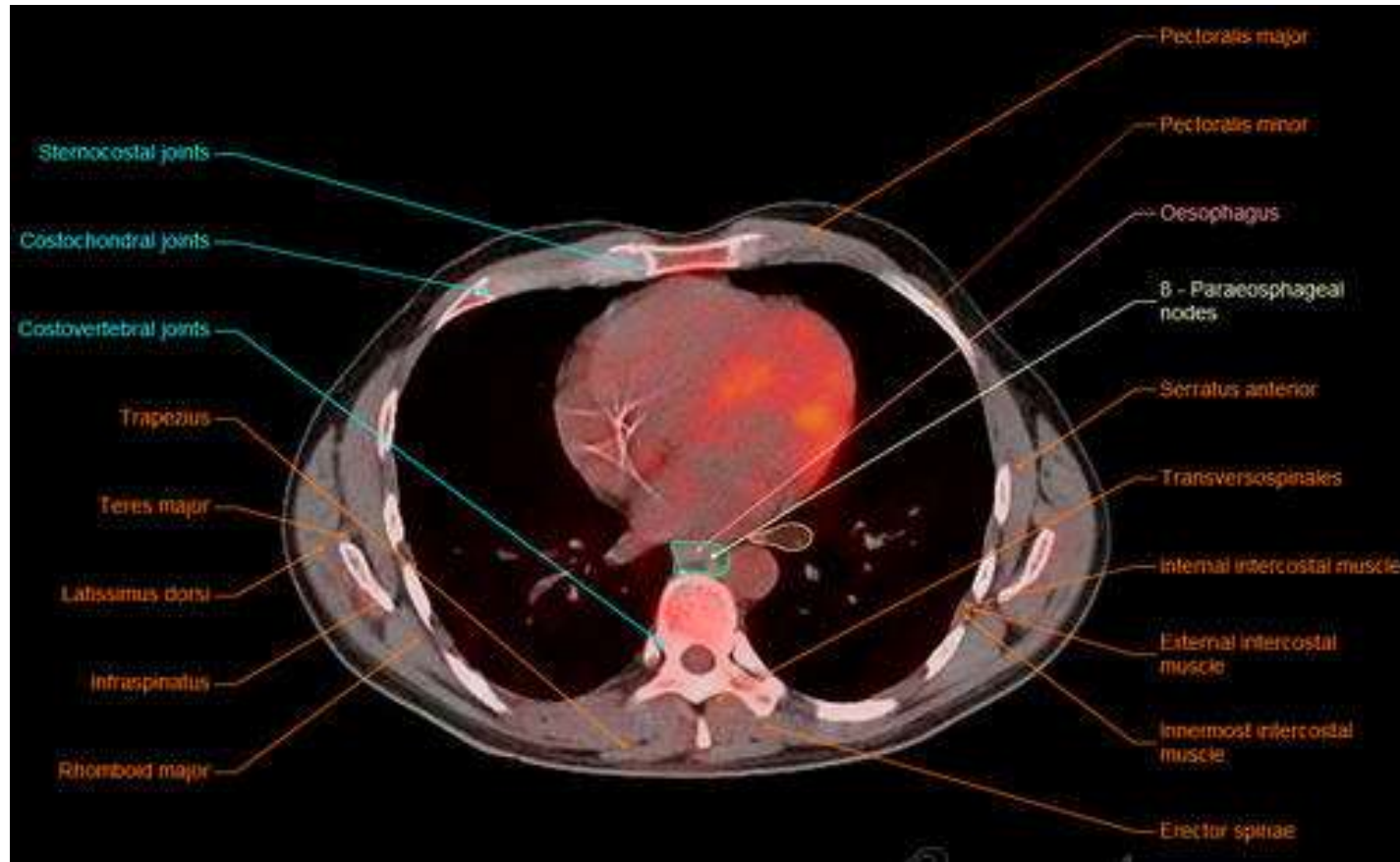
Positron emission tomography (PET), an imaging methodology for positron emitting radioisotopes. PET enables visual image analysis of multiple different metabolic chemical processes and is thus one of the most flexible imaging technologies.

Cardiology uses are growing very slowly due to technical and relative cost difficulties. Most uses are for research, not clinical purposes. Appropriate radioisotopes of elements within chemical compounds of the metabolic pathway being examined are used to make the location of the chemical compounds of interest visible in a PET scanner constructed image.

Instrumental methods: Positron emission tomography (device)



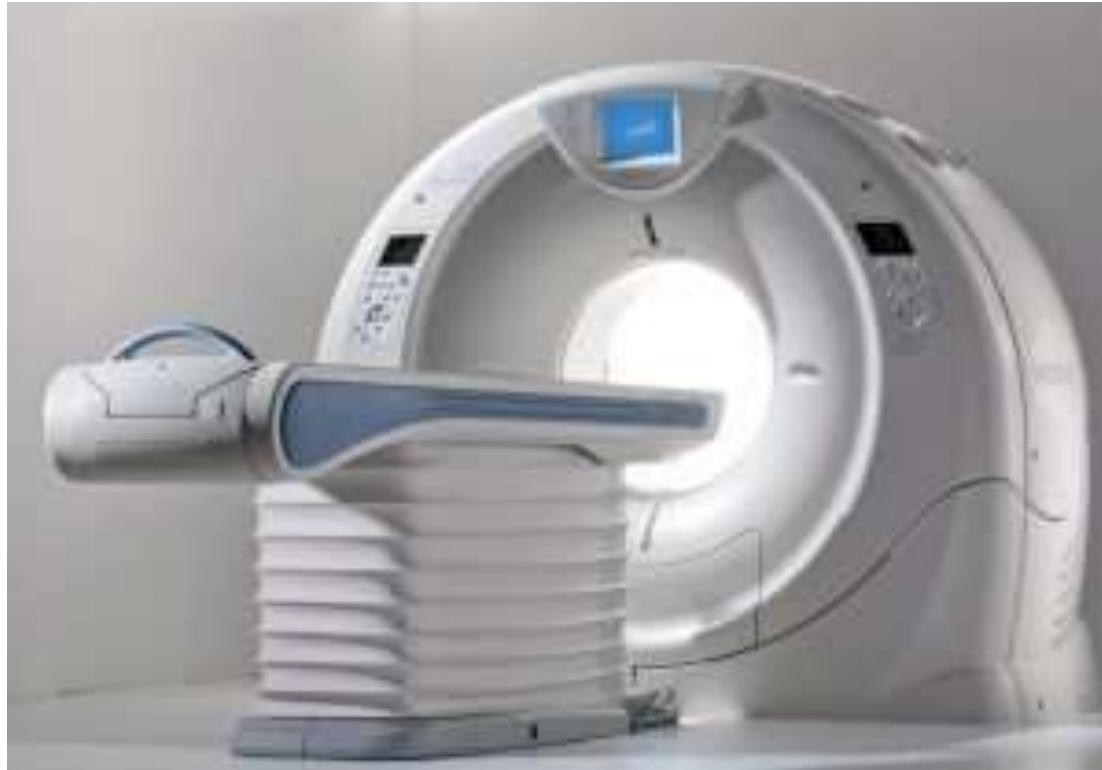Instrumental methods: Positron emission tomography (result example)



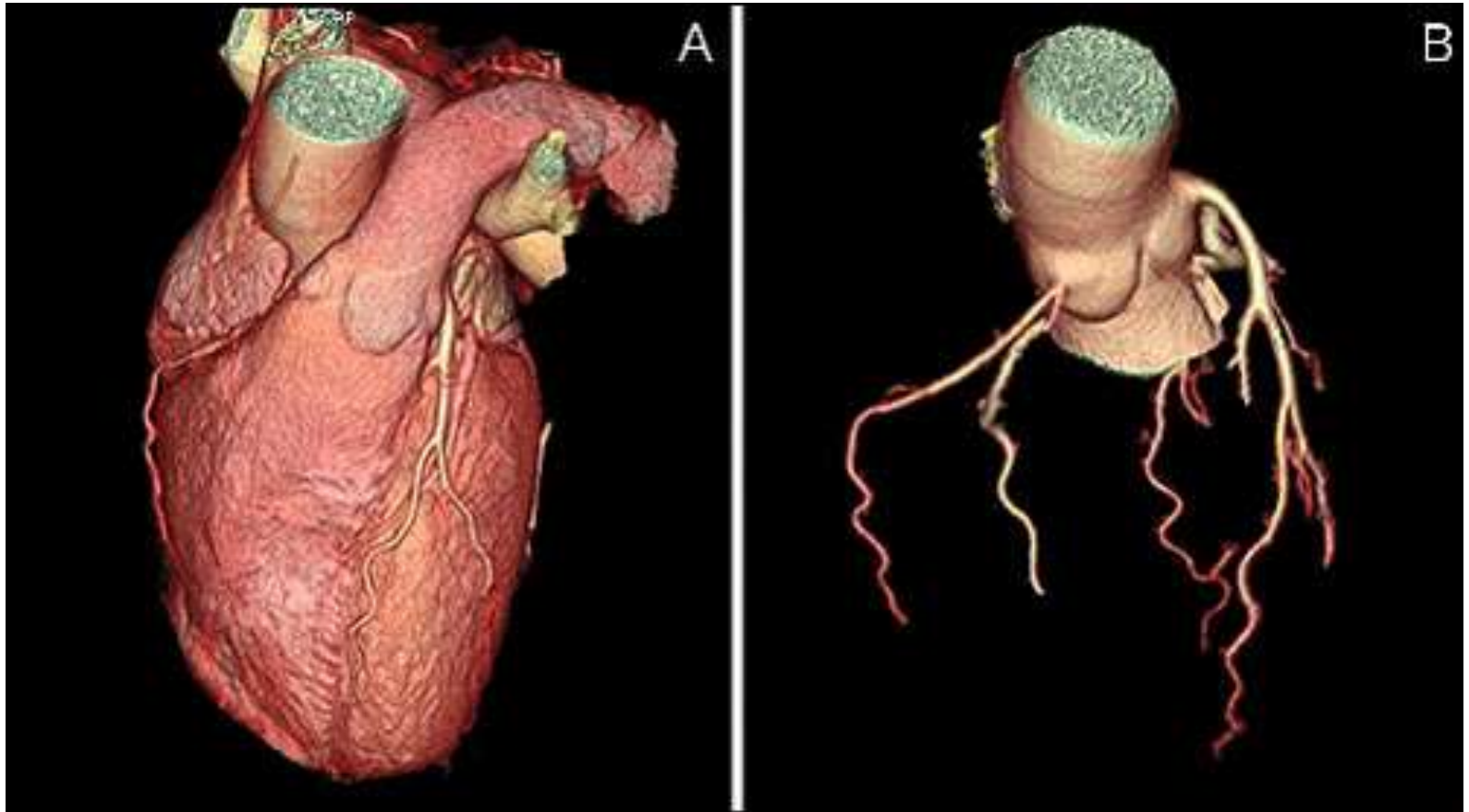
Instrumental methods: Computed tomography angiography (definition & targets)

- Computed tomography angiography (CTA), an imaging methodology using a ring-shaped machine with an X-Ray source spinning around the circular path so as to bathe the inner circle with a uniform and known X-Ray density
- Great development and growth will be seen in the short term, allowing radiologists to diagnose cardiac artery disease without anesthesia and in a non-invasive way

Instrumental methods: Computed tomography angiography (device)



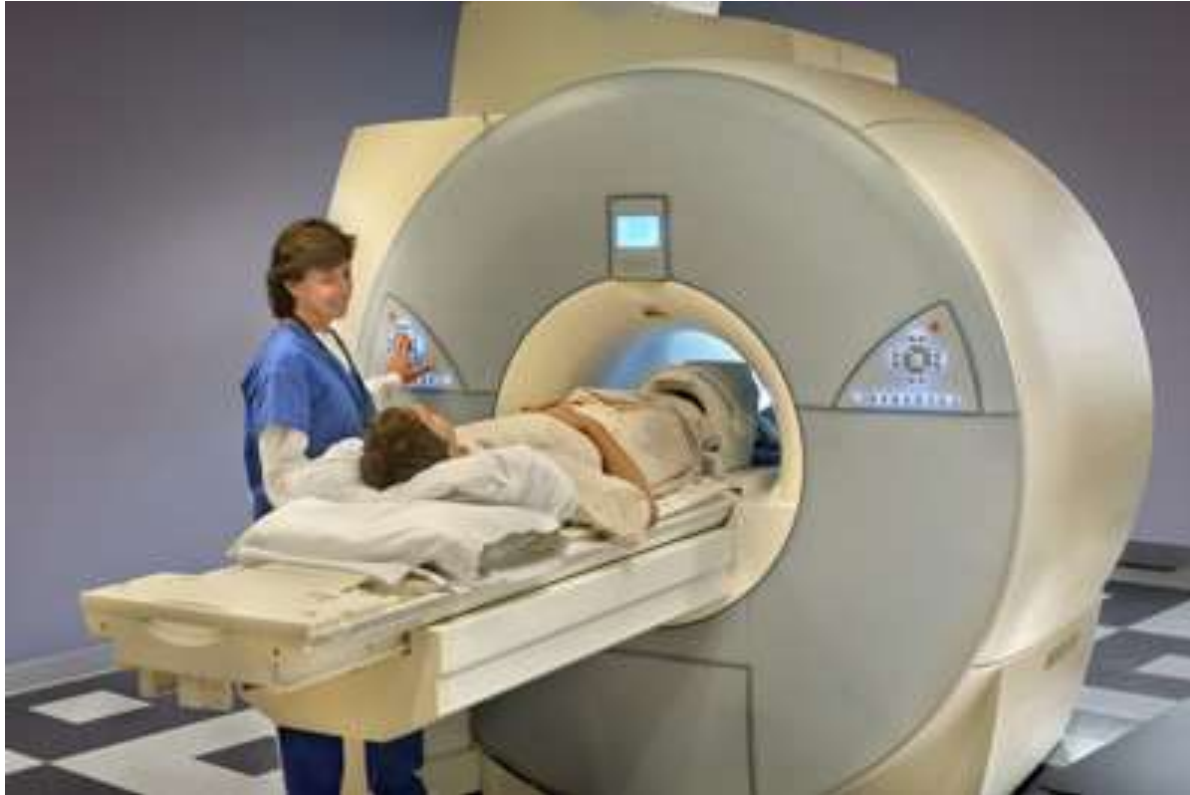Instrumental methods: Magnetic resonance imaging (result example)



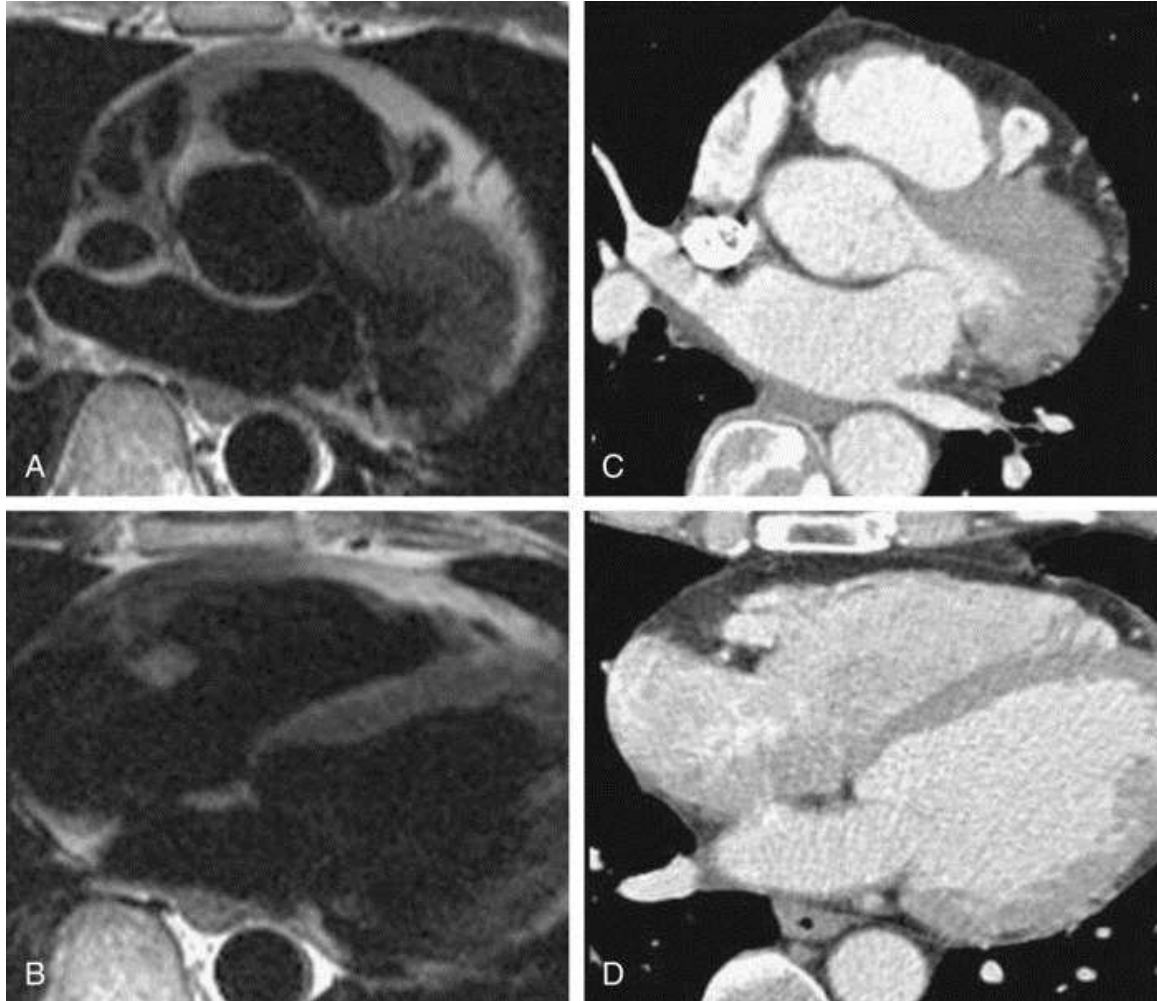
Instrumental methods: Magnetic resonance imaging (definition & targets)

- Magnetic resonance imaging (nuclear magnetic resonance imaging, MRI), an methodology based on aligning the spin axis of nuclei within molecules of the object being visualized using both powerful superconducting magnets and radio frequency signals and detectors
- MRI differentiates soft tissues better than computed tomography and allows for comprehensive exams including the quantitative assessment of size, morphology, function, and tissue characteristics in one single session

Instrumental methods: Magnetic resonance imaging (device)



Instrumental methods: Magnetic resonance imaging (result example)



Instrumental methods: med tech that transform the world

CardioDefender
diagnostic system, a
smartphone ECG that
can provide continuous
readings throughout
the day that can help
detect arrhythmias that
may be hard to spot in
an office visit



Instrumental methods: med tech that transform the world

- Wireless Blood Pressure Monitor
- Easy and precise self-measurement of blood pressure with personal smartphone



Instrumental methods: med tech that transform the world

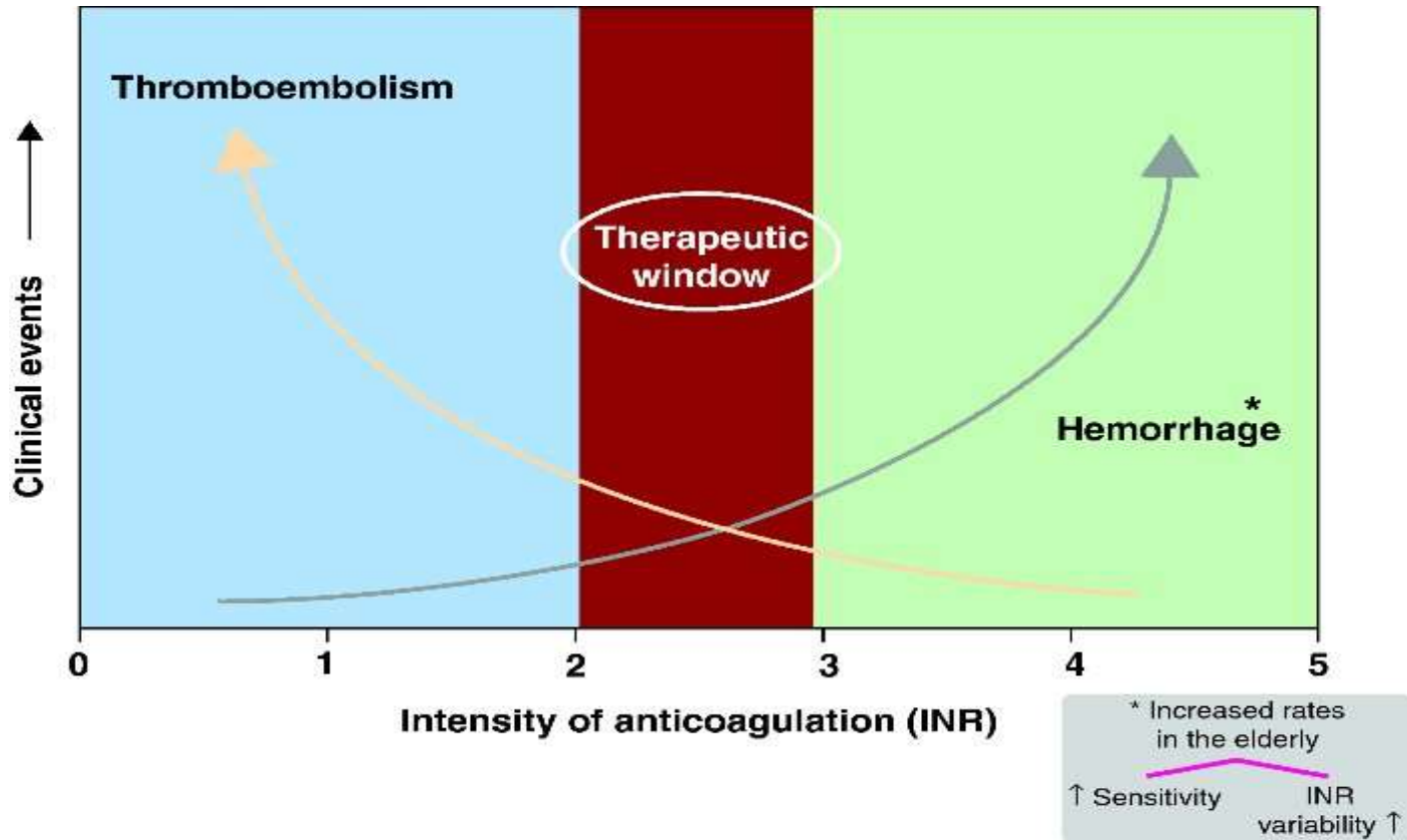
- A health-tracking wristband that could give health care professionals real-time information on the well-being of their patients.
- The wearable can measure a patient's pulse, activity level, skin temperature, heartbeat rhythm, light levels and light exposure



laboratory methods: Ordinary tests kit

- Blood count
- Blood sugar tests
- Blood tests for those taking anticoagulants (Blood thinners)
- Blood tests to determine risk of coronary artery disease
- B-type natriuretic peptide (BNP) blood test
- Electrolytes
- Enzyme & protein blood tests
- Lipid blood tests
- Thyroid blood tests
- Urine Albumin/Creatinine Ratio (Ualb/Cr)

laboratory methods: Blood thinners



- Prothrombin Time (PT): Normal range for an adult: 9.9-13 seconds
- International Normalized Ratio (INR): Normal level for an adult: 0.9 – 1.2

laboratory methods: tests to determine risk of coronary artery disease

- Lipoprotein a (Lp(a)) associated with higher risk of heart attack and stroke, desirable level for adults: less than 30 mg/dL
- Apolipoprotein A1 (Apo A1) is the major protein of HDL, low level is associated with increased risk of early cardiovascular disease, desirable level for adults: more than 123 mg/dL
- Apolipoprotein B (ApoB) found in cholesterol particles, ApoB may be a better overall marker of risk than LDL alone, goal values: less than 100 mg/dL for those with low/intermediate risk, less than 80 mg/dL for high-risk individuals, such as those with cardiovascular disease or diabetes

laboratory methods: B-type natriuretic peptide (BNP) blood test

- "Non-traditional" blood protein made in the heart and found in the blood
- High levels are associated with increased risks of cardiovascular disease, heart attack and heart failure development
- Elevated levels are associated with development of heart failure and worse prognosis
- Goal values: less than 125 pg/mL

laboratory methods: Enzyme & protein blood tests

- Alanine Aminotransferase (ALT; also called SGPT), goal value: 5 – 50 U/L
- Aspartate Aminotransferase (AST; SGOT), goal value: 7 – 40 U/L
- Creatinine (Cr), goal value: 0.7 – 1.4 mg/dL
- Creatine Kinase (CK), goal value: 30 – 220 U/L
- Lactate dehydrogenase (LDH), goal value: 100 - 220 U/L
- Myoglobin (Mb), goal value: 30 – 90 µg/mL
- Troponin T (cTNT), goal value: 0.0 - 0.10 µg/mL

laboratory methods: Lipid blood tests

- Total cholesterol. A high level can put you at increased risk of heart disease. Ideally, total cholesterol should be below 200 milligrams per deciliter (mg/dL), or 5.2 millimoles per liter (mmol/L)
- Low-density lipoprotein (LDL) cholesterol. Too much of it in blood causes the accumulation of fatty deposits (plaques) in arteries (atherosclerosis). Ideally, your LDL cholesterol level should be less than 130 mg/dL (3.4 mmol/L), and under 100 mg/dL (2.6 mmol/L) is even better
- High-density lipoprotein (HDL) cholesterol. Ideally, your HDL cholesterol level should be 60 mg/dL (1.6 mmol/L) or higher, though it's common that HDL cholesterol is higher in women than men.
- Triglycerides. High levels increase risk of heart disease. Ideally, triglyceride level should be less than 150 mg/dL (1.7 mmol/L)

laboratory methods: C-reactive protein

- CRP is a sign of inflammation somewhere in the body
- Inflammation plays a central role in the process of atherosclerosis, in which fatty deposits clog arteries
- CRP test result can be interpreted as putting heart disease risk at:
 - Low risk (less than 1.0 milligrams per liter, or mg/L)
 - Average risk (1.0 to 3.0 mg/L)
 - High risk (above 3.0 mg/L)

laboratory methods: Thyroid blood tests

- Thyroid Stimulating Hormone (TSH), normal range for an adult: 0.4 – 5.5 mU/mL
- Thyroxine (T4), normal range for an adult: 5 – 11 µg/dL
- Microsomal Thyroid Antibodies (TPO), desirable level for an adult: 0.0 - 5.0 IU/mL

laboratory methods: Urine Albumin/Creatinine Ratio (Ualb/Cr)

- Albumin is a protein found in urine (Ualb) that can be a sign of increased risk for kidney disease, diabetes complications and cardiovascular risks
- If elevated levels of Ualb/CR are present, close attention to blood pressure control, including use of specific blood pressure medications that help protect the kidney, may be recommended
- Goal values: more than 30 mg/g indicates increased risk for CVD and diabetic nephropathy and more than 300 mg/g indicates clinical nephropathy

Glossary of Patients Examination with Diseases of the Cardiovascular System' terms

Cardiovascular Terminology Glossary