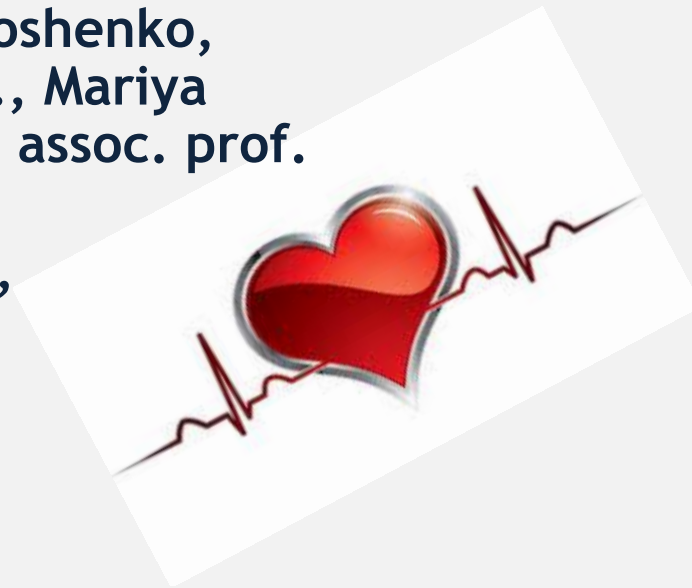

# ECG basics. Normal ECG. Steps of ECG interpretation with introduction to ECG pathological patterns.

Eugenia Golubkina, ass. prof., Olena Timoshenko,  
ass. prof., Olena Kanishcheva, ass. prof., Mariya  
Brynza, assoc. prof., Olena Makharynska, assoc. prof.  
Department of Internal Medicine  
V. N. Karazin Kharkiv National University,  
Kharkiv, Ukraine



# Introduction

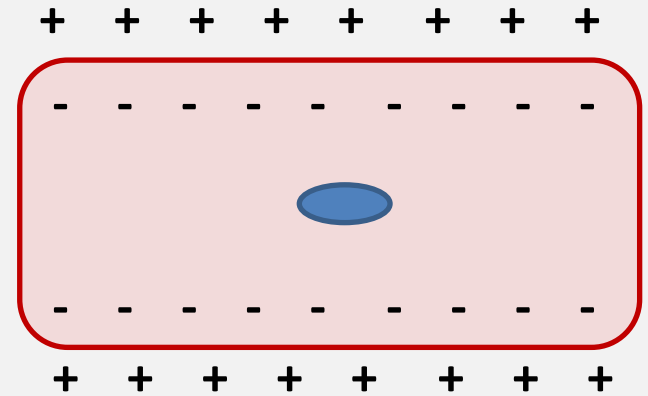


- The ECG is a recording of the electrical activity of the heart.
- Each heart beat consists of one complete cycle of cardiac contraction and relaxation that begins when the sinus node (SA node) depolarizes spontaneously.
- Contraction is provided by mechanism of depolarization of cardiac cells, relaxation - by mechanism of repolarization.
- Thus cardiac cells can be in two states - resting state and depolarized state

# Resting state of cardiac cells



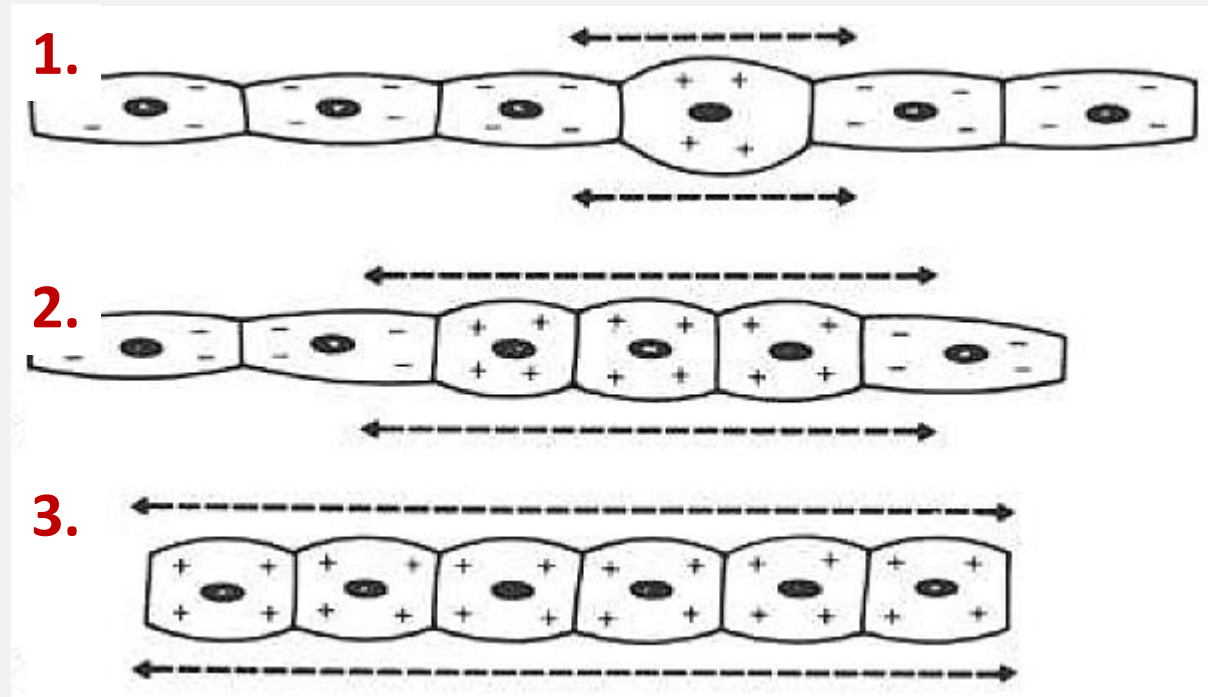
- Cardiac cells, in their resting state, are electrically polarized, their insides are negatively charged, while outsides are charged positively.
- This electrical polarity is maintained by membrane pumps that ensure the appropriate distribution of ions (primarily potassium, sodium, chloride, and calcium) necessary to keep the insides of these cells relatively electronegative.



# Depolarization of cardiac cells



- Depolarization is the process when the cardiac cell loses its internal negativity by changing the charge.
- Depolarization is propagated from cell to cell, producing a wave of depolarization that can be transmitted across the entire heart.



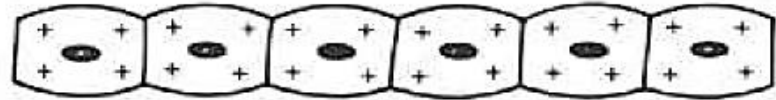
1. Depolarization of a single cell
2. Wave of depolarization from cell to cell
3. All the cells are depolarized

# Repolarization of cardiac cells

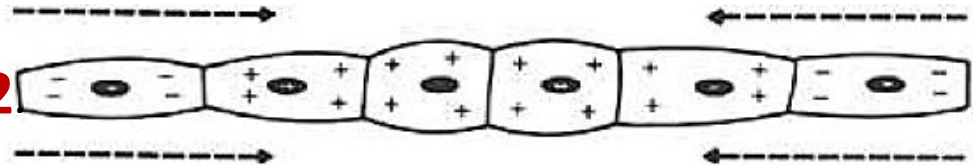


- After depolarization is complete, the cardiac cells are able to restore their resting polarity through a process called repolarization.
- An electrical tracing obtained after record one electrical cycle of depolarization and repolarization from a single cell is called an action potential.

1.



2.

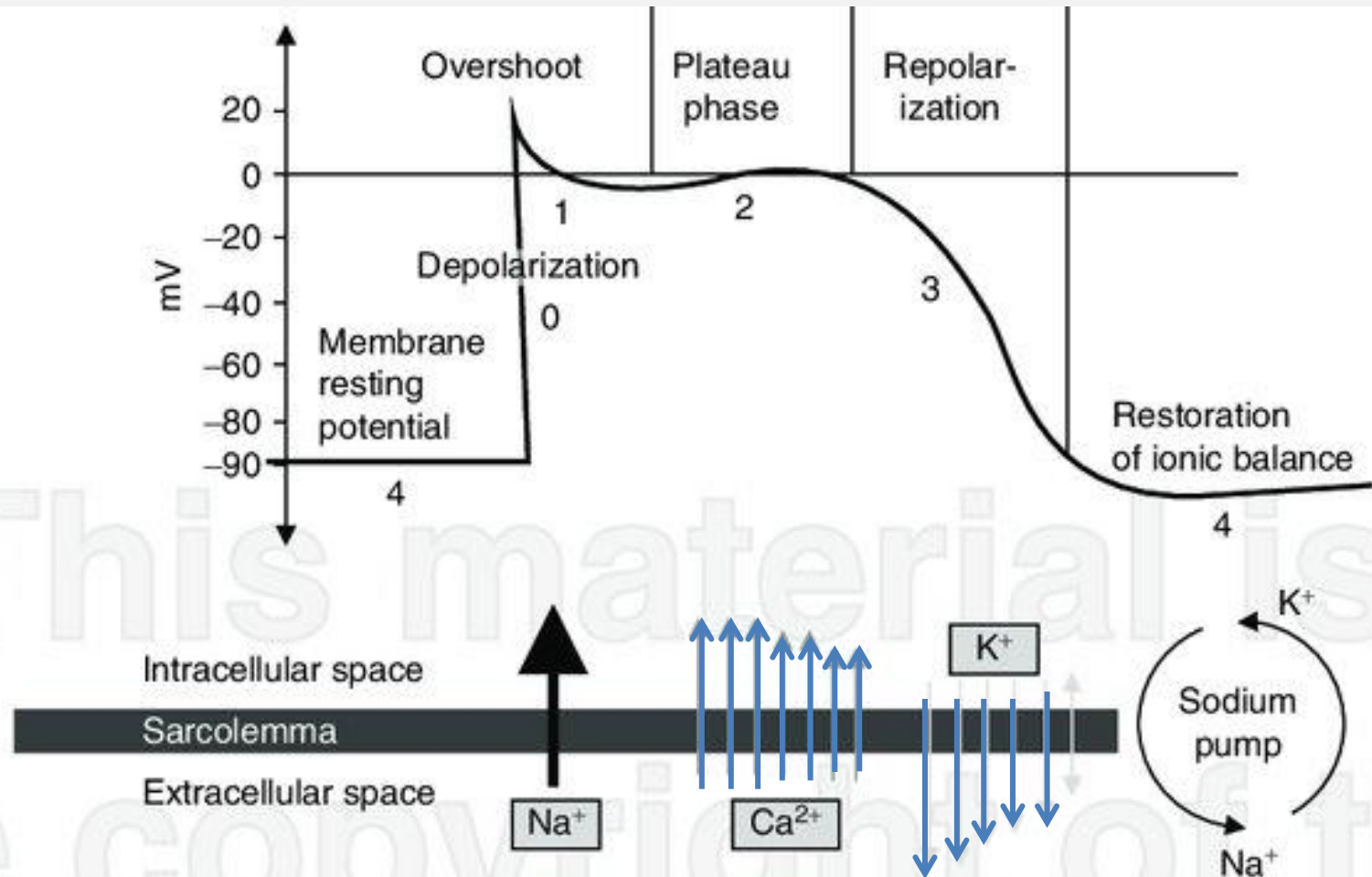


3.



1. Cells are depolarized.
2. Repolarization started.
3. All cells are in the resting stage

# Myocardial action potential

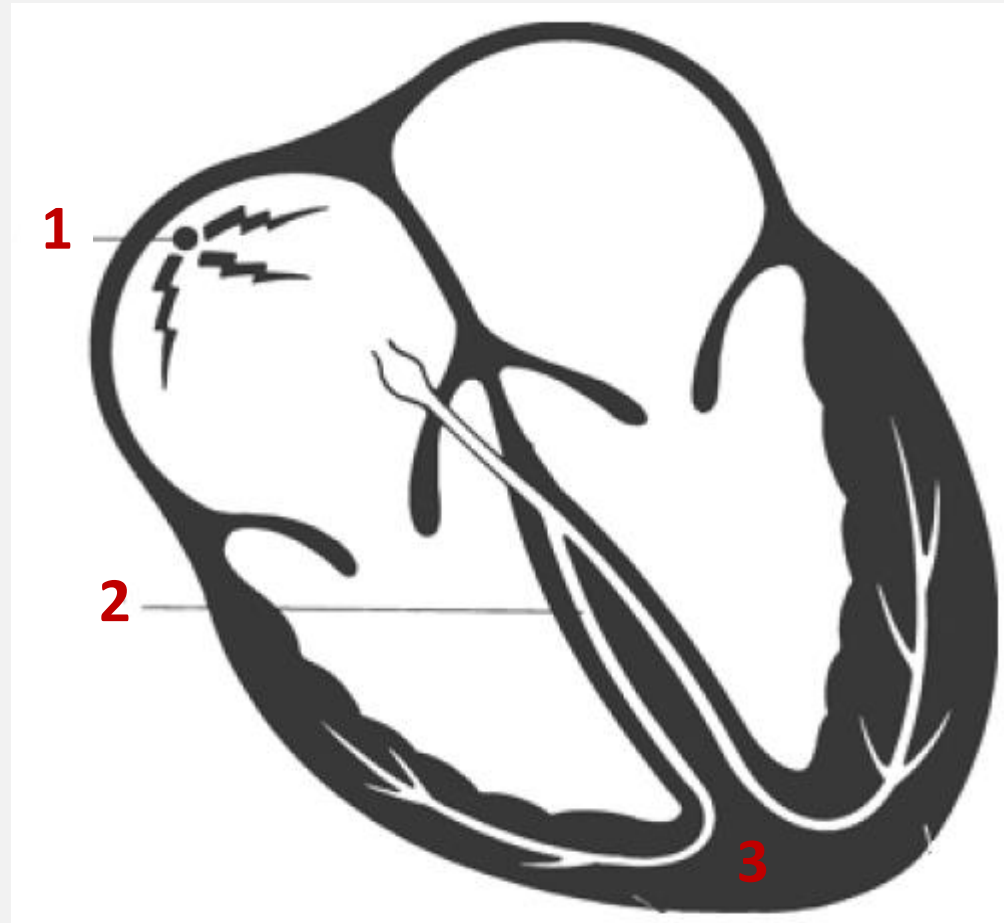


# The cells of the heart



The heart consists of three types of cells:

1. Pacemaker cells—the normal electrical power source of the heart
2. Electrical conducting cells—the wiring of the heart
3. Myocardial cells—the contractile machinery of the heart.



# Pacemaker cells

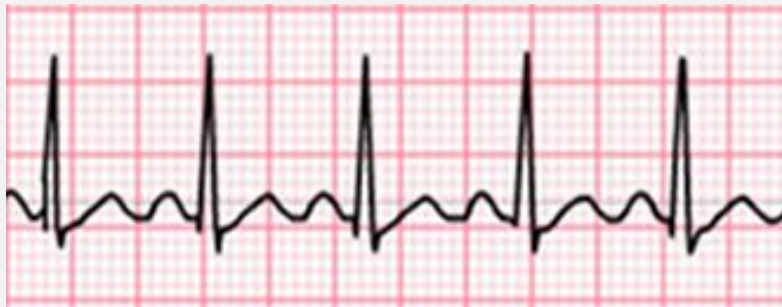

- Pacemaker cells are located in the upper part of the right atrium and able to depolarize spontaneously at a particular rate (normally at 60 to 100 times per minute).
- The rate of depolarization is determined by the innate electrical characteristics of the cell and by influence of autonomous nervous system and hormonal status.
- Each spontaneous depolarization serves as the source of a wave of depolarization that initiates one complete cycle of cardiac contraction and relaxation.

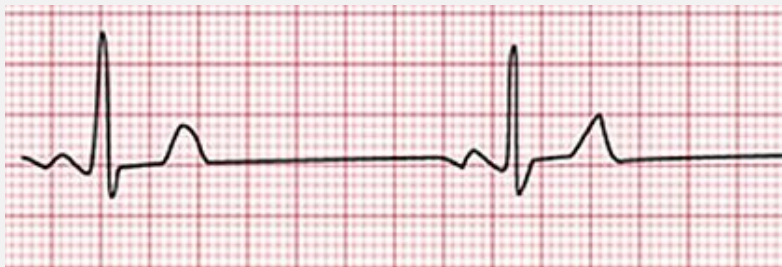**NB!** Every cell in the heart actually has the ability to behave like a pacemaker cell. But this ability normally is suppressed unless the dominant cells of the sinus node fail or if something in the internal or external environment of a cell (sympathetic stimulation, cardiac disease, etc.) stimulates its automatic behavior.



# Autonomous nervous system vs sinoatrial node (SA node)



**Activation of sympathetic nervous system accelerates the SA node**



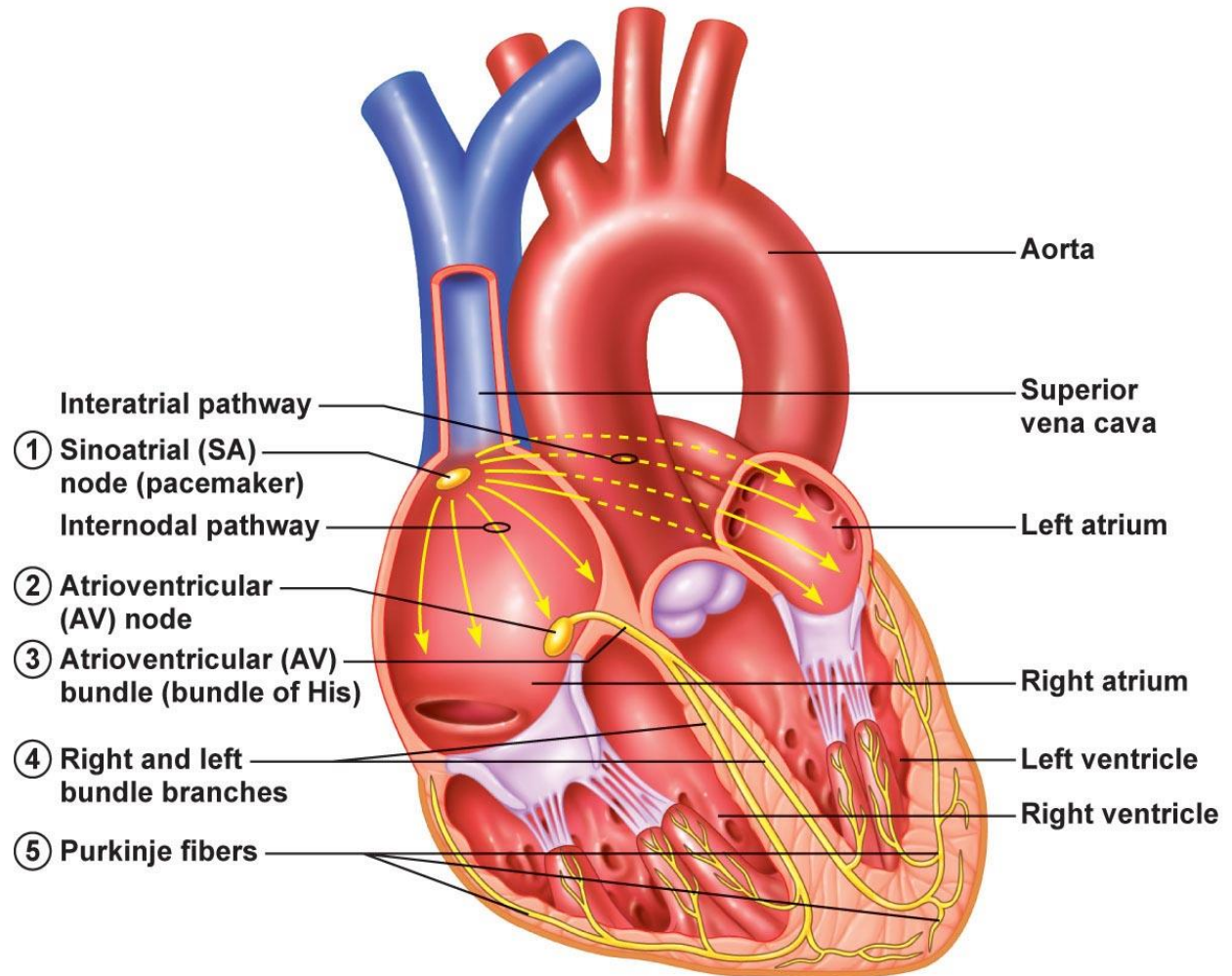
**Activation of parasympathetic nervous system slows the SA node**



# Conducting cells



These cells carry current to distant regions of the heart.



# Bundle of His



The bundle of His into right and left bundle branches. The right bundle branch carries the current down the right side of the interventricular septum all the way to the apex of the right ventricle.

Left bundle branch divides into three major fascicles:

- Septal fascicle, which depolarizes the interventricular septum in a left-to-right direction
- Anterior fascicle, which runs along the anterior surface of the left ventricle
- Posterior fascicle, which sweeps over the posterior surface of the left ventricle.

# Myocardial cells



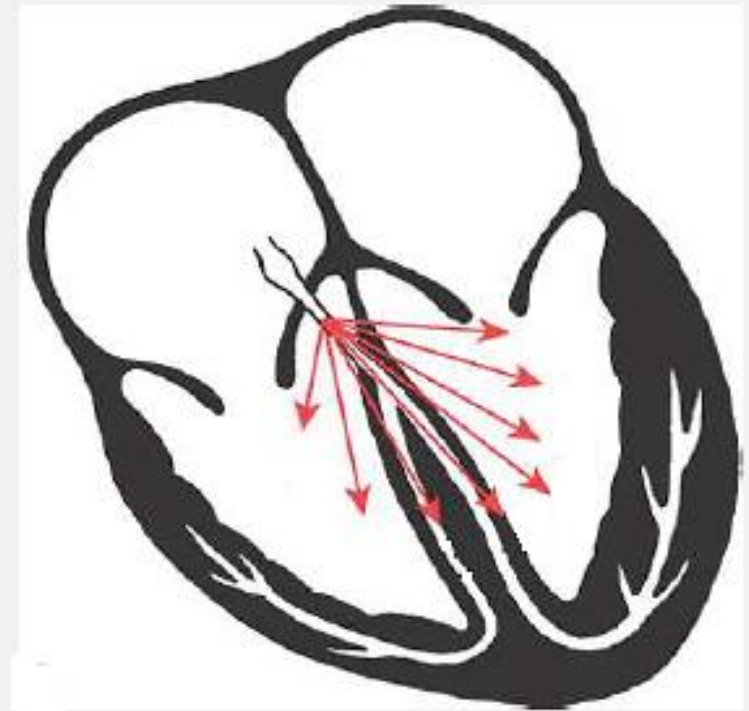
- The myocardial cells constitute the major part of the heart tissue. They are responsible for the contracting and relaxing.
- They contain contractile proteins actin and myosin.
- When a wave of depolarization reaches a myocardial cell, calcium is released within the cell, allows actin and myosin to interact, causing the cell to contract. This process is called excitation-contraction coupling.
- Myocardial cells can transmit an electrical current just like electrical conducting cells, but they do it far less efficiently. Thus, a wave of depolarization, upon reaching the myocardial cells, will spread slowly across the entire myocardium.



# Mean electrical vector of the heart



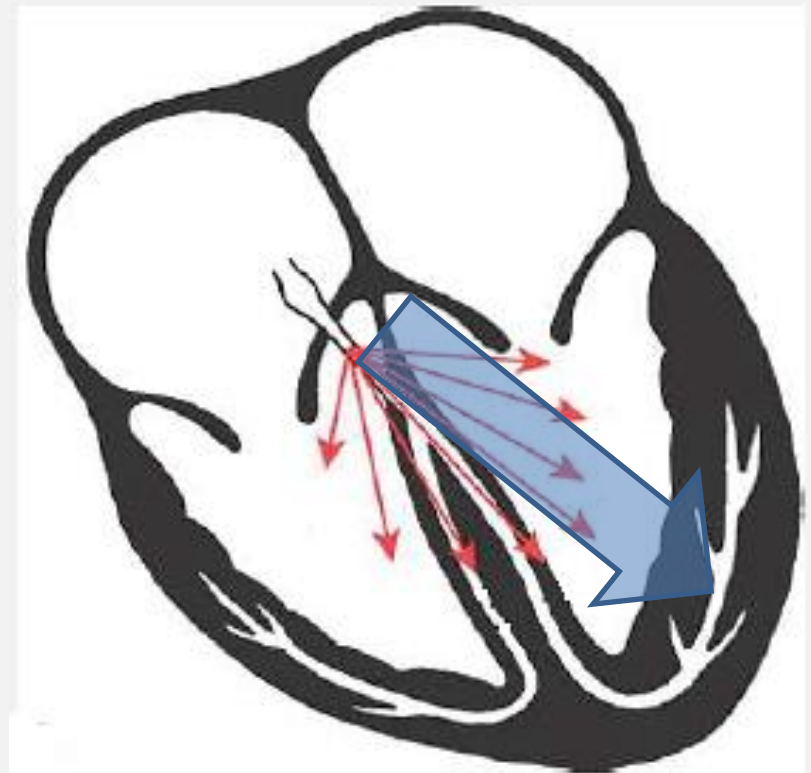
- When the ventricles undergo depolarization, the wave of depolarization that spreads across the muscle mass occurs in many different directions simultaneously (**red arrows**).
- The vectors swing progressively leftward because the electrical activity of the much larger left ventricle increasingly dominates.



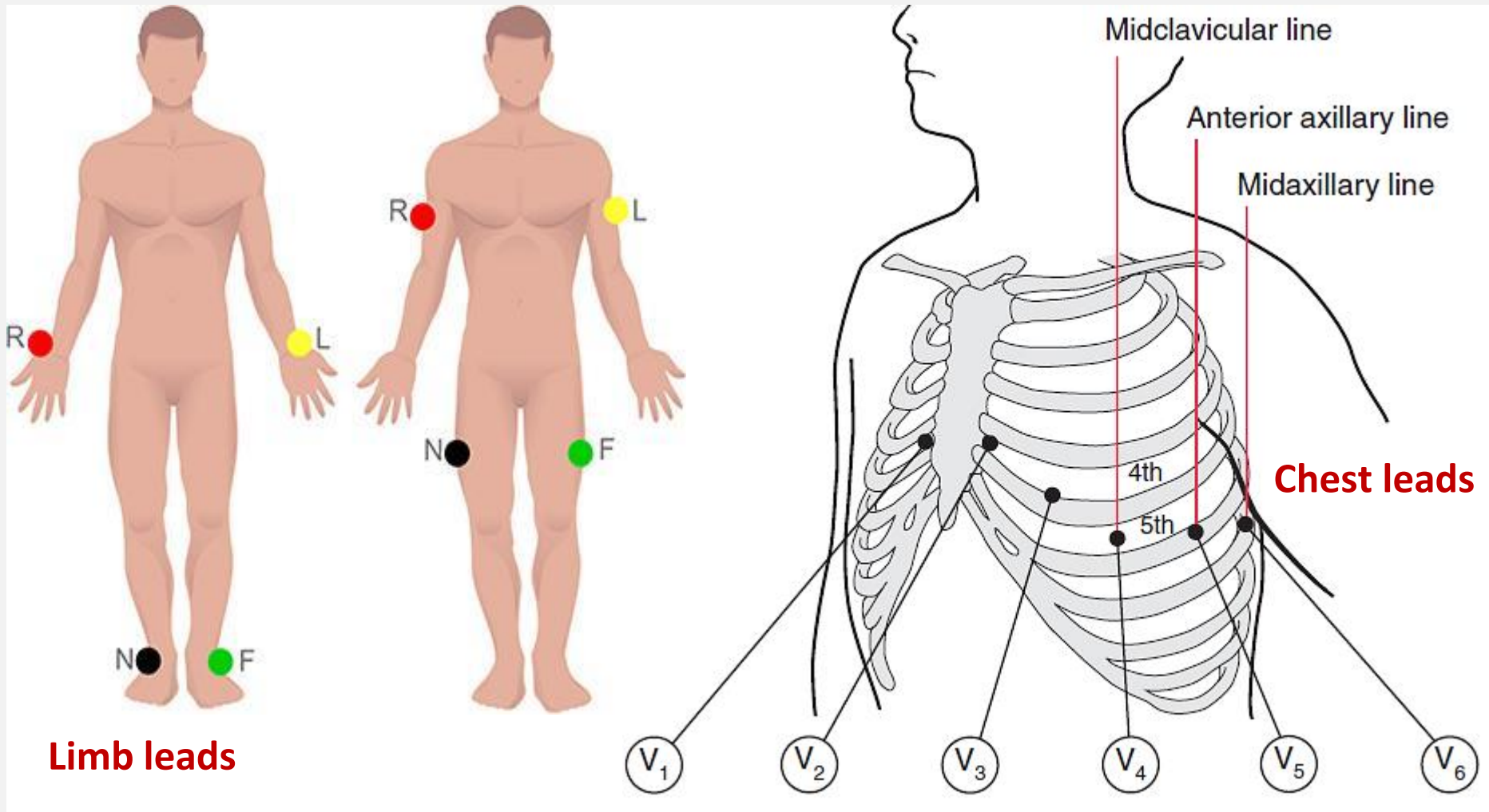
# Mean electrical vector of the heart



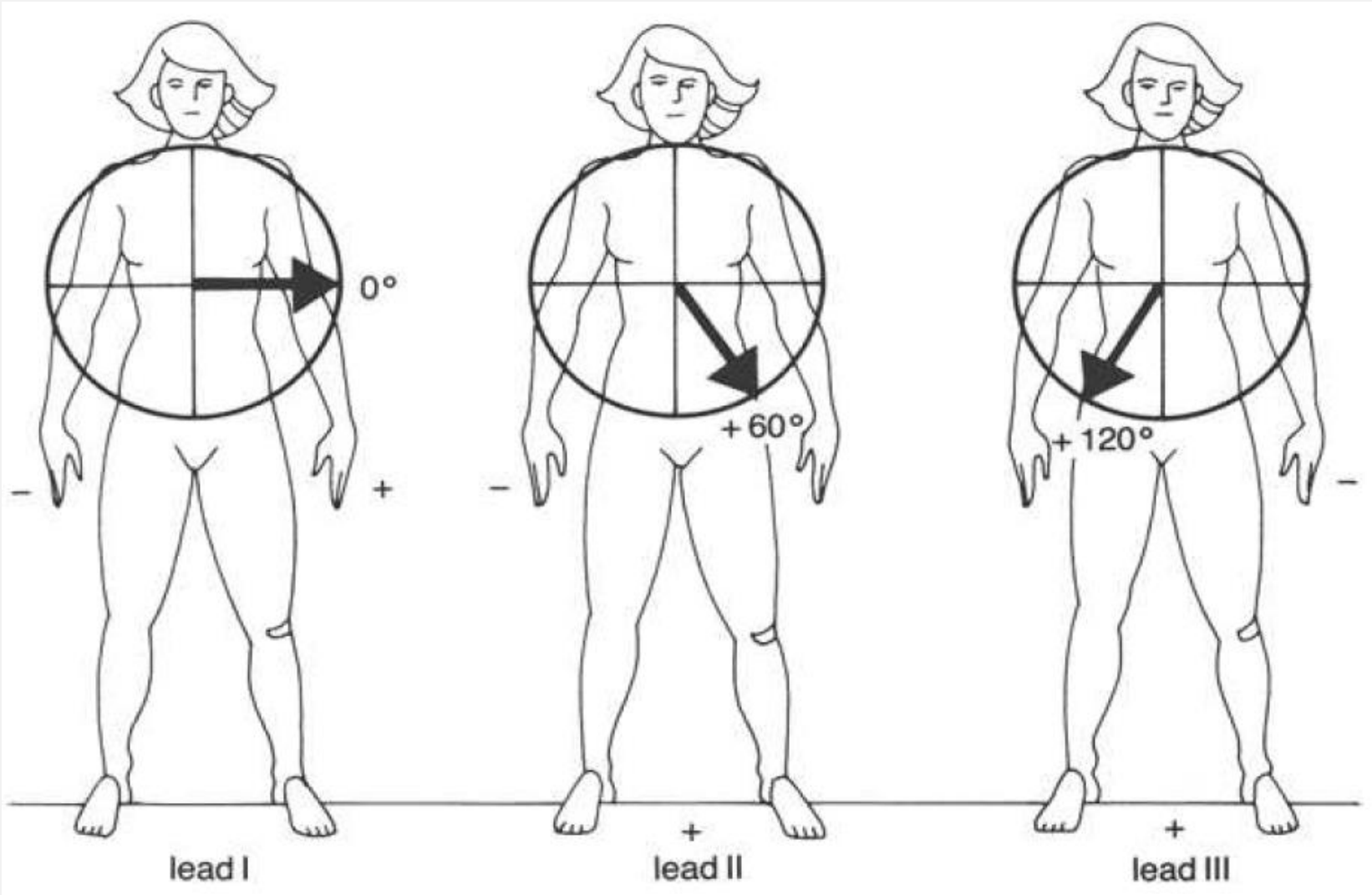
- The average vector of all of the instantaneous vectors is called the mean electrical vector (blue arrow) and normally points leftward and inferiorly.
- The direction of the mean vector is called the electrical axis of the heart or the QRS axis.
- The axis of the P wave and T wave also can be defined.



# ECG recording: electrodes placing

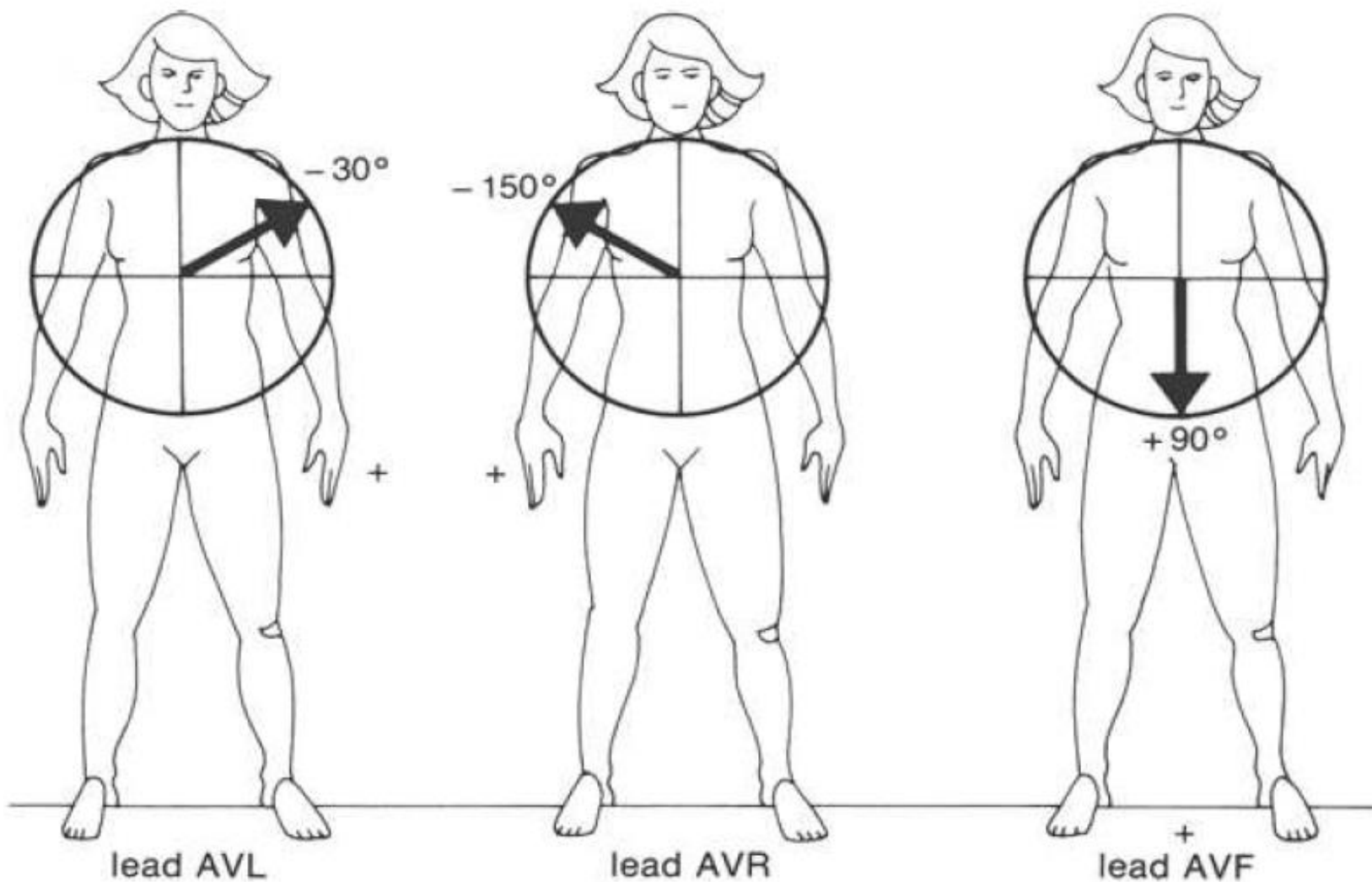


# Limb leads

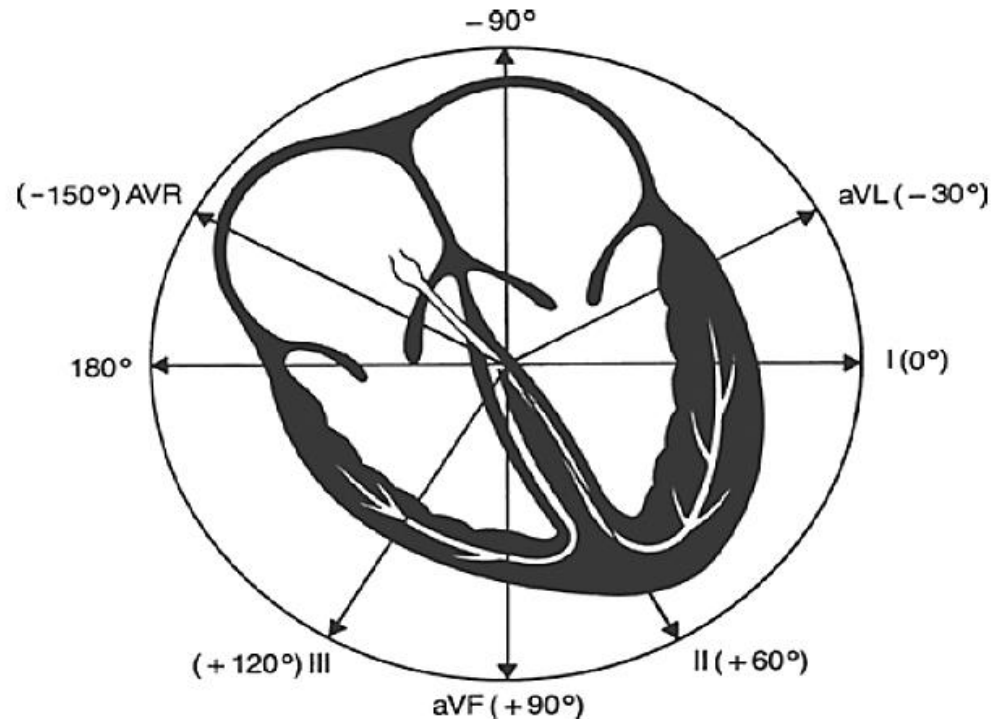
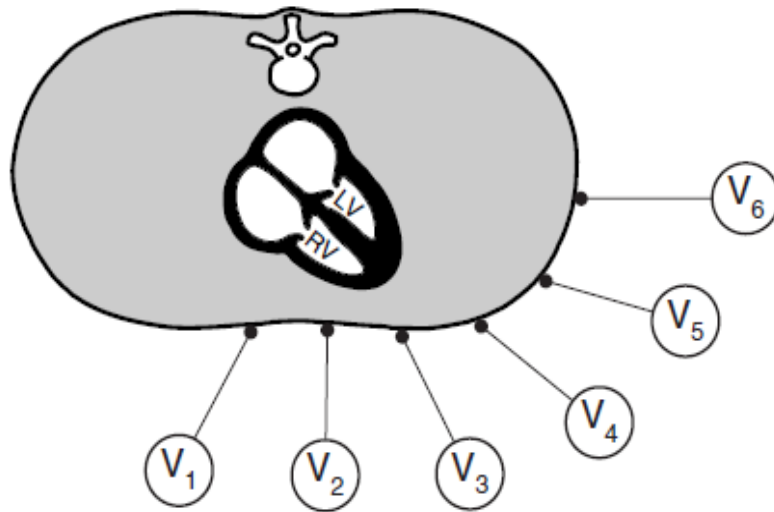




# Augmented limb leads

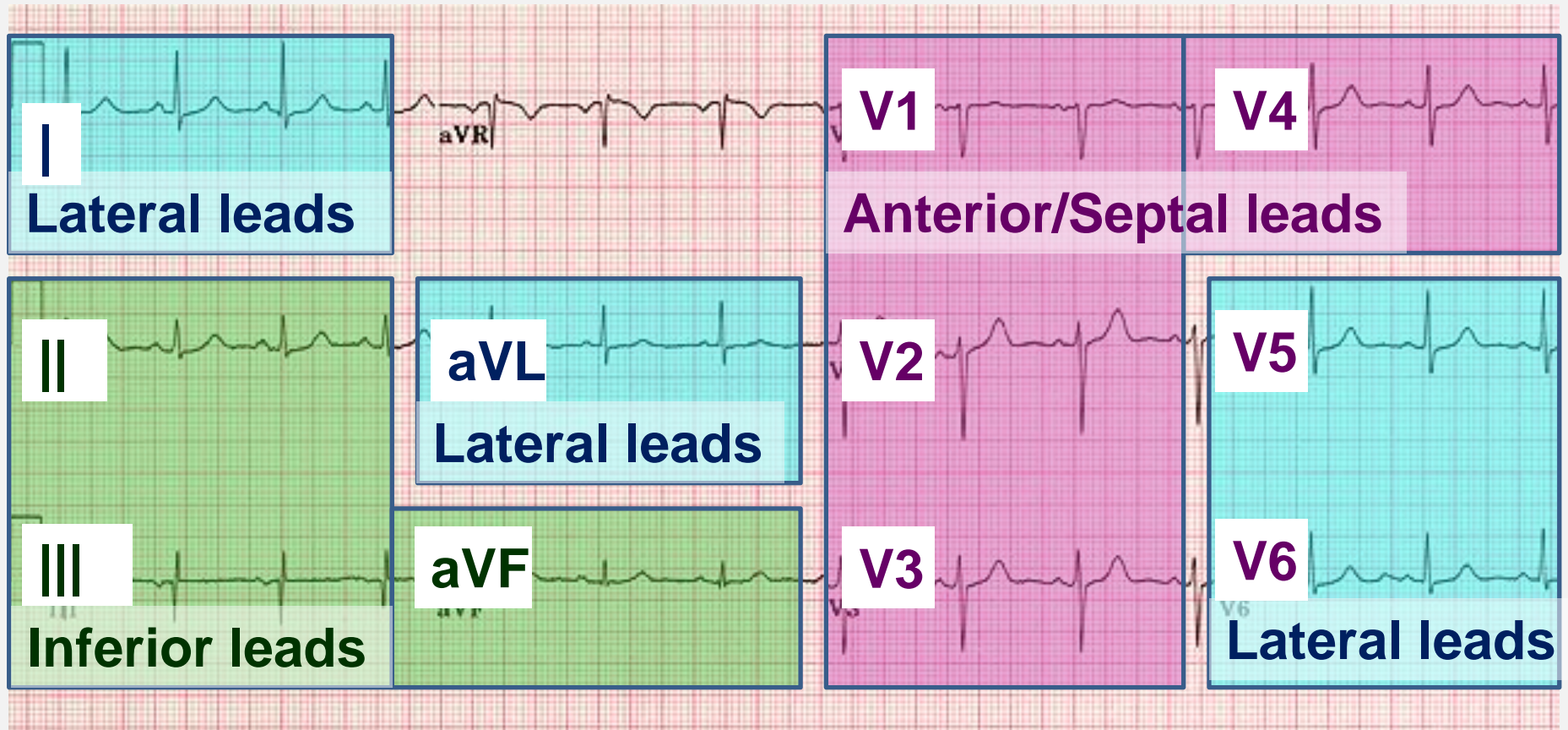


# Leads and its angles



- Leads V1, V2 - septal leads, V3, V4 - anterior leads
- Leads II, III, and AVF - inferior leads;
- Leads I, AVL, V5, V6 - lateral leads;
- AVR;

# ECG leads



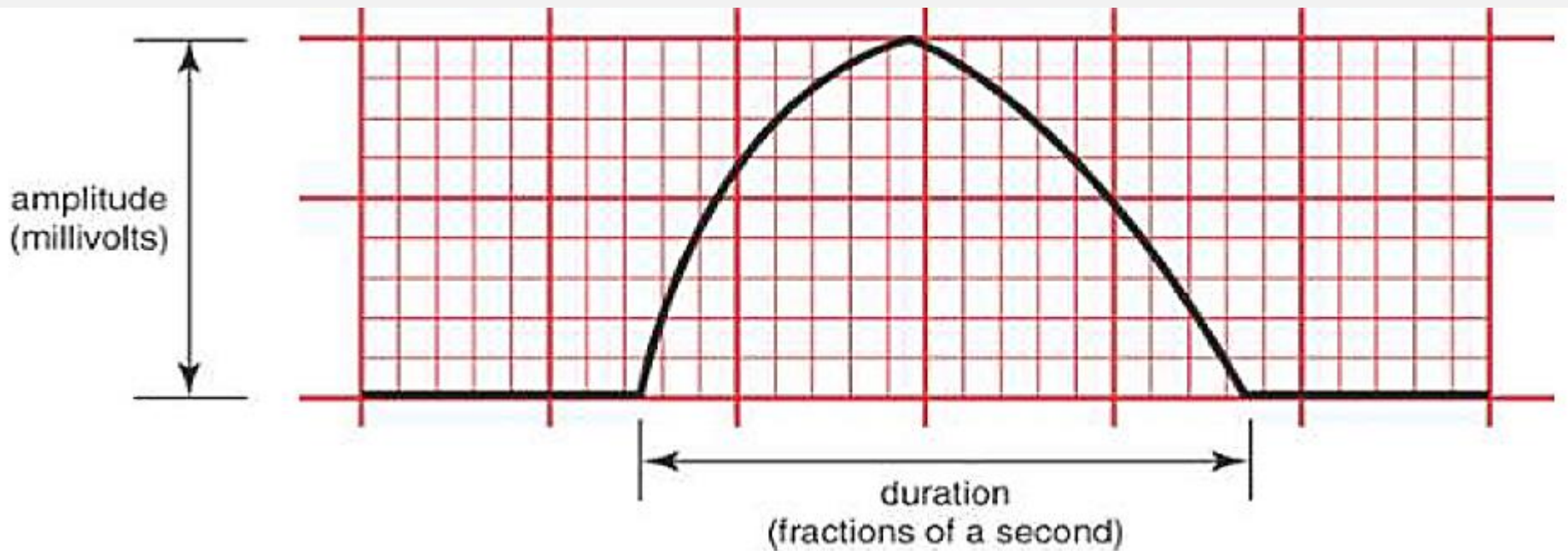


# ECG waves' characteristics



## Main characteristics:

- Duration, measured in fractions of a second
- Amplitude, measured in millivolts (mV)
- Configuration (shape and appearance of a wave).



# Segments vs intervals

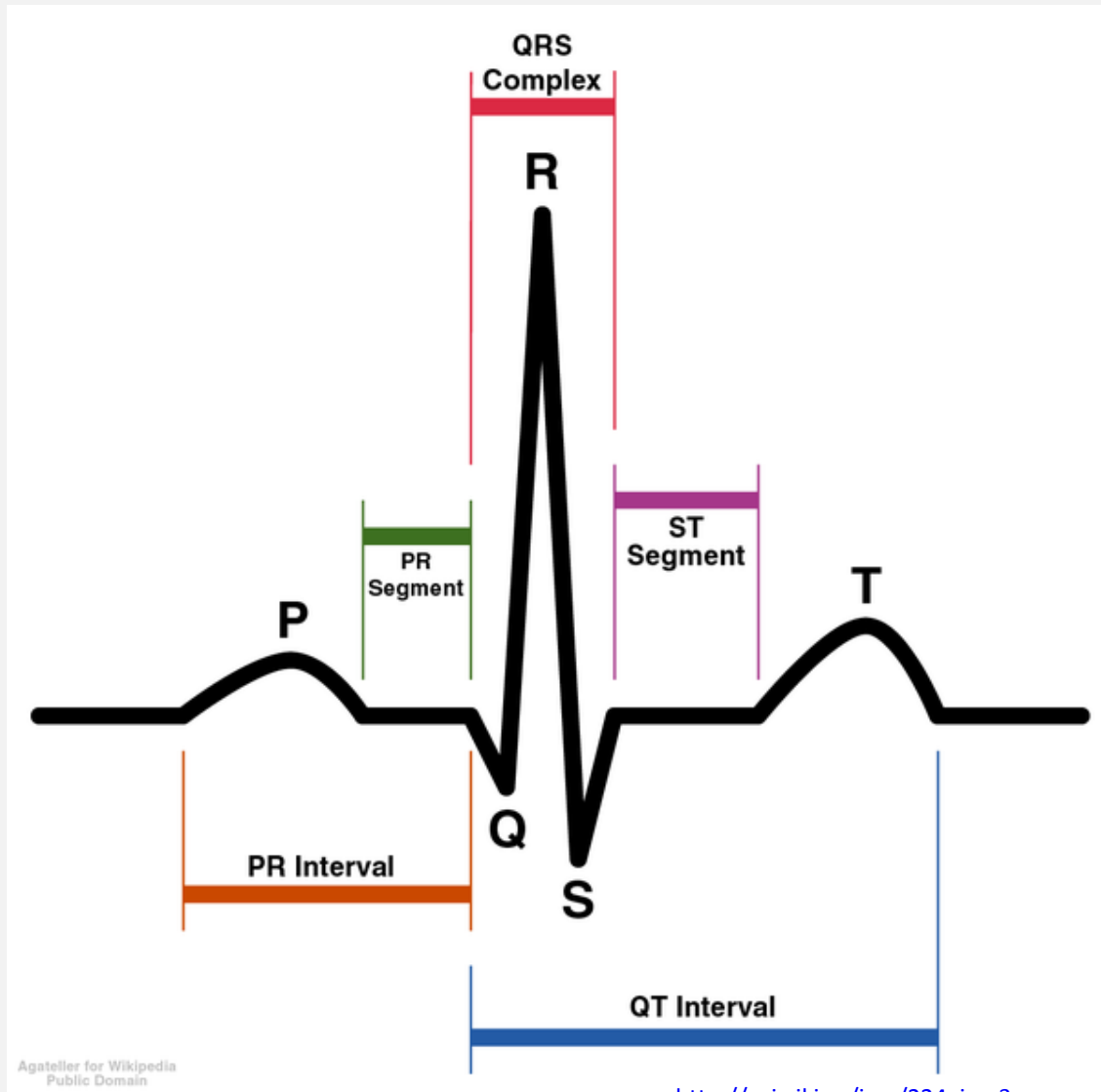


Segment - straight line connecting two waves

Interval - at least one wave plus connecting straight line

The main ECG components:

- P-wave, PR interval
- QRS complex
- T wave, ST segment
- QT interval



# Wave deflections




- Any waveform above the isoelectric line is considered a positive (upright) deflection and any waveform below this line a negative (downward) deflection.
- A deflection having both a positive and negative component is called a biphasic deflection.
- This basic concept can be applied to the P wave, the QRS complex, and the T wave deflections.


Positive deflection



Biphasic deflection



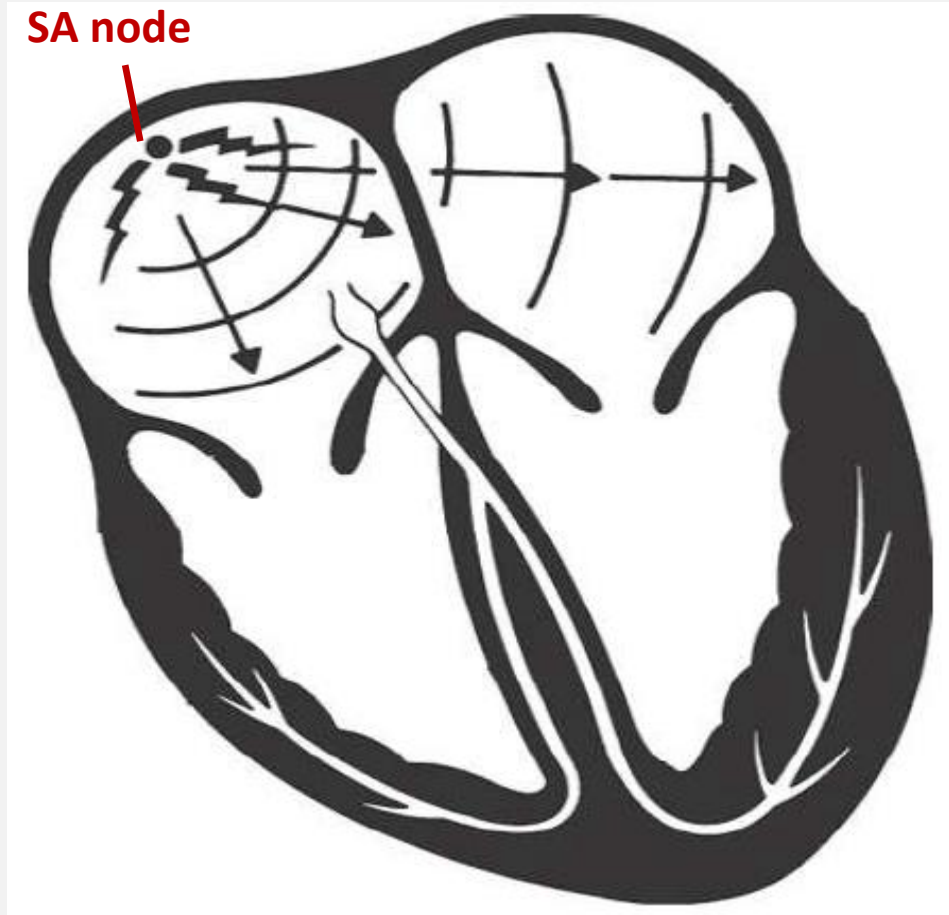
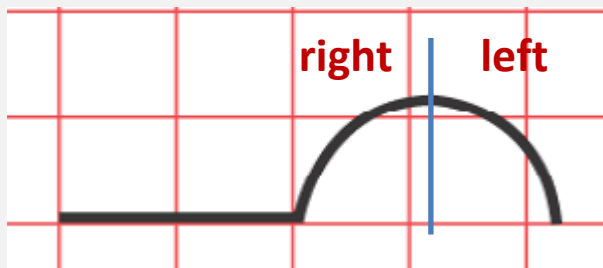
Negative deflection



# P wave



- The P wave records atrial depolarization and contraction.
- The first part of the P wave reflects **right atrial activity**; the second part reflects **left atrial activity**.


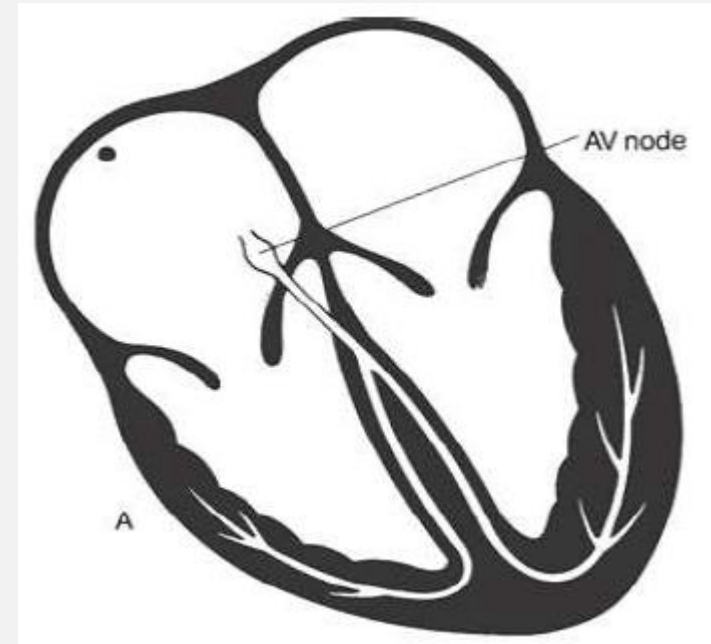


The SA node depolarizes spontaneously and atrial depolarization begins from the **right atrium to the left**

# Conduction through the AV node



- Once atrial depolarization is complete, the ECG becomes electrically silent because of physiological delay - conduction pause at the atrioventricular (AV) node that acts like a gatekeeper between atria and ventricles.
- This pause is essential to allow the atria to finish contracting before the ventricles begin to contract.



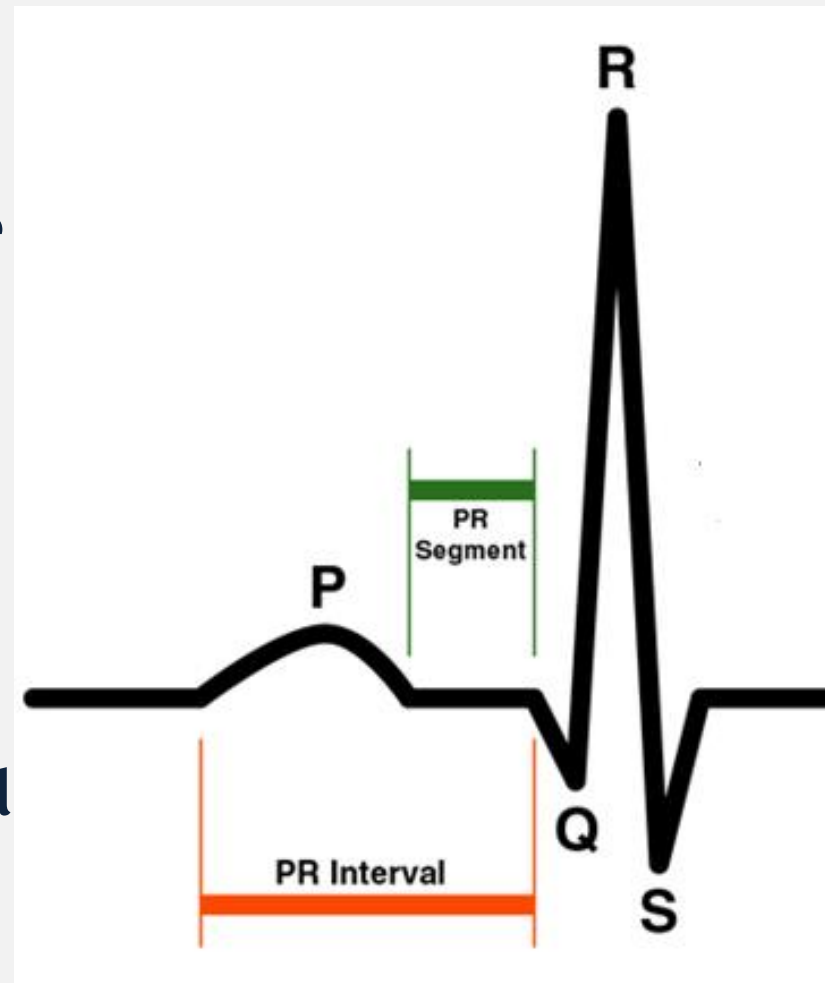
conduction pause at the  
atrioventricular (AV) node



# PR segment, PR interval



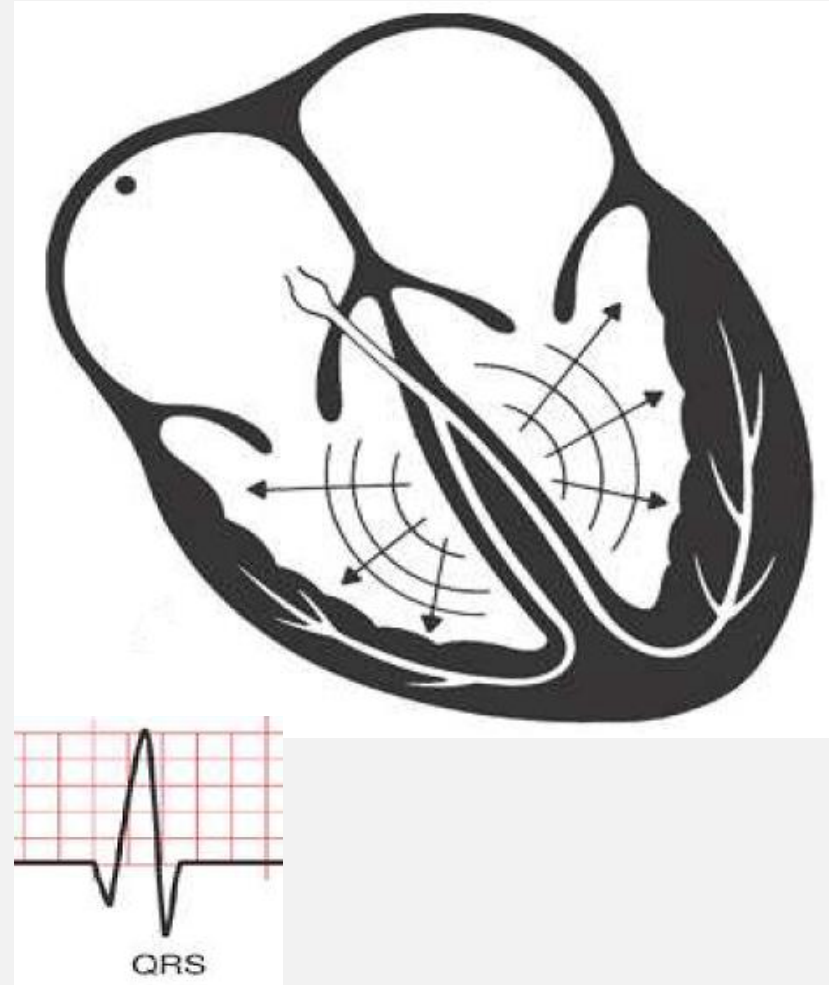
- The PR interval includes the P wave and the straight line connecting it to the QRS complex; it measures the time from the start of atrial depolarization to the start of ventricular depolarization.
- The PR segment is the straight line running from the end of the P wave to the start of the QRS complex and measures the time from the end of atrial depolarization to the start of ventricular depolarization



# QRS complex



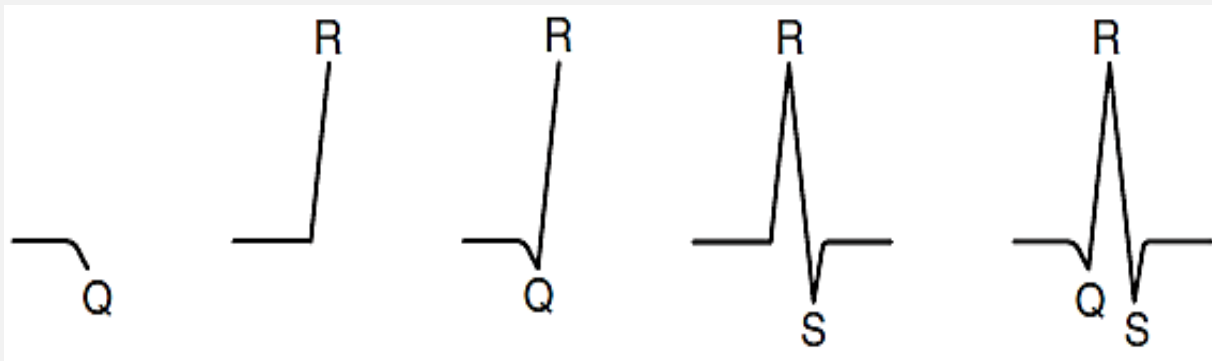
- The appearance of QRS complex indicates ventricular myocardial depolarization and thus ventricular contraction.
- Ventricular depolarization starts with septum.
- The amplitude of the QRS complex is much greater than that of the atrial P wave because the more prominent muscle mass of the ventricles.
- The QRS complex may have variable shape and configuration.



# Parts of the QRS complex



- Q wave reflects the depolarization of the septum with electrical vector directed right and downward (negative deflection).
- R wave reflects the depolarization of apical part of ventricular myocardium with electrical vector directed left and down.
- S wave represents progression of depolarization over ventricles, vector extends upward.

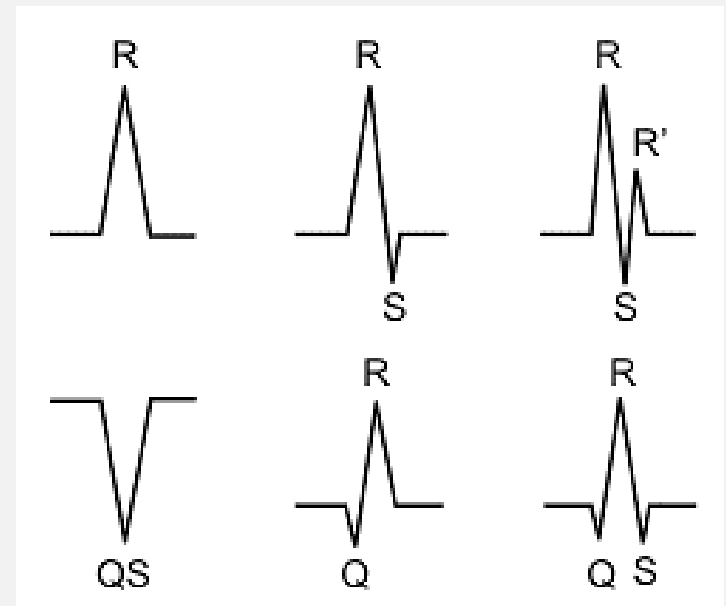


# Q wave vs S wave



- A downward deflection can only be called a Q wave if it is the first wave of the complex. Any other downward deflection is called an S wave.
- If the entire configuration consists solely of one downward deflection, the wave is called a QS wave.

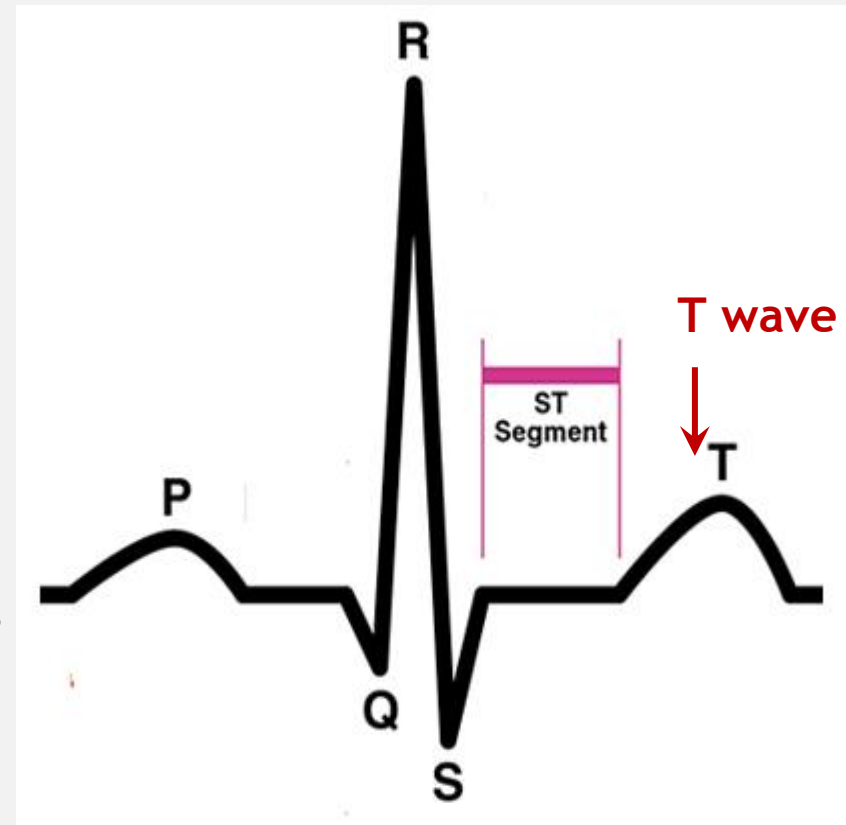
**Different shapes of QRS complex**



# T wave, ST segment



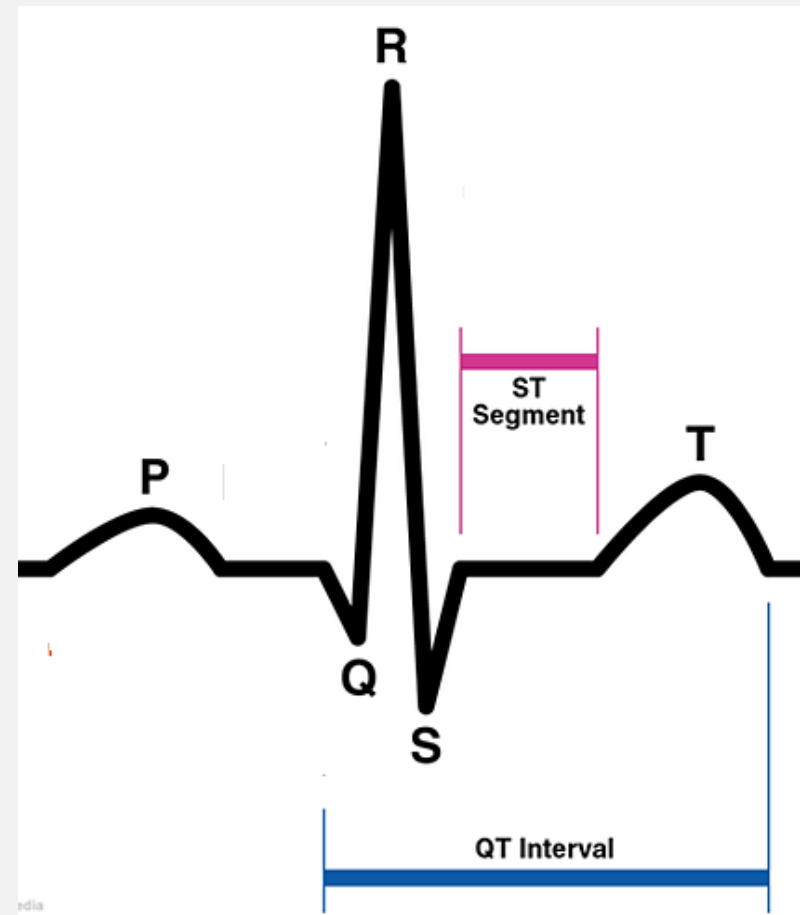
- After short refractory period characterized by isoline on ECG, appears T wave indicating ventricular repolarization;
- The ST segment is the straight line connecting the end of the QRS complex with the beginning of the T wave
- ST segment measures the time from the end of ventricular depolarization to the start of ventricular repolarization.
- **NB!** atrial repolarization wave is buried under QRS complex and is not visible.



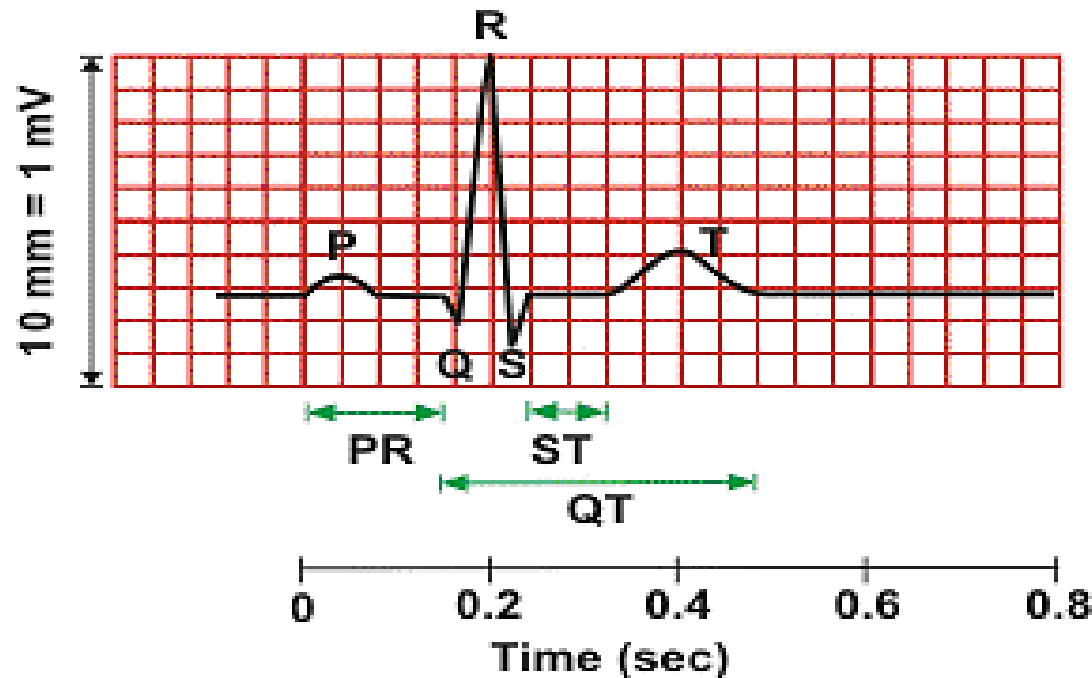
# QT interval



- The QT interval includes the QRS complex, the ST segment, and the T wave.
- It measures the time from the beginning of ventricular depolarization to the end of ventricular repolarization.
- The corrected QT interval (QTc) estimates the QT interval due to the heart rate.
- $QTc = \text{measured QT} / \sqrt{RR}$  (in seconds)



# Duration of the main ECG components



P wave (0.08 - 0.10 s)

QRS (0.06 - 0.10 s)

P-R interval (0.12 - 0.20 s)

Q-T<sub>c</sub> interval ( $\leq 0.44$  s)\*

$$*QT_c = \frac{QT}{\sqrt{RR}}$$

# Anamnesis and ECG: key points



Before ECG recording essential is to assess the anamnesis of the patient.

- Assess complaints of the patient: palpitations, intermissions in the work of the heart, chest pain (localization, duration, character of the pain, irradiation, provoking and relieving factors, etc.), episodes of fainting, dizziness, etc.
- Assess anamnesis morbi and vitae: drug history, previous interventions, hospitalizations, family history of cardiovascular diseases, lifestyle habits (diet, smoking, alcohol intake, etc.), occupational conditions

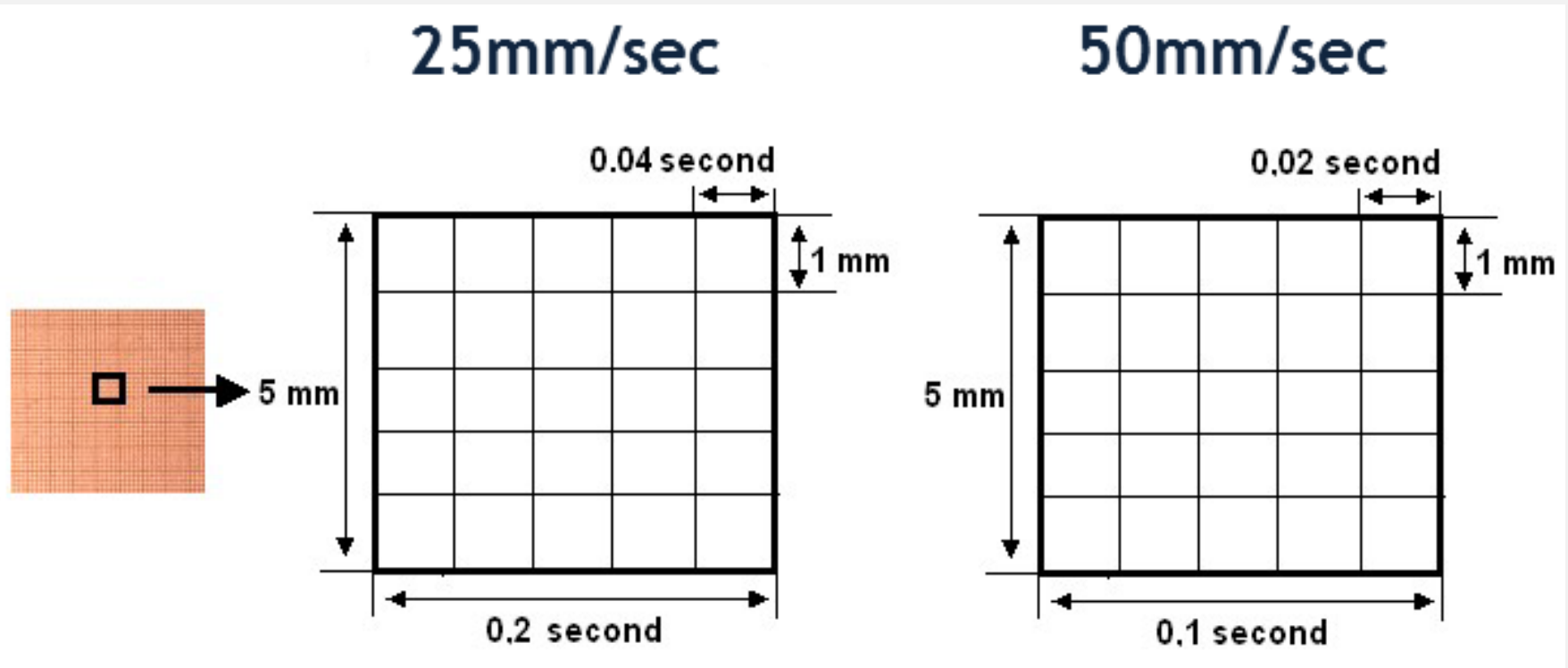


# ECG interpretation:



- Rate (normal, tachycardia, bradycardia);
- Rhythm (sinus/non sinus; regular/irregular)
- Electric axis (normal, left axis deviation, right axis deviation);
- Waves and intervals calculation with description of morphology;
- Check for signs of hypertrophy of heart chambers;
- Check for signs of ischemia and MI;
- Check for signs of arrhythmias;
- Check for signs of AV blocks, bundle branch blocks;

# ECG paper: how to calculate



Adopted from: Electrocardiographic method of cardiac function examination.  
Technique of ECG registration and reading. Method. instr. for students /  
Authors. T.V. Ashcheulova, O.N. Kovalyova, A.V. Demydenko, page 5.

# Heart rate evaluation for regular rhythms:

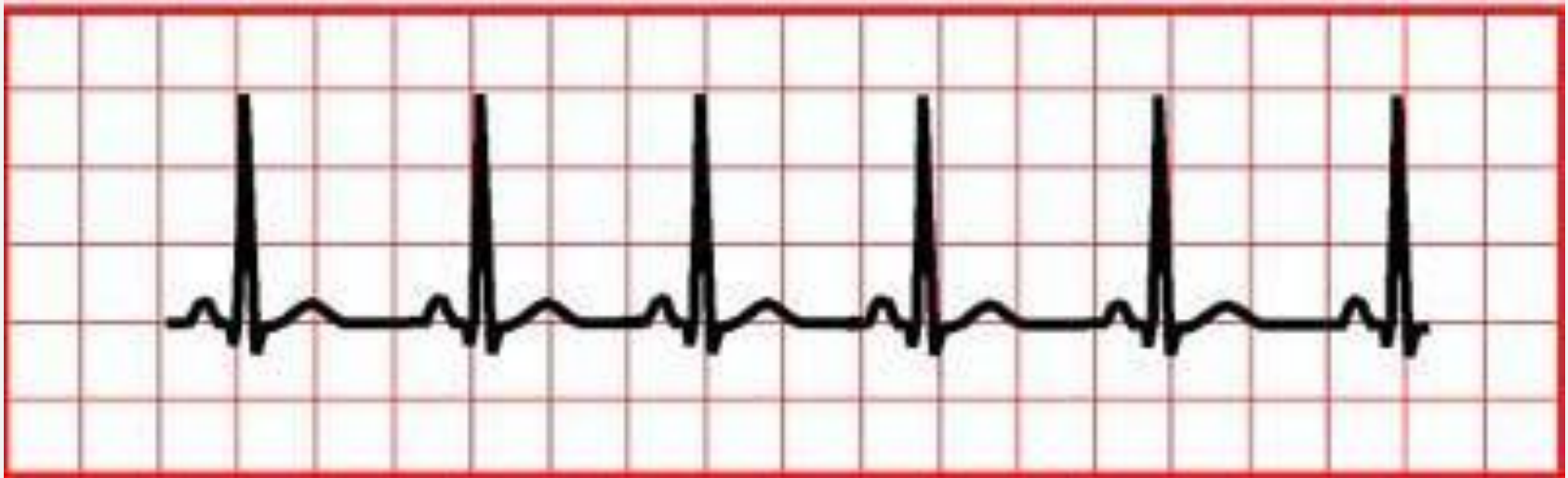


- Count the number of “big boxes” between two QRS complexes, and divide this into 300/600 (depend on speed of ECG paper - 25 or 50 mm/sec).
- Count the number of “small boxes ” between two QRS complexes, and divide this into 1500/3000 (depend on speed of ECG paper - 25 or 50 mm/sec).
- $HR = 60 / RR \text{ (in seconds)}$

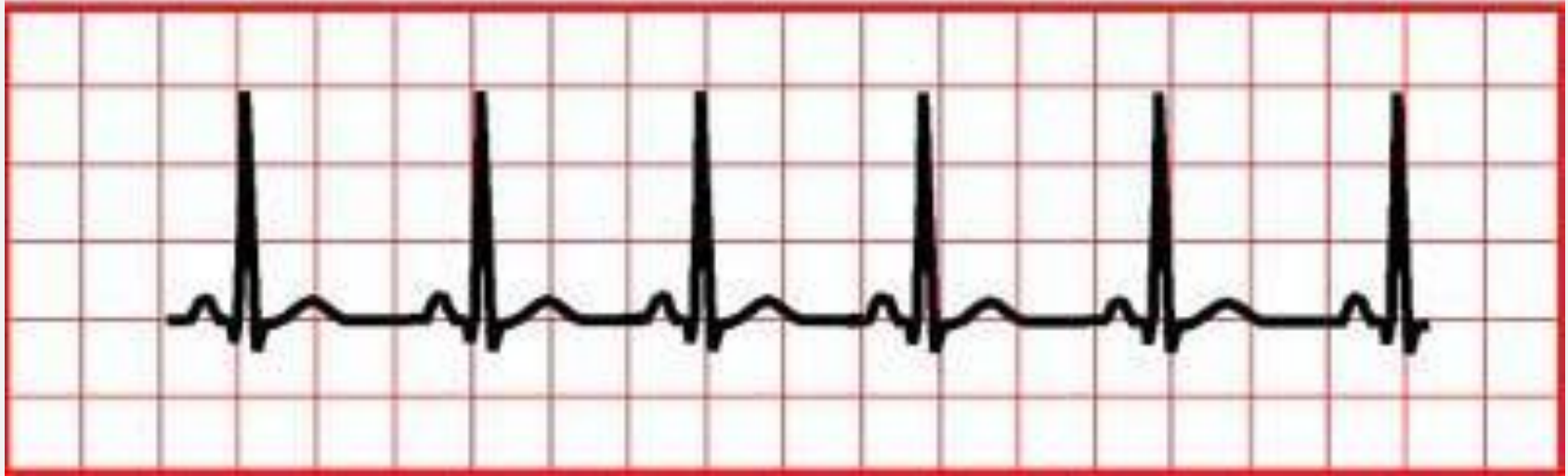
# Practical part



- Count the heart rate on ecg below using “big boxes method”



# Practical part



## Speed 25 mm/s:

- $HR = 300 / \text{amount of "big boxes"} = 300 / 3 = 100$ ;
- $HR = 60 / \text{RR in sec} = 60 / (3 * 0,2) = 60 / 0,6 = 100$

## Speed 50 mm/s

- $HR = 600 / \text{amount of "big boxes"} = 600 / 3 = 200$ ;
- $HR = 60 / \text{RR in sec} = 60 / (3 * 0,1) = 60 / 0,3 = 200$

# Heart rate evaluation for irregular rhythms:



- Six-second method:

Count off 6 seconds on ECG strip (remember 1 large box = 0.2 seconds if speed is 25mm/sec 1 large box = 0.1 seconds if speed is 50mm/sec and so 30 or 60 large boxes = 6 seconds). Then, count the number of R-R intervals in six seconds and multiply by 10.

- Three seconds method:

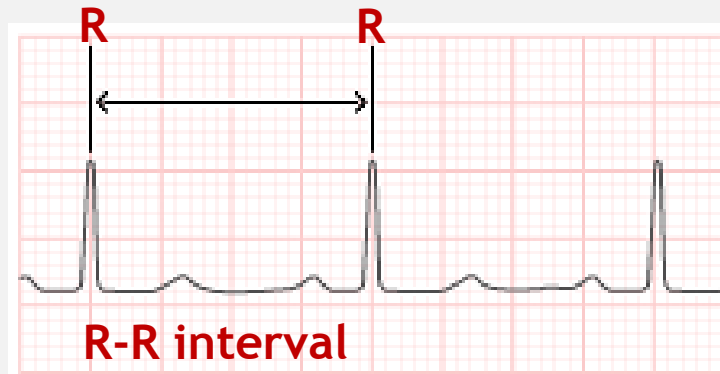
Count off 3 seconds on ECG strip;

Then count the number of R-R intervals in three seconds and multiply by 20.

# Rhythm



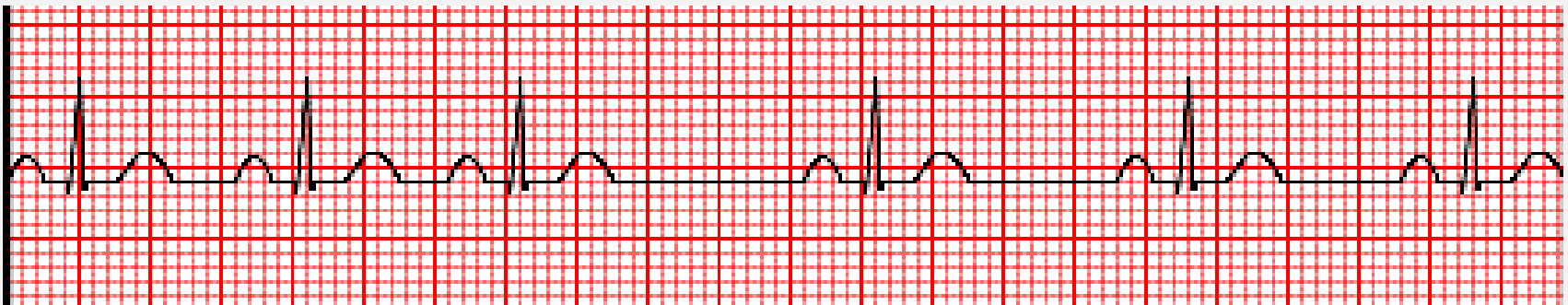
- Presence of positive P wave of the same shape before QRS complex indicates sinus rhythm;
- Negative P waves in sinus rhythm can be seen in lead aVR.
- Equal RR intervals ( $\pm 10\%$ ) indicate regular rhythm;



# Practical part



Is rhythm on this ECG strip sinus and regular?

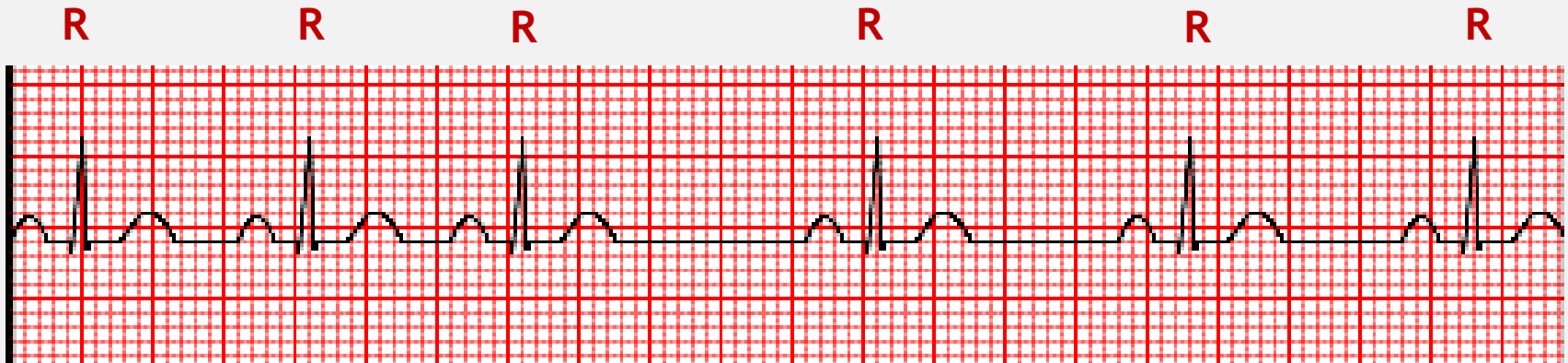




# Practical part



- This rhythm is sinus - there is P wave before each QRS complex;
- The rhythm is irregular - R-R intervals are not equal;
- It's sinus arrhythmia



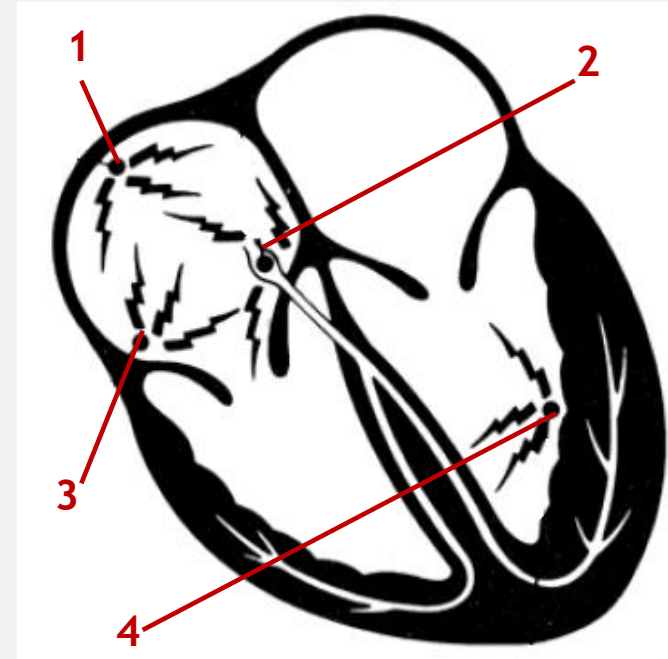
# Non sinus (ectopic) pacemakers



When an electrical signal is generated from the group of cells outside the SA node (ectopic focus) its called **non sinus or ectopic pacemaker**.

The ectopic focus can be in the atria, junction (the AV node) or in the ventricles. It may cause:

- Premature beats
- Escape beats
- Pacing the heart (atrial rhythms, junctional rhythms, ventricular rh.)



- 1- SA node (sinus pacemaker)
- 2- junctional pacemaker (AV node)
- 3- atrial pacemaker (ectopic focus)
- 4- ventricular pacemaker (ectopic focus)

# Non sinus pacemakers vs heart rate



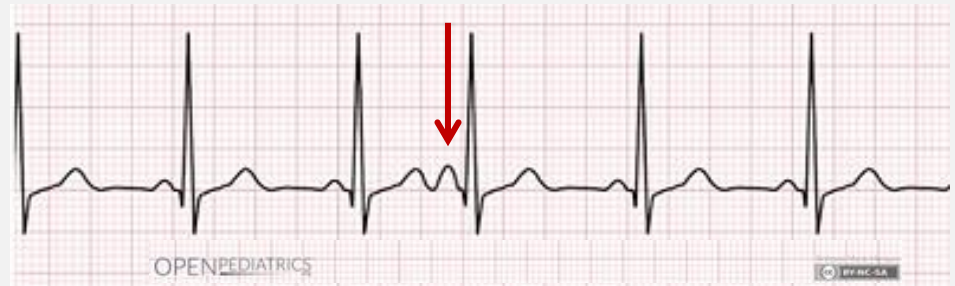Localization of the pacemaker	Heart rate
Atria	60-75
AV node ( junctional)	40-60
Ventricles	20-40

**NB!** The activity of non sinus (ectopic) pacemakers is normally suppressed by the higher rate of the SA node (60-100 bpm).

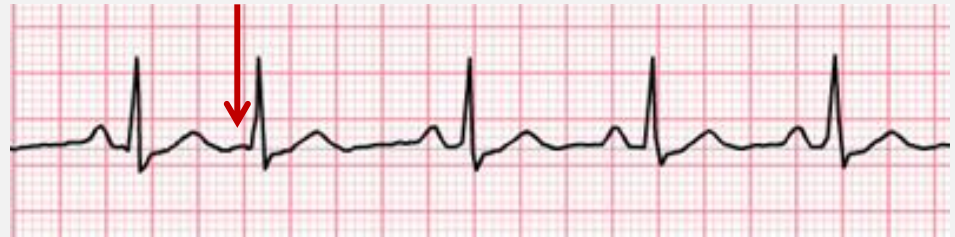# ECG examples of non-sinus contractions



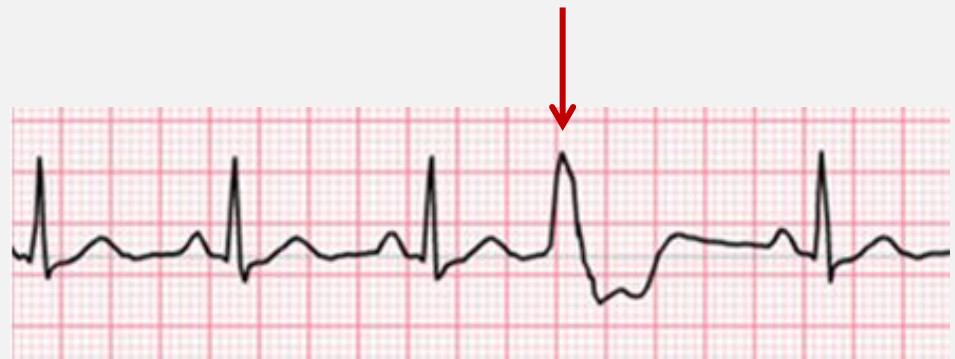**1. Premature atrial contraction (PAC);**



**2. Premature junctional contraction (PJC);**



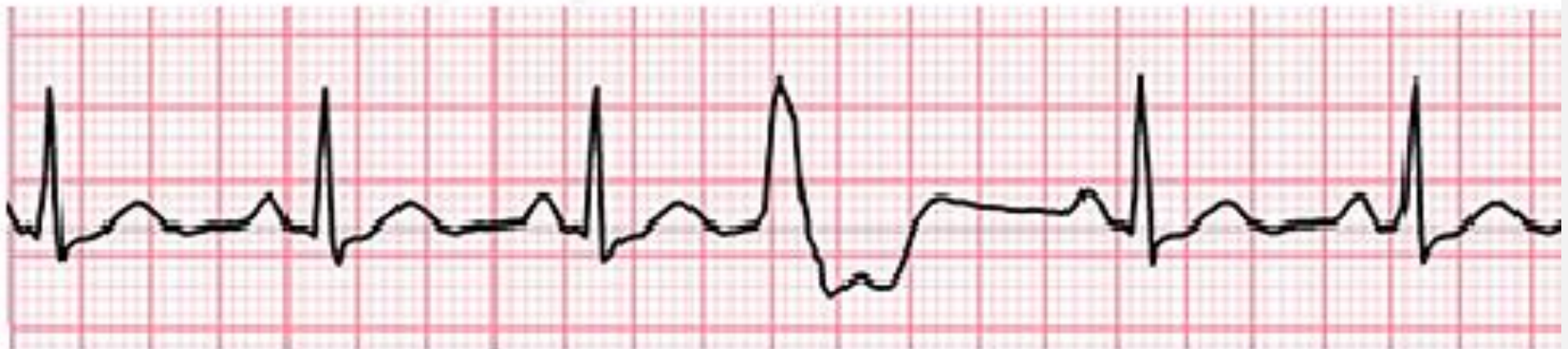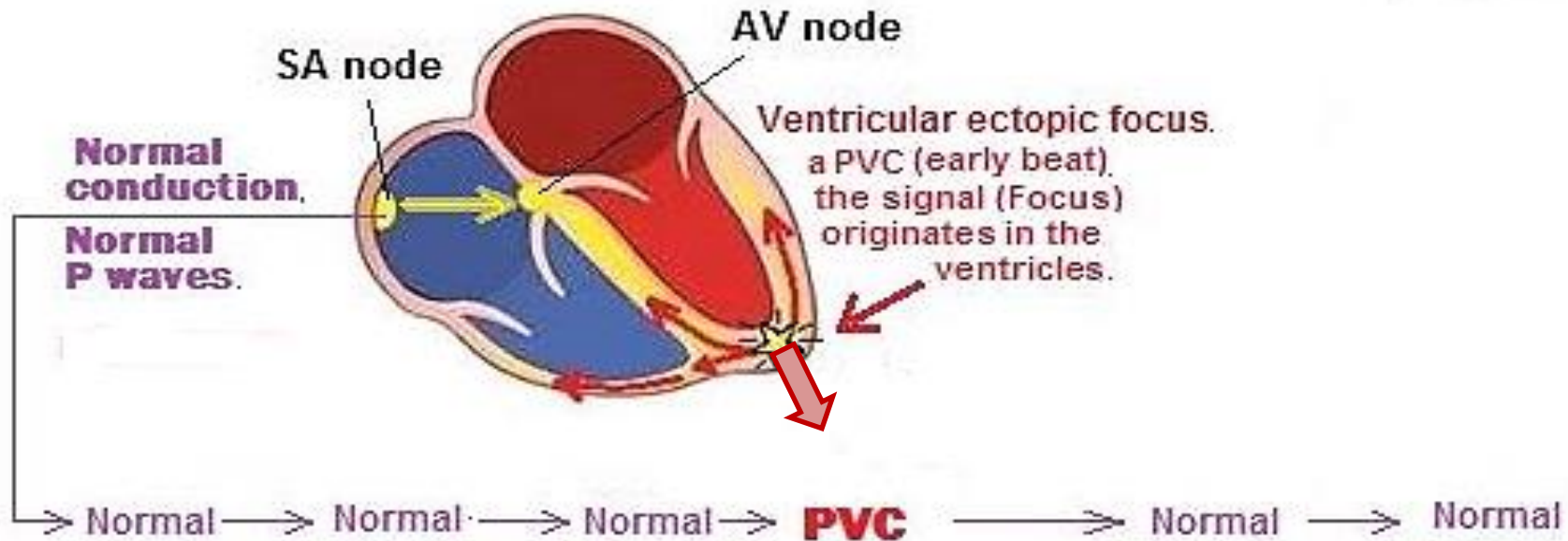
**3. Premature ventricular contraction (PVC).**



<https://www.practicalclinicalskills.com/ekg-practice-drill-directory-detail?category=PJC>

[http://www.medicine-on-line.com/html/ecg/e0001en\\_files/08.htm](http://www.medicine-on-line.com/html/ecg/e0001en_files/08.htm)

# Pathophysiology of ectopic pacemaker

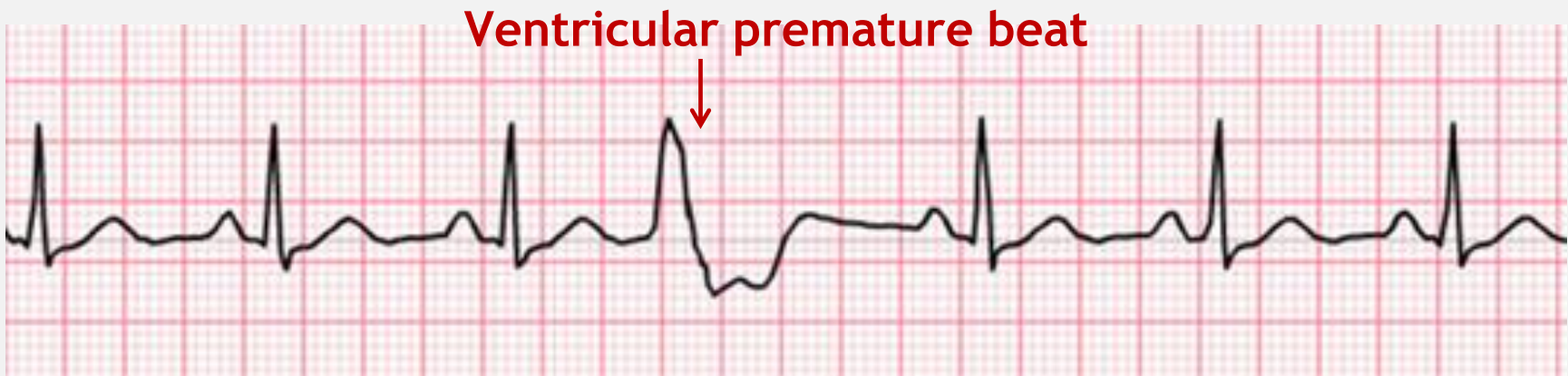




# Premature beat



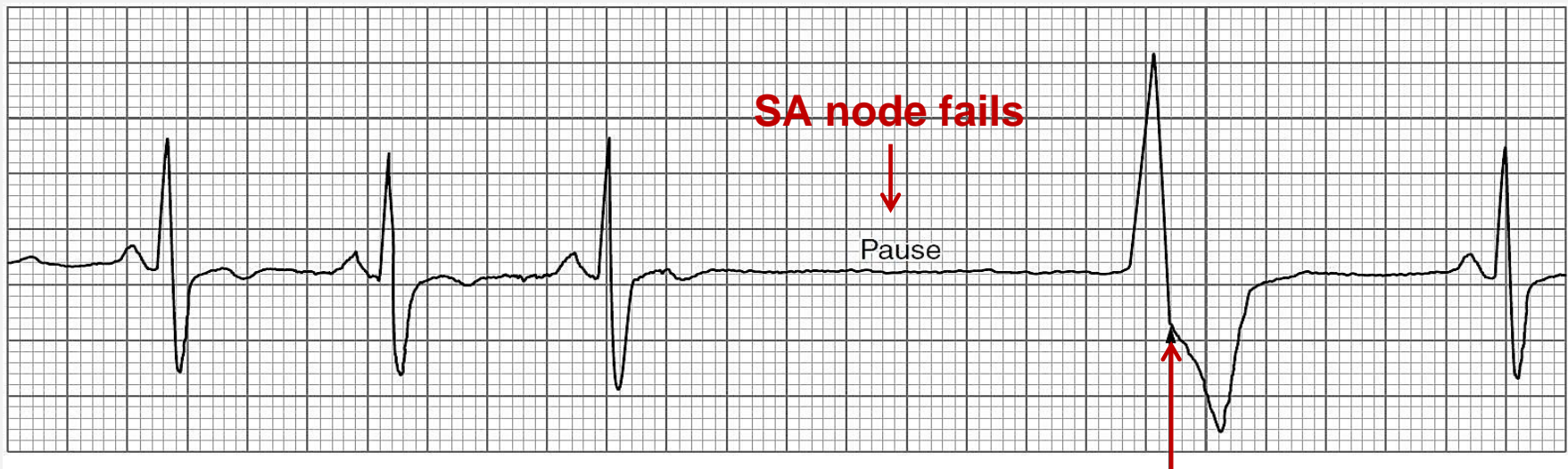
- **A premature beat** arises from an ectopic pacemaker: in the atria, the AV junction, or the ventricles. The non-sinus impulse is early, initiating a heart beat before the next anticipated sinus beat implies. The reason the ectopic focus discharges a pacing impulse early in this instance is because the ectopic focus is irritable and competes with the sinus node.



# Escape beat



- **An escape beat** is a heart beat arising from an ectopic focus in the atria, the AV junction, or the ventricles when the sinus node fails in its role as a pacemaker or when the sinus impulse fails to be conducted to the ventricles as in complete heart block





# Heart rate and rhythm abnormalities



## For sinus rhythms:

- Sinus tachycardia ( $>100$  bpm);
- Sinus bradycardia ( $<60$  bpm);
- Sinus arrhythmia, sick sinus syndrome

## For non sinus rhythms:

**Atria:** supraventricular tachycardia, atrial fibrillation, atrial flutter, wandering atrial pacemaker, PAC, multifocal atrial tachycardia

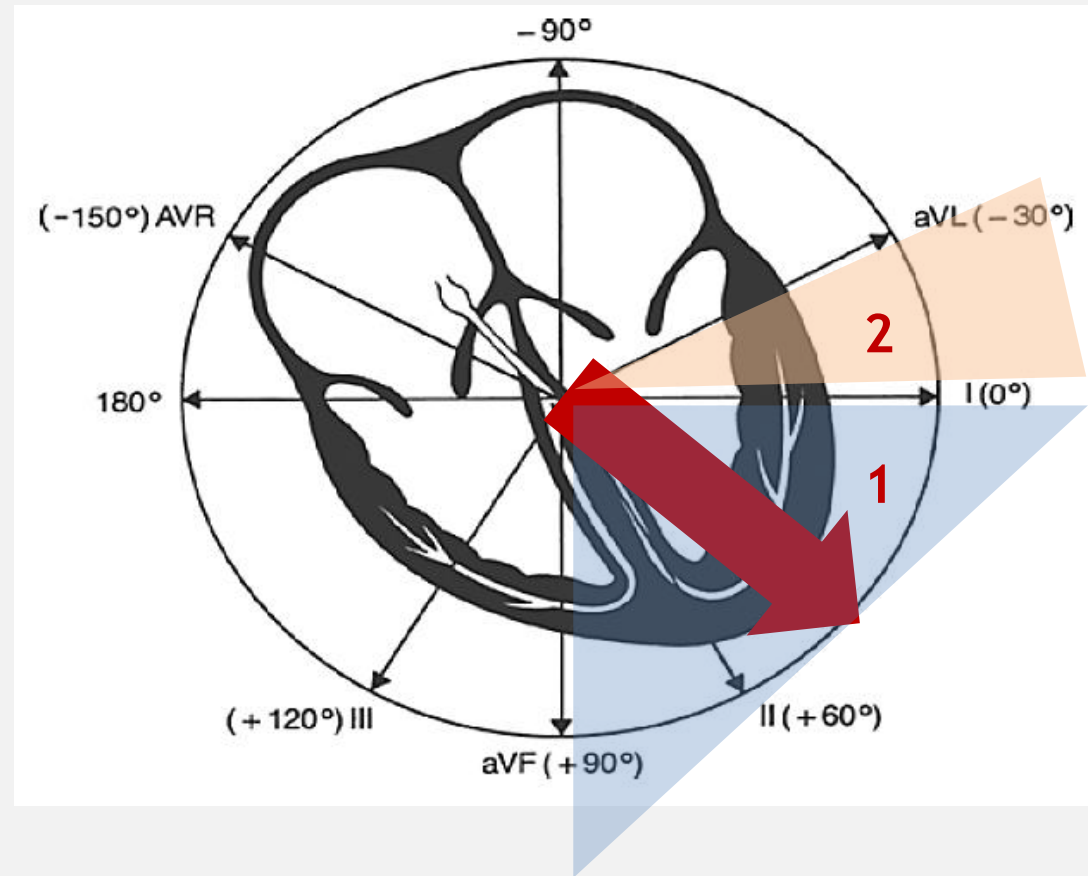
**AV node:** junctional rhythm; junctional tachycardia;

**Ventricles:** PVC, ventricular tachycardia, idioventricular rhythm, accelerated Idioventricular rhythm, ventricular fibrillation.

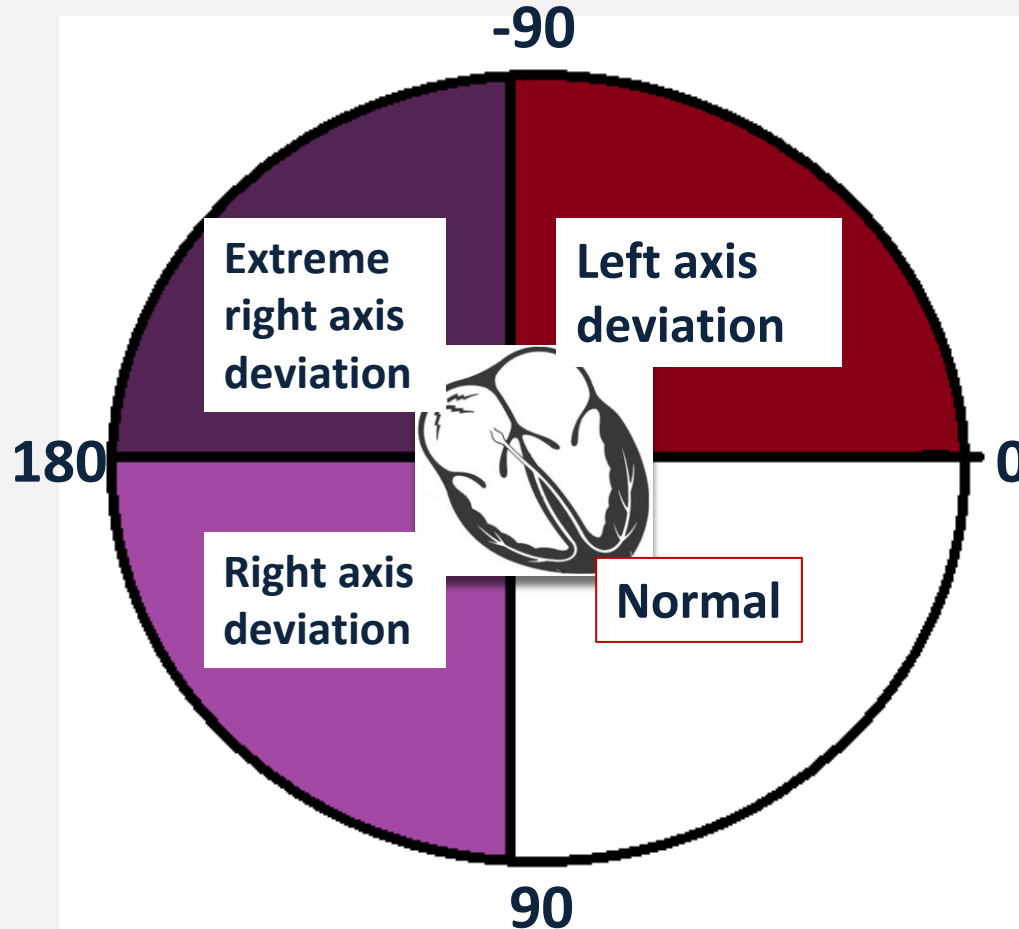
# Electrical axis of the heart



- Normally the position of the mean electrical axis lies in the range: 0 - 90 (1).
- Some researchers extend it at the level: -30 - 90 (2).



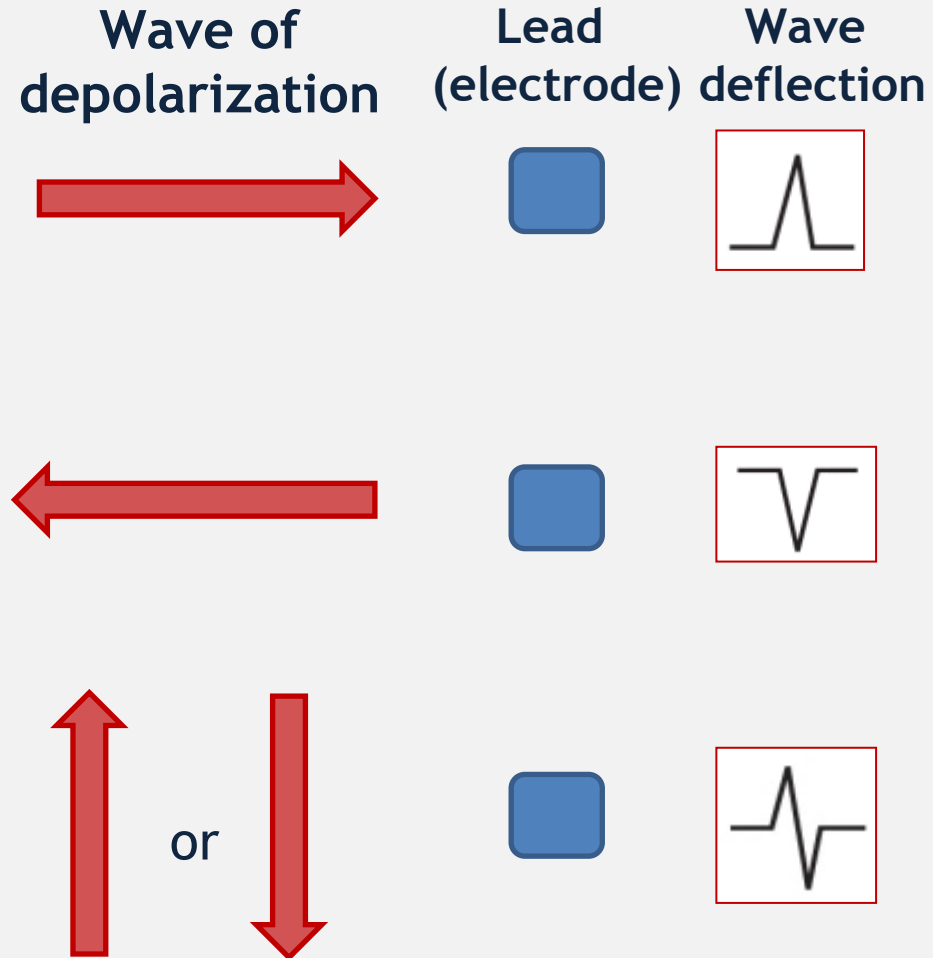
# Positions of electric axis of the heart



# Wave deflections vs. mean electrical vector




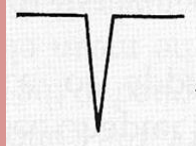
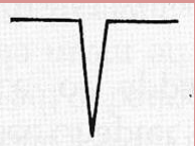

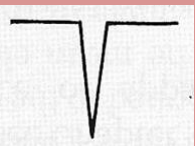
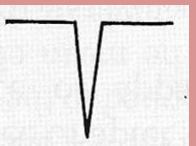


- a positive wave deflection is recorded by the lead if the wave of depolarization is moving toward it;
- a negative wave deflection is recorded by the lead if the wave of depolarization is moving away from it;
- a biphasic wave deflection is recorded by the lead if the depolarization wave is moving perpendicular to it (90°).



# Electric axis determination (fast method)



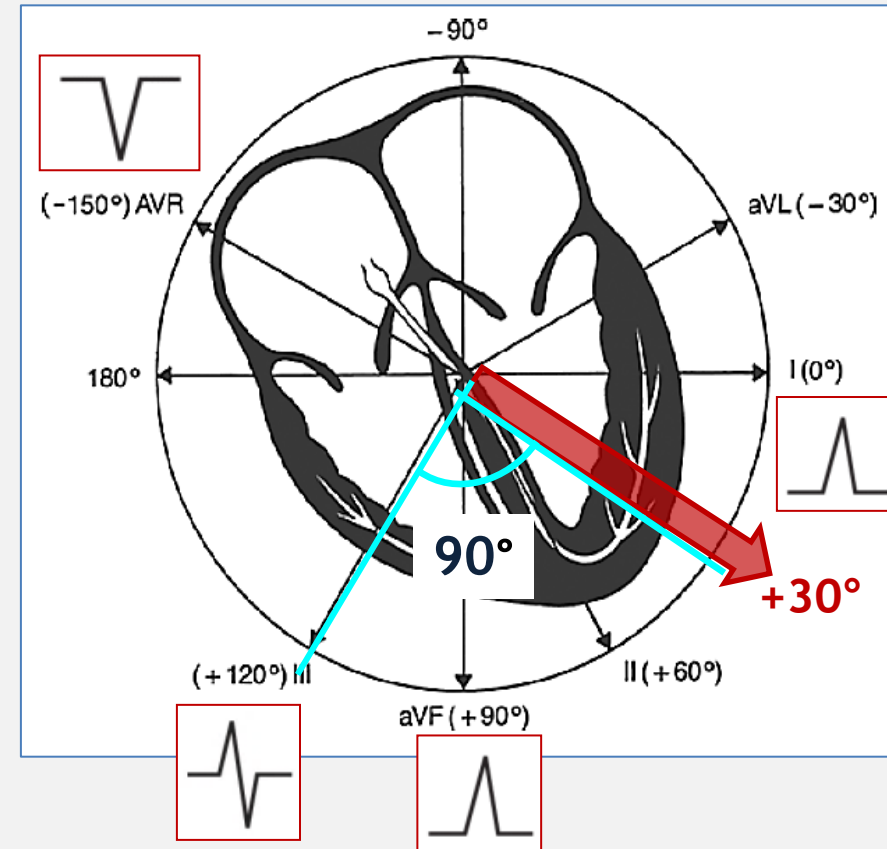
Lead I	Lead aVF	Description	Axis
+ 	+ 	Dominant R wave in lead I, aVF	<u>Normal</u> 0 to 90 degrees
+ 	- 	Dominant R wave in lead I, dominant S wave in aVF	<u>Left axis deviation</u> 0 to (-90) degrees
- 	+ 	Dominant R wave in lead I, dominant S wave in aVF	<u>Right axis deviation</u> 90 to 180 degrees
- 	- 	Dominant S wave in lead I, aVF	<u>Extreme right axis deviation</u> -90 to 180 degrees

# Electrical axis determination and biphasic leads



Analysis of biphasic leads allows a more precise estimation of the electrical axis;

Example: if the QRS complex in lead III is biphasic, then the axis must be oriented at right angles ( $90^\circ$ ) to this lead, at either  $+30^\circ$  or  $-150^\circ$ . And, if we already know that the axis is normal—that is, if the QRS complex is positive in leads I and AVF—then the axis cannot be  $-150^\circ$ , but must be  $+30^\circ$ .



# Axis deviation (causes)



## Right axis deviation -

### RALPH:

- **R**ight ventricular hypertrophy
- **A**nterolateral MI
- **L**eft **P**osterior **H**emiblock

## Left axis deviation -

### VILLA:

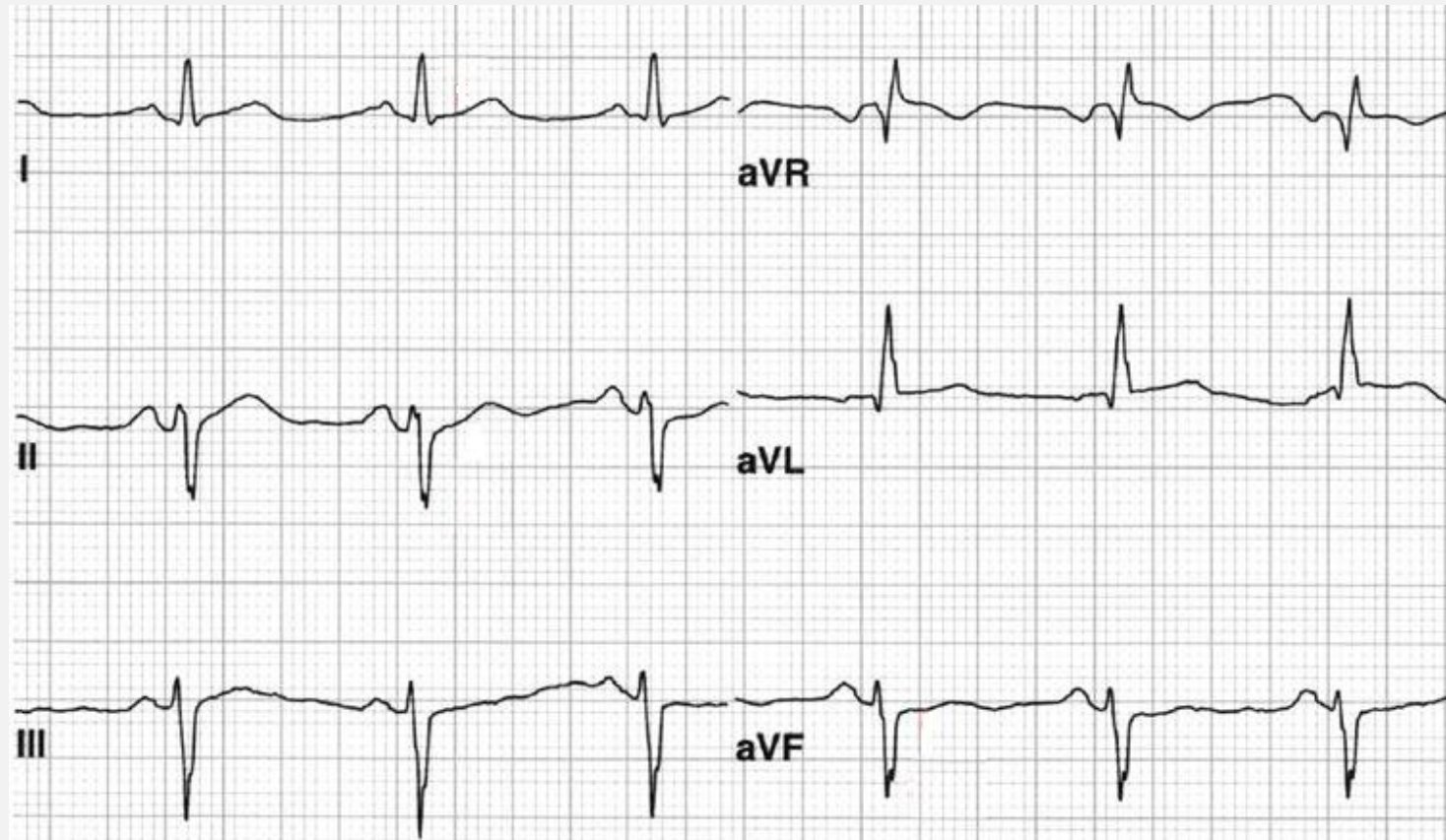
- **V**entricular tachycardia
- **I**nferior MI
- **L**eft ventricular hypertrophy
- **L**eft **A**nterior hemiblock



# Practical part



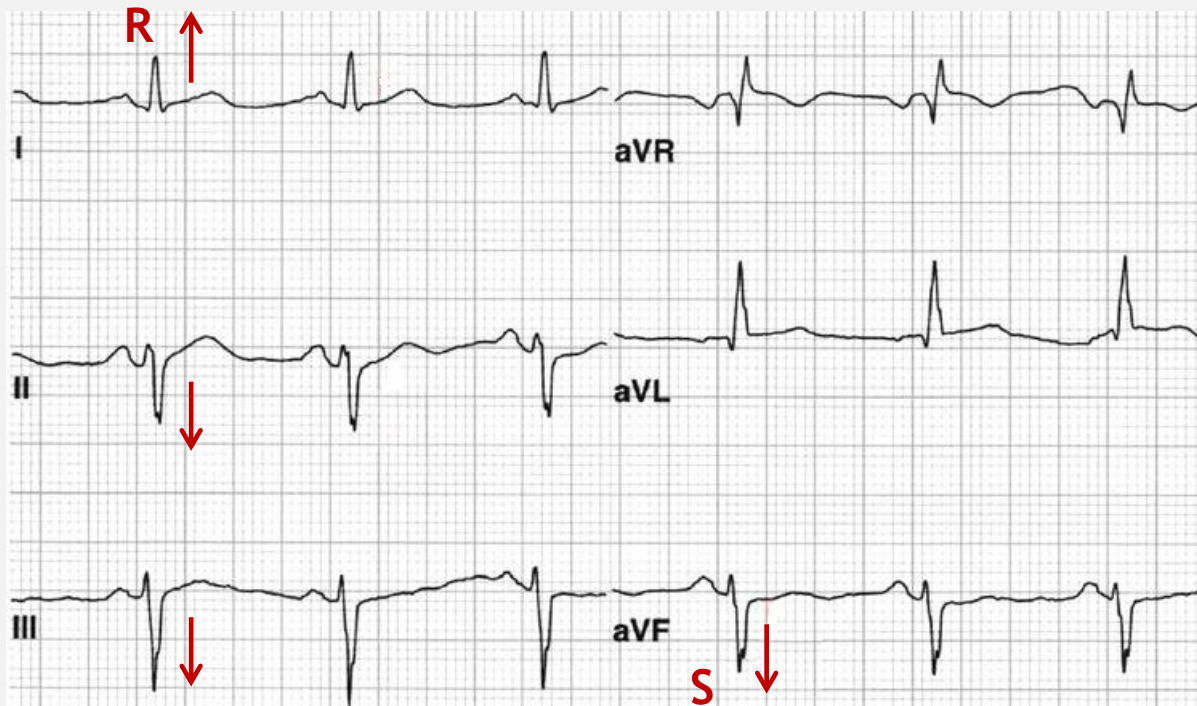
- What is position of the electrical axis of the heart on this ECG?



# Practical part



- Lead I: R wave is dominant (so called positive QRS);
- Lead III: S wave is dominant (negative QRS);
- Also negative QRS in leads II, avF;
- It's left axis deviation

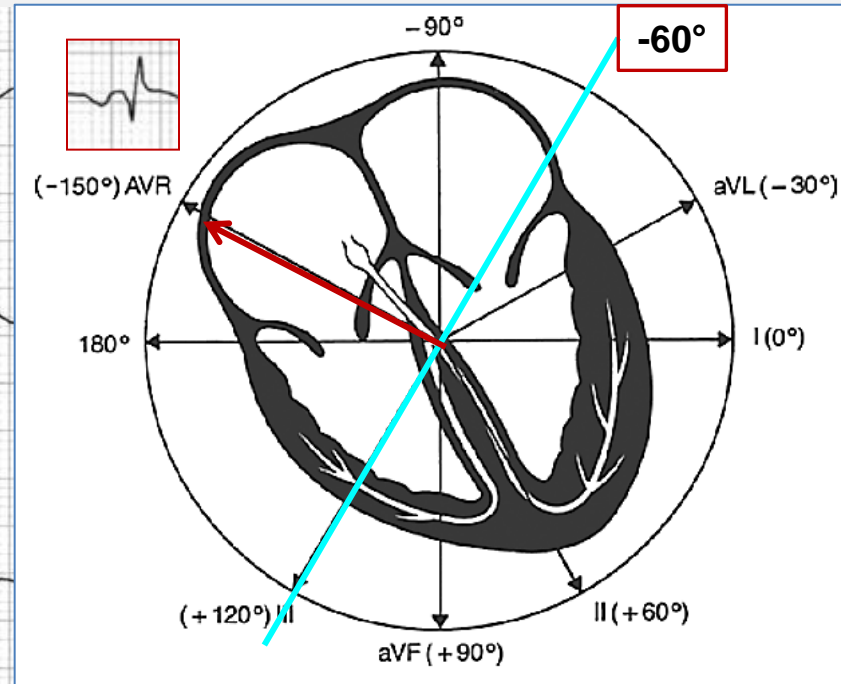
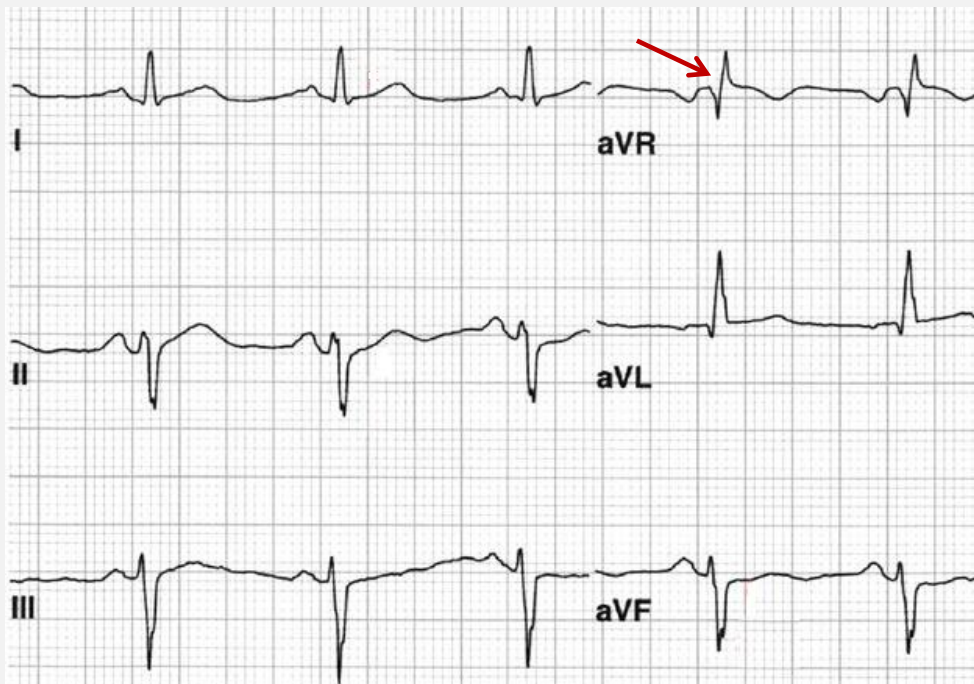


[https://www.researchgate.net/profile/Sanjay\\_Sharma32/publication/234099418/figure/fig5/AS:300132902948868@1448568668528/ECG-demonstrates-abnormal-left-axis-deviation-defined-as-frontal-plane-QRS-axis-of-less\\_W640.jpg](https://www.researchgate.net/profile/Sanjay_Sharma32/publication/234099418/figure/fig5/AS:300132902948868@1448568668528/ECG-demonstrates-abnormal-left-axis-deviation-defined-as-frontal-plane-QRS-axis-of-less_W640.jpg)

# Practical part



In lead aVR QRS complex is biphasic, so electrical axis (mean vector) should be on it's perpendicular line - or  $+120^\circ$  or  $-60^\circ$ . But we already know that that the axis falls within the zone of left axis deviation (i .e., between  $0^\circ$  and  $-90^\circ$ ), the correct axis must be  $-60^\circ$ .



# Normal P wave: features



- Normal P wave is positive in lead I, II, aVF, V4-V6 and negative in aVR (in the same direction as QRS complex).
- It is often biphasic in leads III and V1 with similar sizes of the positive and negative deflections.
- It is best visualized in lead II, aVF, V1.
- The P wave in lead II is typically rounded and upright in appearance.
- The duration of P wave is less than 0,12 sec.
- The amplitude of P wave is  $< 2.5$  mm in the limb leads,  $< 1.5$  mm in the precordial leads

# P wave: key points



- Is P wave present?
- Is it positive/negative (inverted)/biphasic?
- Amplitude of P wave increased/normal/decreased?
- Is P wave widened?
- Shape of the P wave: rounded and upright/peaked, flattened/biphasic/notched/ “M”-shaped ?
- Is it present before each QRS?
- Does it have the same shape and morphology before each QRS?
- Does the atrial rate correspond to ventricular rate?

# P wave abnormalities



## Different shape of P wave:

- Ectopic atrial focus; Wandering atrial pacemaker; multifocal atrial tachycardia
- Signs of atrial hypertrophy ( P mitrale, P pulmonale);

## Inverted P wave:

- Junctional premature or escape beat; Junctional rhythm;
- Ectopic atrial focus near the AV node;

## Absent P wave:

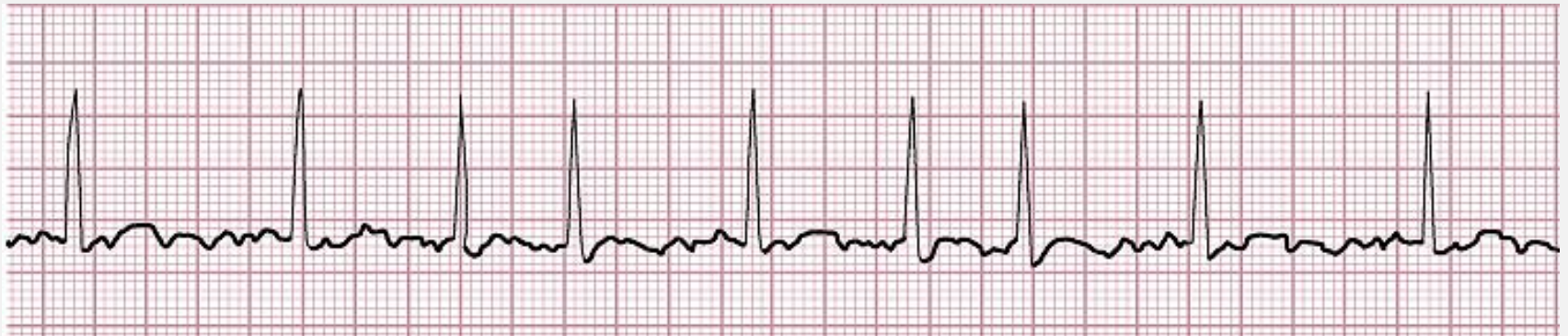- Atrial fibrillation (f waves present instead);
- Atrial flutter (F waves present instead);
- Sinoatrial node block;
- Junctional premature or escape beat; Junctional rhythm;
- Premature ventricle contraction (PVC); Idioventricular rhythm; Ventricular tachycardia; Ventricular fibrillation;



# Practical part



- Evaluate characteristics of P wave and rhythm on the ECG below.

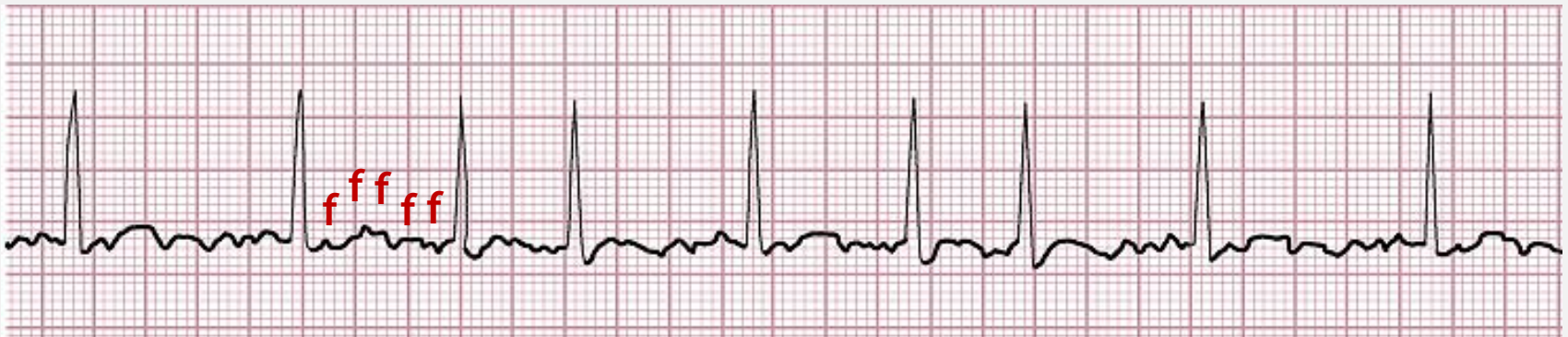



# Practical part



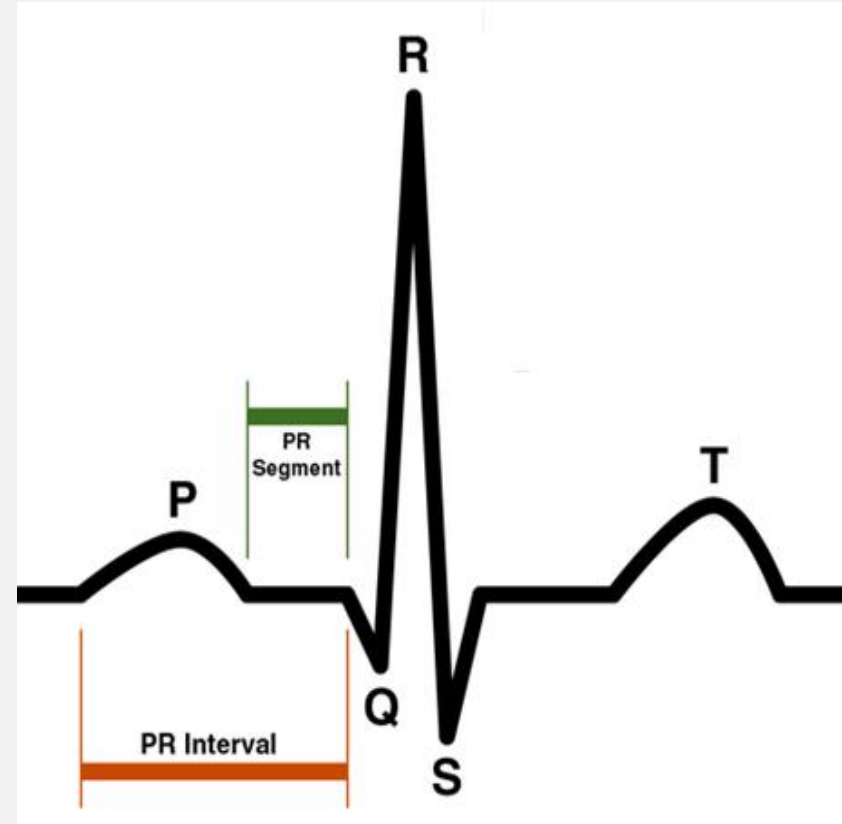
- P wave is absent;
- Rhythm is non sinus, irregular;
- There are multiple f waves present instead of P wave;
- It's atrial fibrillation



# Normal PR interval features



- **PR interval** is measured from the beginning of the upslope of the P wave to the beginning of the QRS complex.
- PR interval normally is 0,12 to 0,2 sec;
- PR interval shortens with increased heart rate;
- **The PR segment** is usually horizontal and runs along the same baseline as the start of the P wave.

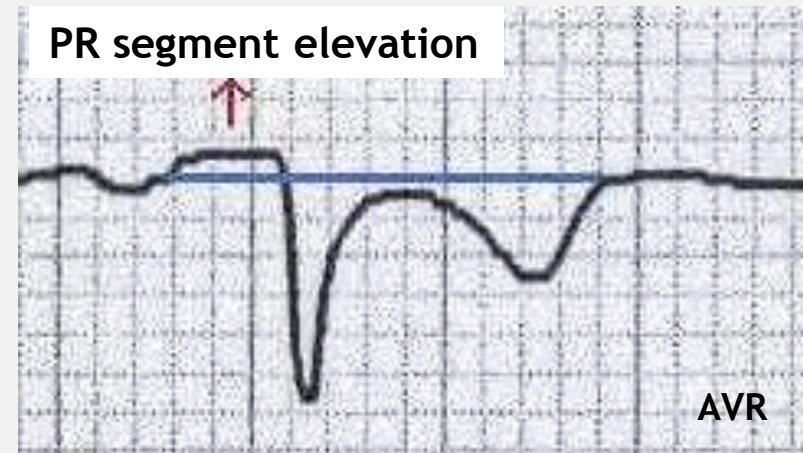
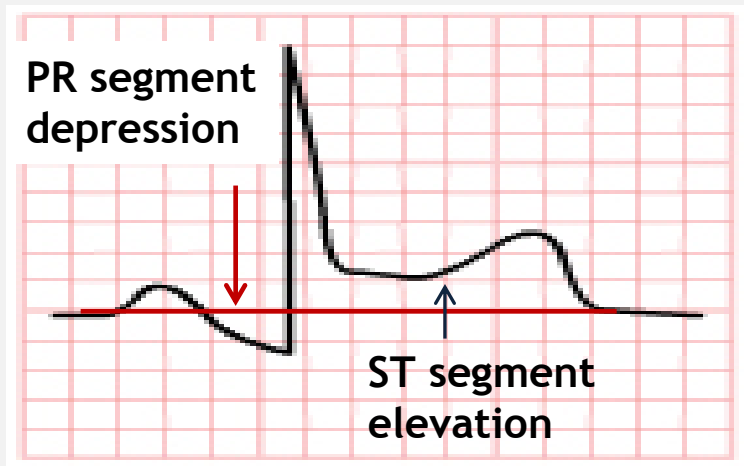


# PR interval, segment: key points



- Is the PR interval present?
- Is its duration normal/shortened/widened?
- Is the duration of PR interval constant before each QRS complex?
- Is there the PR segment depression/elevation?

# PR segment depression, elevation



- PR segment below isoline indicate PR segment depression;
- PR segment above isoline - PR segment elevation

# PR interval, segment abnormalities



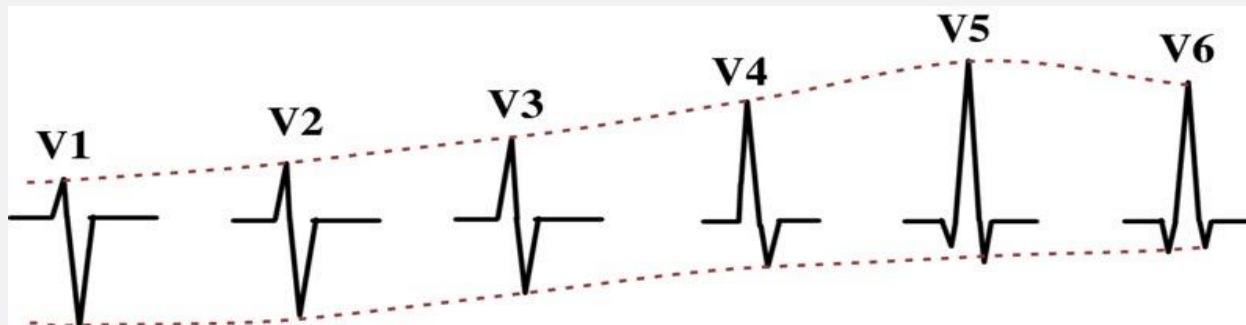
- Short PR interval: WRW (Wolff-Parkinson-White syndrome, Lown-Ganong-Levine syndrome, other causes - Duchenne muscular dystrophy, type II glycogen storage disease (Pompe's), HOCM)
- Long PR interval: AV block first degree, trifascicular block
- Changing duration of PR interval: AV block second degree
- PR segment depression/elevation: acute pericarditis, atrial infarction;

# Normal QRS complex features



- Normal physiological Q wave in I, II, aVL, aVF, V5, V6 is  $< 0,03$  sec, in V4  $< 0,02$  sec.
- The appearance of Q wave in V1-V3 is abnormal.
- Duration of the QRS-complex is 0,06 - 0,1 sec.
- R wave progression: the pattern seen in the chest leads characterized by the change from the S wave being prominent (in V1 and V2) to the R wave being prominent (in V4, V5, V6) with transition point in V3 where QRS complex is biphasic.

Normal R wave progression



<https://download.e-bookshelf.de/download/0004/0666/71/L-X-0004066671-0020271024.XHTML/images/ec03f005b.jpg>

# QRS complex: key points



- Is the width of QRS complex normal/widened/narrowed?
- Are there any pathological Q waves?
- Are there any Delta waves present?
- Is the amplitude (voltage) of QRS complex normal/high/low?
- Is there changing amplitude of QRS complex from beat to beat?
- Is there normal R wave progression in precordial leads?



# Low vs. high voltage QRS



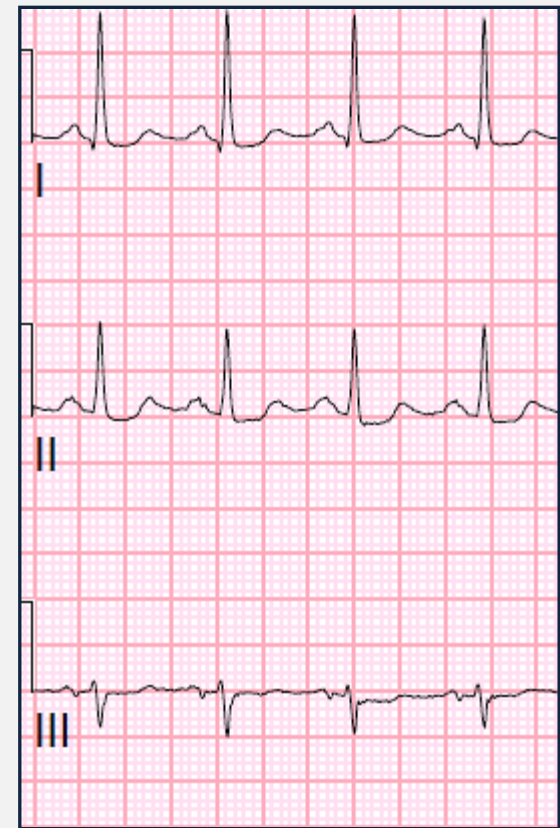
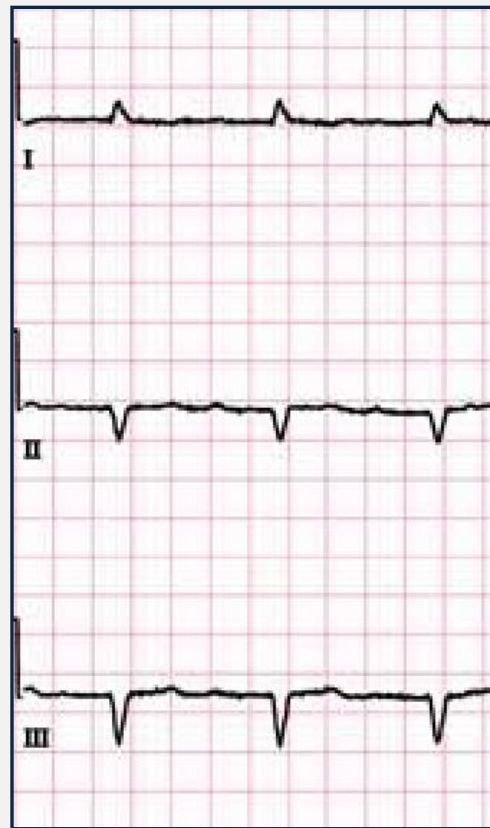## Low voltage QRS:

- The amplitudes of the QRS complexes in the limb leads are  $< 5$  mm; or in the precordial leads  $< 10$  mm;

## High voltage QRS:

- R in V5 or V6 + S in V1 or V2  $> 35$  mm;
- R in aVL  $> 11$ mm;
- R in II, III, aVF  $\geq 20$  mm;
- R in V5 or V6  $> 26$  mm

## Low voltage QRS    High voltage QRS



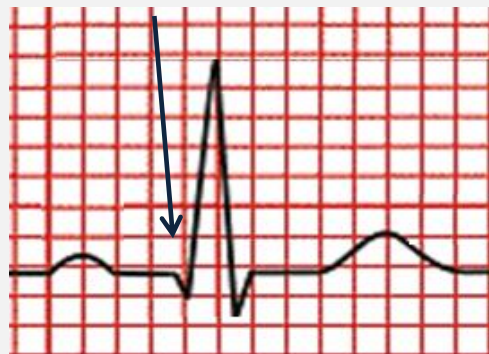
# Pathological Q wave features



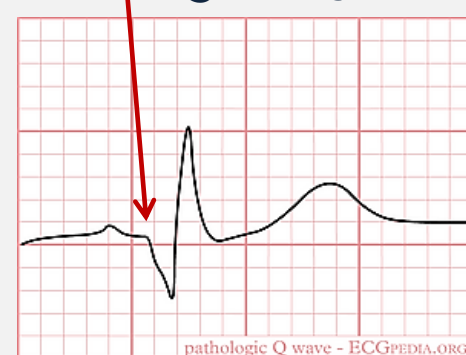- The depth of the pathological Q wave should be at least 25% of the depth of the associated R wave, duration  $>0,04$  sec.
- The Q wave should appear in at least 2 contiguous leads
- Any Q wave in leads V1- V3 with a duration of  $>0,02$  seconds is likely to be pathological.

**NB!** “Apparently pathological Q waves ” may have a tiny R-deflection preceding them indicating that there is no Q wave at all.

Physiological Q wave



Pathological Q wave



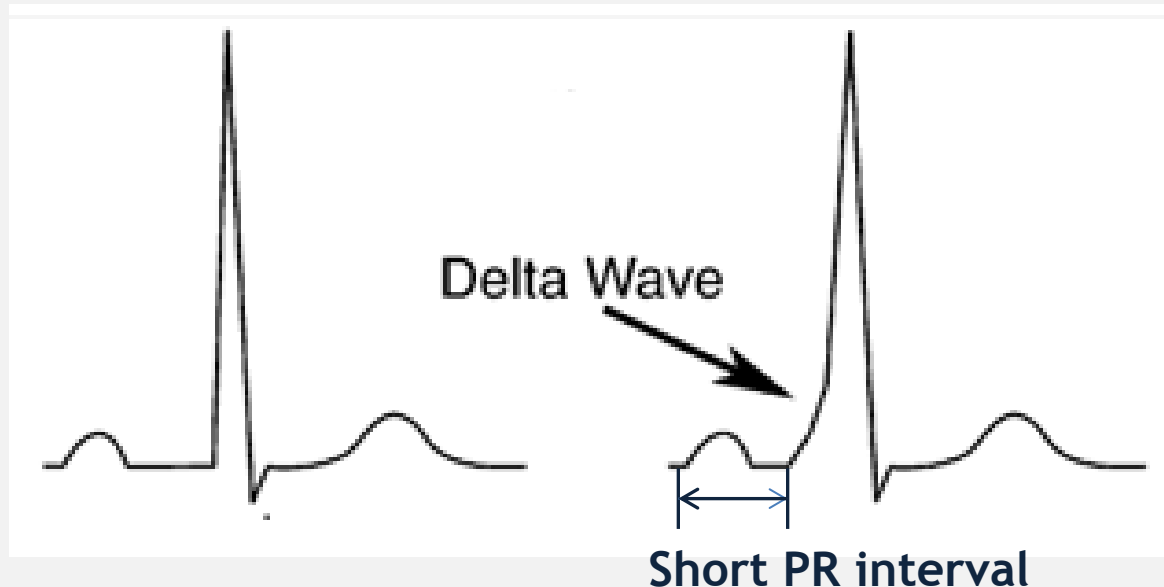
# The Delta wave



The Delta wave is a slurred upstroke in the QRS complex often associated with a short PR interval. It is most commonly associated with pre-excitation syndrome such as WPW.

Normal QRS

QRS with Delta wave  
(WPW syndrome)



# QRS complex abnormalities



- Narrow QRS complex: supraventricular rhythms;
- Wide QRS complex: bundle branch block, ventricular extrasystoles, ventricular rhythm, ventricular tachycardia, pacemaker with ventricular stimulation, WPW (Wolff-Parkinson-White syndrome), hyperkalemia, drugs (e.g. tricyclic antidepressants);

**NB!** A QRS duration  $> 0,1$  sec is abnormal (delayed conduction through the ventricles, incomplete block of bundle of Hiss), a QRS duration  $> 0,12$  sec is required for the diagnosis of bundle branch block or ventricular rhythm

# QRS complex abnormalities



- High amplitude of the QRS complex: ventricular hypertrophy (arterial hypertension, cardiomyopathy, athletes heart), thin chest wall in young adults;
- Low amplitude of the QRS complex: pericardial, pleural effusion, emphysema, pneumothorax, previous massive MI, advanced dilated cardiomyopathy, infiltrative/connective tissue diseases (restrictive cardiomyopathy, amyloidosis, scleroderma etc.);
- Abnormal R wave progression: right and left ventricular hypertrophy, MI, cardiomyopathy, dextracardia;
- Delta wave: pre-excitation syndrome (WPW);

# QRS complex abnormalities



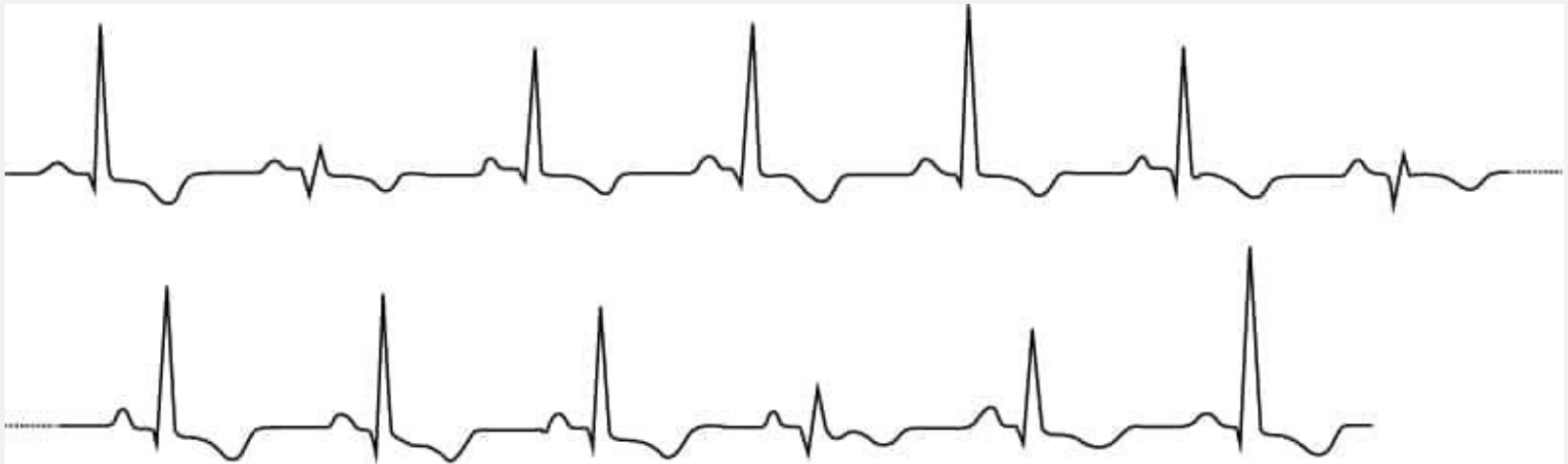- Pathological Q wave: MI; abnormal Q waves also may be seen in pneumothorax, hypertrophic cardiomyopathy, amyloidosis, myocarditis, etc.
- Changing amplitude of the QRS complex from one beat to another (electrical alternans): Wolff-Parkinson-White syndrome, rheumatic heart disease, acute pulmonary embolism, myocardial contusion, left ventricular dysfunction; if electrical alternans of QRS complex is associated with changing amplitude of P and T waves (total electrical alternans): cardiac tamponade, pericardial effusion, hypertrophic cardiomyopathy



# Practical part



- Evaluate characteristics of the QRS complex on the ECG below.



# Practical part



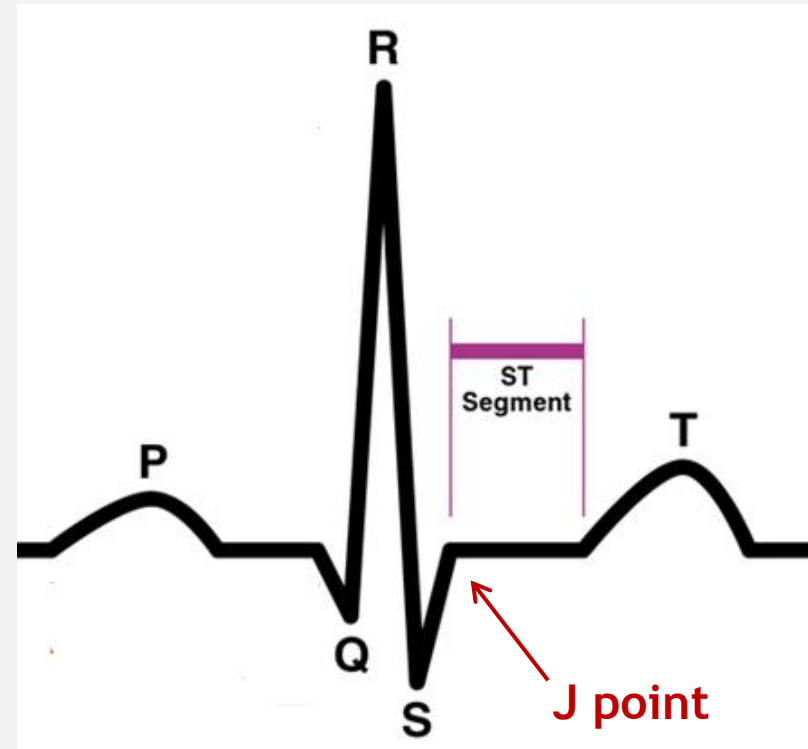
- ECG shows varying amplitude of the QRS complex from beat to beat (note that the T wave amplitude is also different)
- It is total electrical alternans in patient with cardiac tamponade



# Normal ST segment features



- The ST segment is the flat, isoelectric section between the end of the S wave (the J point) and the beginning of the the T wave.
- The transition from the ST segment to the T wave is smooth, not abrupt.
- Duration of ST segment is not so important, but its deviation from the isoline has a clinical value;



# Normal T wave features



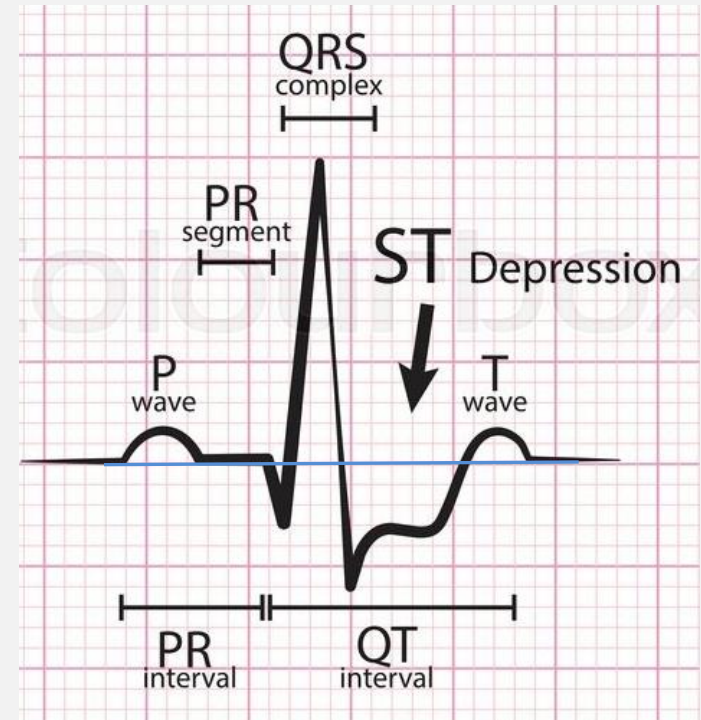
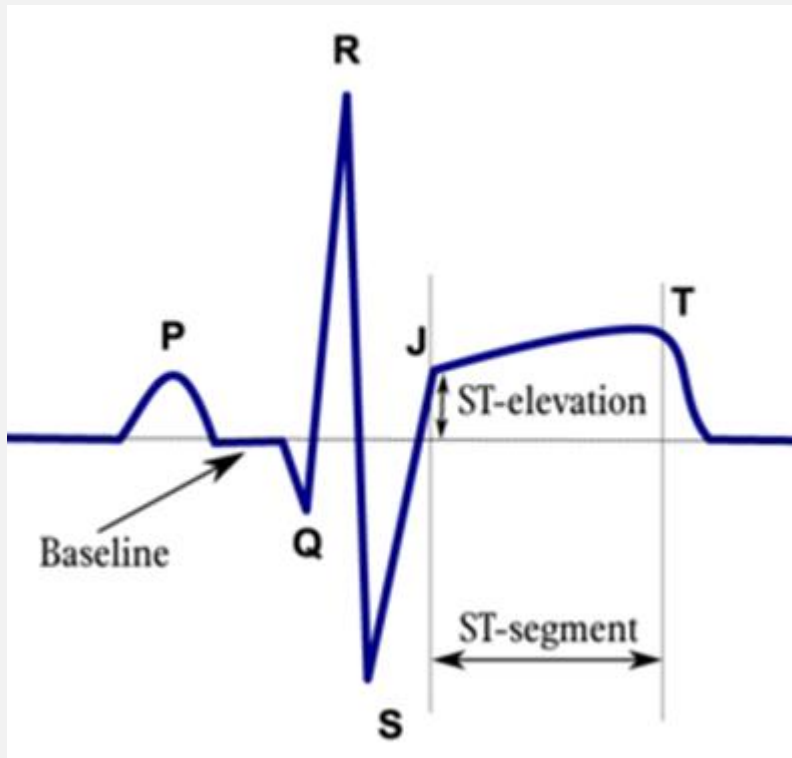
- T wave is always upright in I, II, V4-V6 and inverted in aVR; it may be inverted in V1 too;
- The amplitude of a normal T wave is one third to two thirds that of the corresponding R wave. The highest amplitude of the T wave is usually seen in V2-V3;
- T wave usually corresponds with R waves - positive QRS complex is followed with positive T wave.
- Changes in the ST segment are frequently accompanied with the T wave changes due to its electrophysiological relation and is called ST-T changes.

# ST-T changes: key points



- Is the ST segment on the isoline/elevated/depressed?
- What are the characteristics of the ST elevation (convex/upsloping/downsloping/horizontal/concave)?
- Are the T waves positive/flattened/inverted/ biphasic?
- Does the amplitude of T wave correspond with amplitude of the R wave?
- Is there ST elevations with simultaneous ST depressions in the electrically opposite leads in one ecg strip?
- Are the ST-T changes associated with wide bizarre QRS complexes?

# ST elevation/ST depression



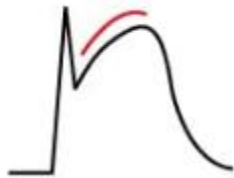
- ST elevation: the J point is displaced above baseline.
- ST depression: the J point is displaced below baseline.

# ST elevation characteristics




## Ischemic ST elevation types

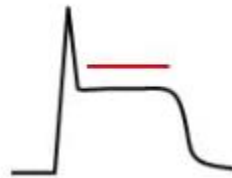Convex



Straight upsloping



Straight horizontal



Straight downsloping



- Usually are present convex, straight ST segment elevations, straight downsloping ST elevation is unusual;
- ST segment tends to merge imperceptibly with the T wave
- There is usually reciprocal ST depression in the electrically opposite leads.

## Non-ischemic ST elevation type

Concave



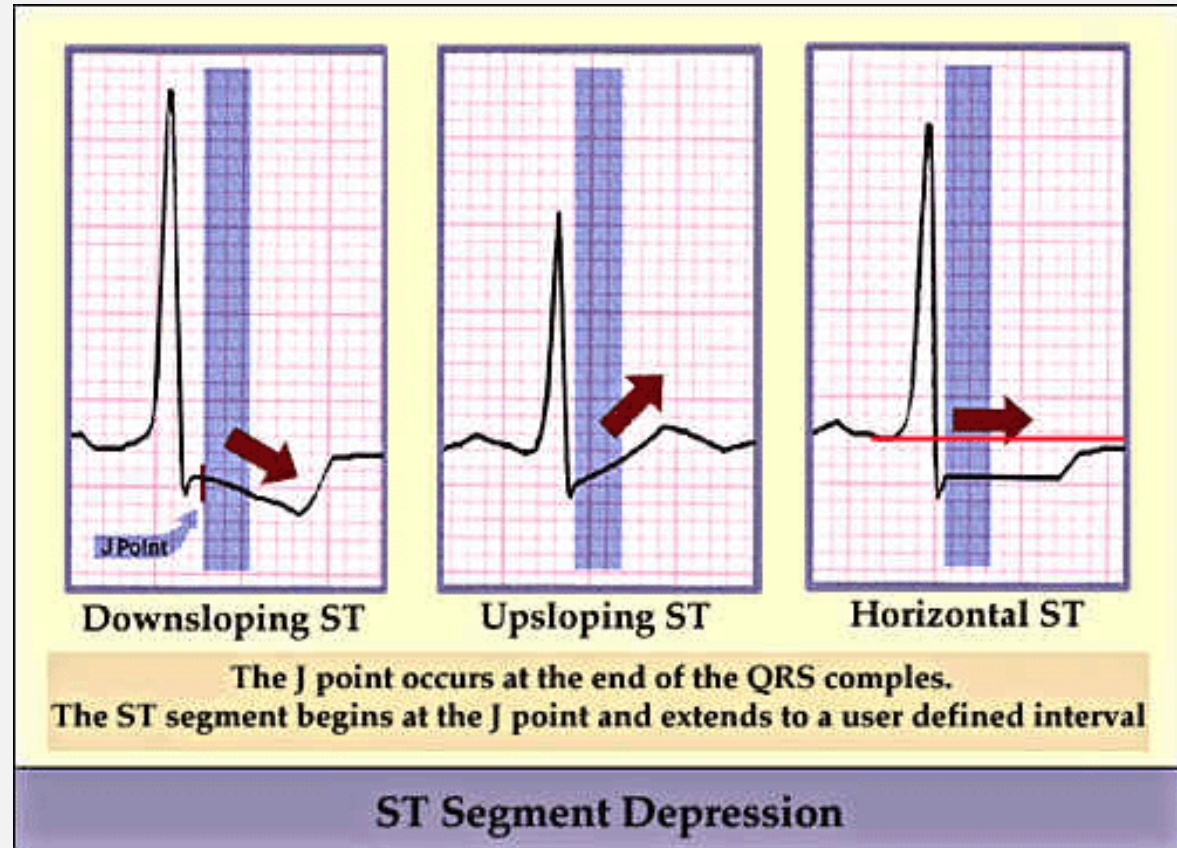
- Concave ST segment,
- not merged with T wave,
- T wave maintain its independent waveform



# ST depressions characteristics



- ST depression less than 0,5 mm is accepted as normal in all leads;
- ST depression more than 0,5 mm in two contiguous leads is abnormal



# ST segment abnormalities



- ST segment elevation: acute MI, Prinzmetal's angina, pericarditis, benign early repolarization, LBBB, non-specific BBB, left ventricular hypertrophy, ventricular extrasystoles, WPW, hyperkalemia, etc.
- ST segment depression: myocardial ischaemia, MI, supraventricular tachycardia, heart failure, ventricular hypertrophy, LBBB, digoxin effect, PE, etc.

# T wave abnormalities



- High amplitude of T waves: hyperkalemia, hyperacute T waves in early stages of MI;
- Flattened and inverted T waves: hyperventilation, anxiety, drinking iced water, neurocirculatory dystonia, ischemia, postischemic T waves, after MI, reperfusion (PCI), bundle branch blocks, pre-excitation syndrome, ventricular hypertrophy;

# Normal QT interval features

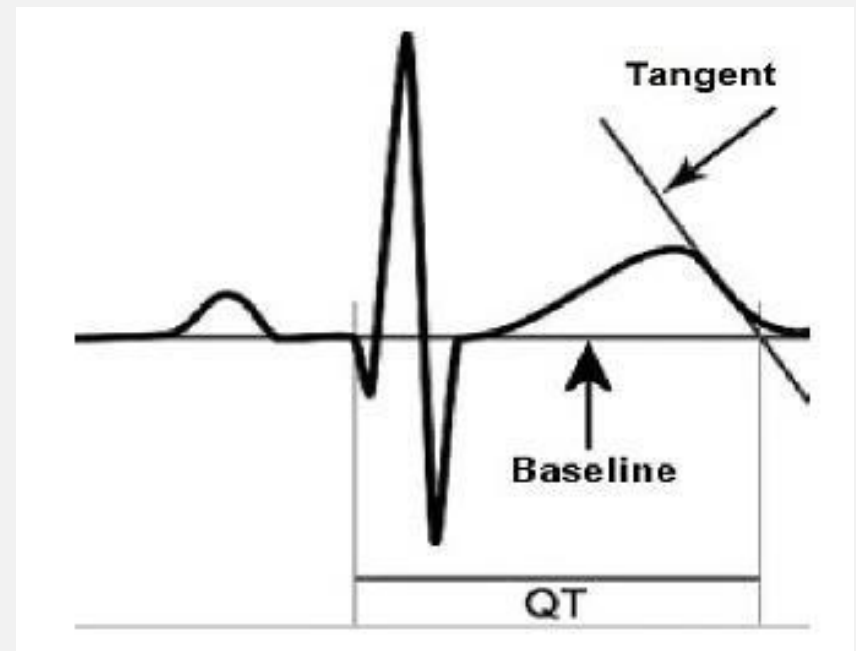


- The duration of QT interval is  $< 440\text{ms}$  in men,  $< 460\text{ms}$  in women;
- QT interval duration is related to the heart rate - the slower is the heart rate - the longer is QT interval and vice versa;
- $\text{QTc} = \text{measured QT} / \sqrt{\text{RR}}$  (in seconds);
- QTc interval allows comparison of QT values over time at different heart rates and improves detection of patients at increased risk of arrhythmias;
- $\text{QTc} > 500\text{ms}$  is associated with increased risk of torsades de pointes;
- QTc is abnormally short if  $< 350\text{ms}$ .

# QT interval measurement



- The QT interval should be measured in lead II or V5-V6;
- Several successive beats should be measured, with the maximum interval taken;
- The end of the T wave is defined as the intercept between the isoelectric line with the tangent drawn through the maximum down slope of the T wave;
- R-R interval is used in calculation of QTc interval.



# QT interval: key points



- Is QT interval normal/shortened/prolonged?
- What is the value of QTc?

# QT interval abnormalities



- Prolonged QT interval: congenital prolonged QT syndrome, drugs (antiarrhythmic- sotalol, amiodarone, procainamide, etc.; tricyclic antidepressants, lithium, etc.; antibiotics: macrolides, etc.); hypokalemia, hypocalcemia, hypothermia, hypothyroidism, bradycardia, etc.

**NB!** Prolonged QT interval may lead to life-threatening ventricular arrhythmias.

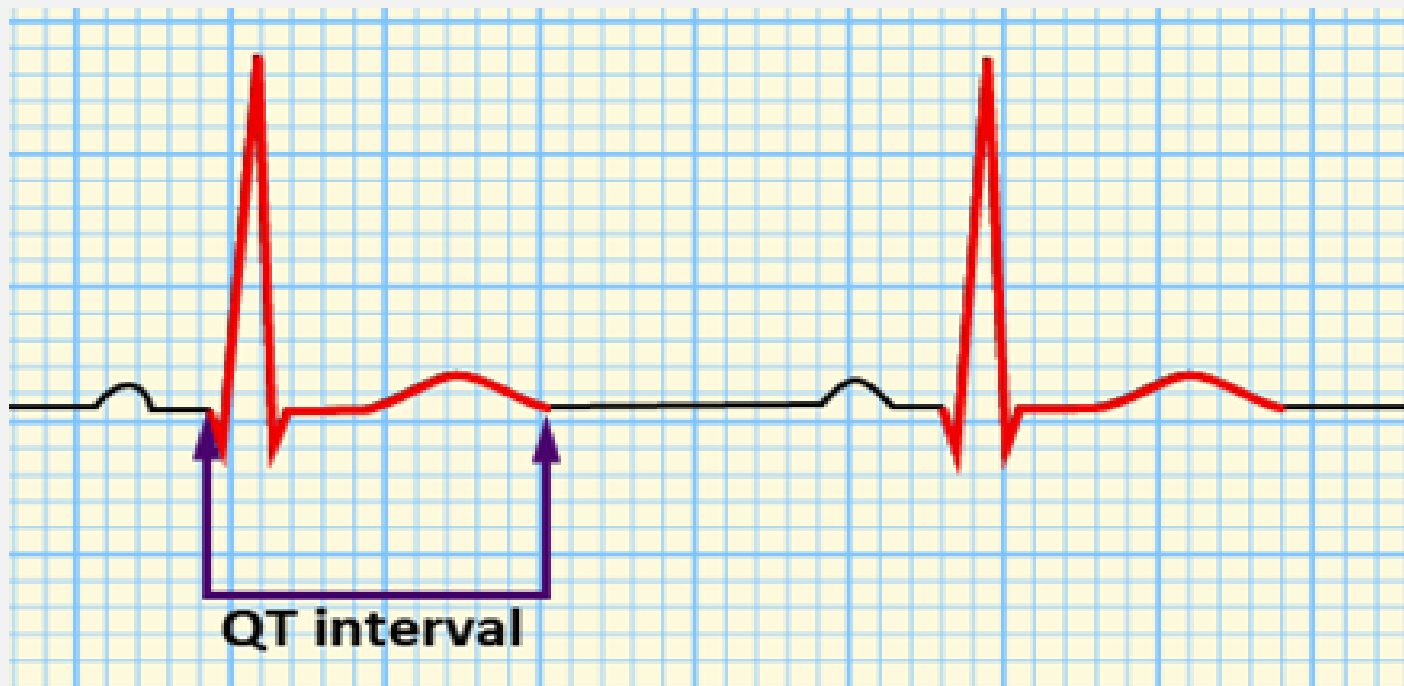
- Short QT interval: is uncommon, rarely may be seen in hypocalcemia, may cause malignant arrhythmias.



# Practical part



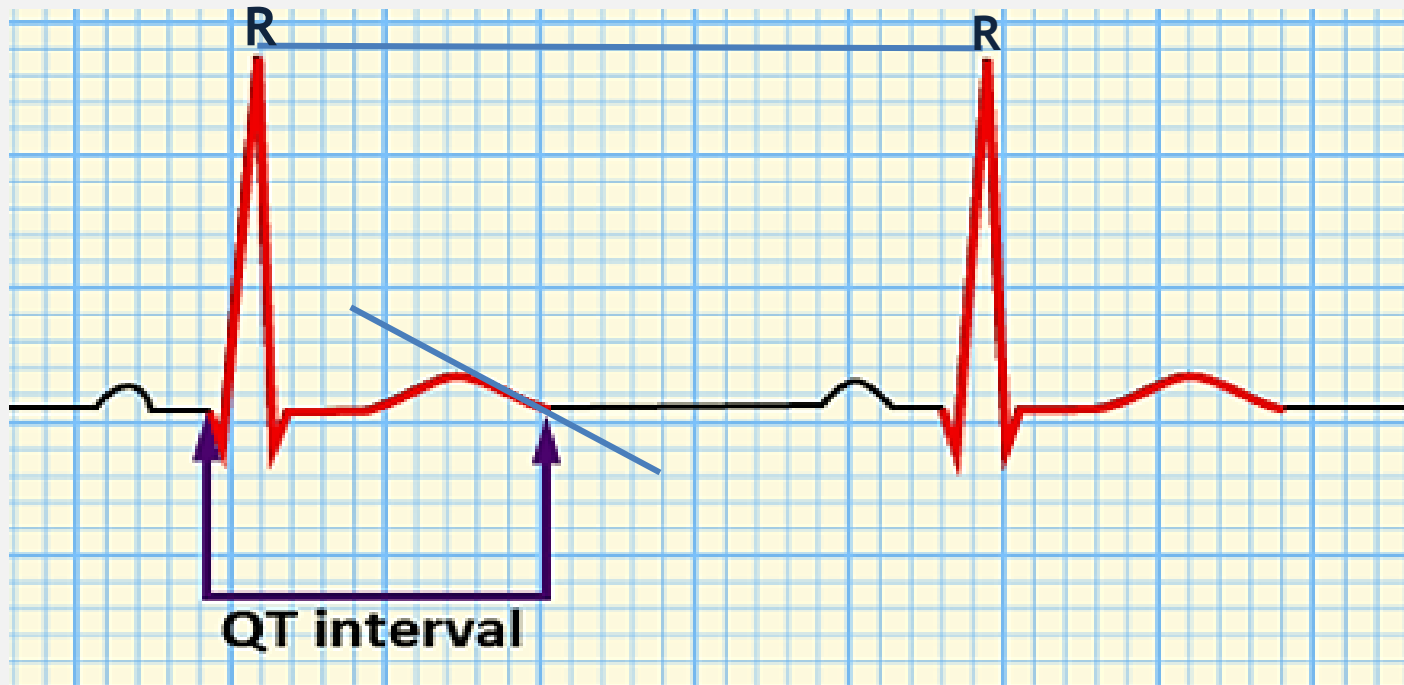
- Measure QT interval, QTc on this ECG strip



# Practical part



- R-R interval - 38 small squares \* 0,04=1,52s,
- QT interval - 11 small squares \* 0,04 = 0,44sec
- QTc =  $0,44 / \sqrt{1,52} = 0,44 / 1,23 = 0,357 = 0,36\text{sec}$



**Thank you for your  
attention!**

