

Kharkiv Karazin National University
Faculty of Medicine
Department of Internal Medicine

Myocardial bridge: clinical case (Coronary stenting for symptomatic myocardial bridging)

Reporter: 6-th course students-Awotunde Akinwumi G, Afolabi Omotolani B
Supervisors: MD Shmidt E.Y., MD Medved E.P, PhD Abdueva F.M., Head of the
Department of Internal MedicineProfessor Yabluchansky N.I.

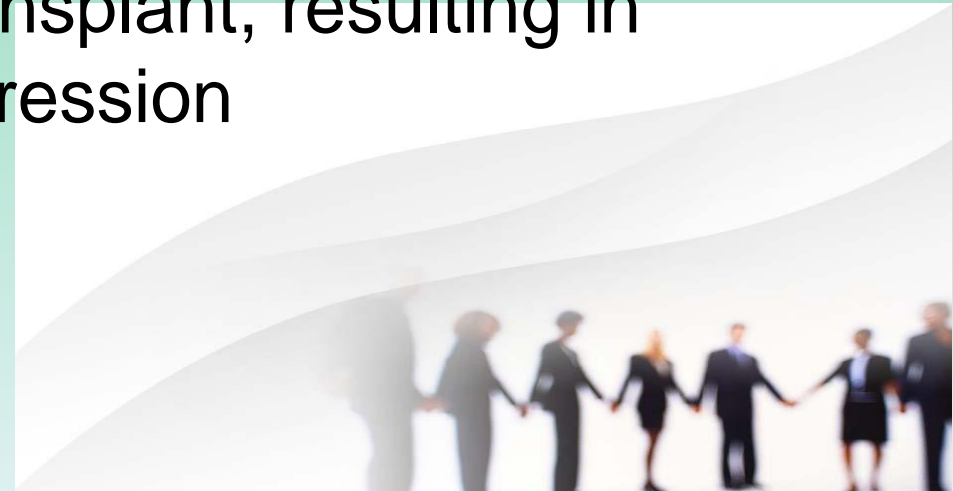Definition

- Myocardial bridge is defined as a segment of the major coronary artery running intramurally through the myocardium, deviating from its usual epicardial course.
- Synonyms: (intramural coronary artery, mural coronary artery, coronary overbridging, myocardial loop)
- First described anatomically by Reyman in 1737

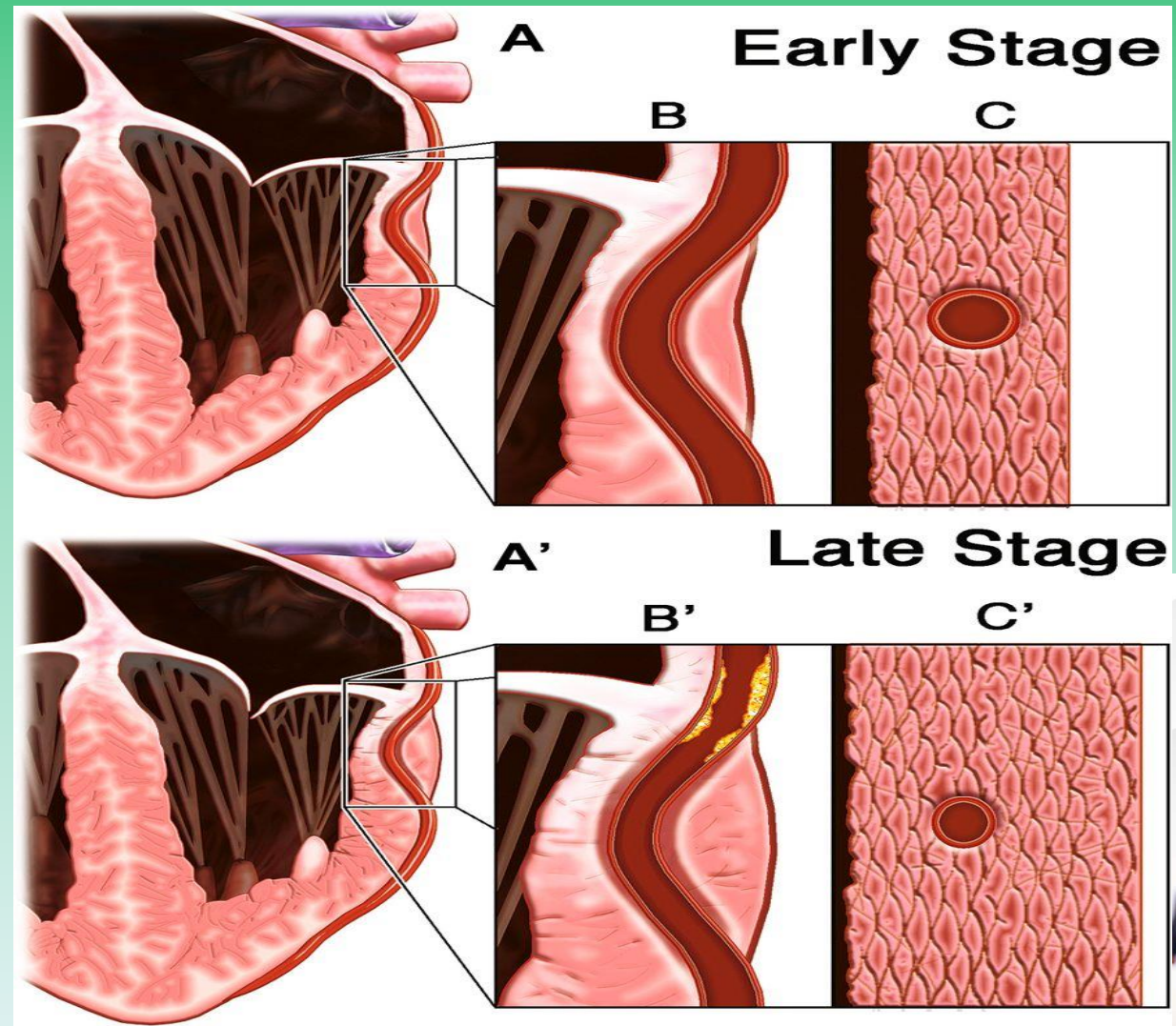


Etiology

- congenital anomaly of the coronary arteries
- rates much higher than the general population in the following conditions:
 - hypertrophic cardiomyopathy patients
 - heart transplant patients: related to the increased stiffness and hypertrophy of the myocardium post transplant, resulting in increased rates of systolic vessel compression



- Schematic Diagram of the Effects of Aging on the Myocardial Bridge **(A)** Heart with myocardial bridging, early stage. **(B)** Longitudinal view of the bridged vessel. **(C)** Cross-sectional view of the vessel in the middle of the myocardial bridge. **(A')** Heart with myocardial bridging, late stage, with ventricular hypertrophy and diastolic dysfunction. **(B')** Longitudinal view of the bridged vessel, with hypertrophied muscle and plaque progression proximal to the bridge. **(C')** Cross-sectional view of the vessel in the middle of the myocardial bridge showing hypertrophied muscle and negative remodeling of the vessel with decreased lumen diameter.

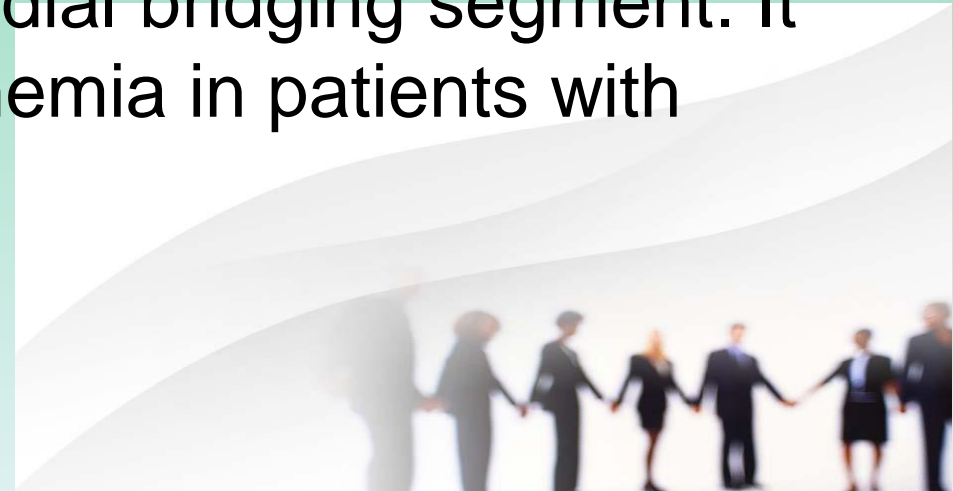

Pathogenesis

- The myocardial bridge causes coronary artery narrowing during systole therefore myocardial bridges should not compromise blood supply to the musculature during diastole.
- Systolic narrowing at the myocardial bridging segment may result in endothelial damage, which may provoke platelet aggregation, coronary vasospasm and eventually acute coronary syndrome

Pathogenesis

- the vessel segment proximal to the bridge appears to develop atherosclerosis at increased rates, approaching 90% rather than the myocardial bridging segment itself . Research has shown vasoactive agents (endothelin-1, endothelial nitric oxide synthase and angiotensin-converting enzyme) to be present in higher concentrations in the proximal portion of the myocardial bridging artery compared to the myocardial bridging segment. It can also be an alternative cause of ischemia in patients with myocardial bridging.



Pathogenesis

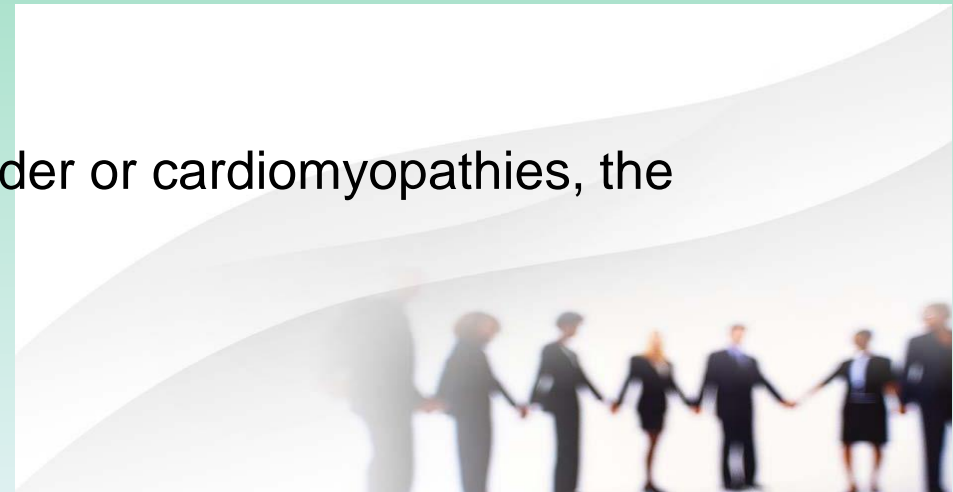
- Bridging is typically described for left anterior descending artery (LAD), with the mid LAD considered the most common location , however, other major coronary arteries can also be involved



Clinical Manifestations (Features)

- Symptomatic patients with myocardial bridging may present with
- myocardial ischemia,
- acute coronary syndromes,
- coronary spasm,
- exercise-induced dysrhythmias (such as supraventricular tachycardia, ventricular tachycardia, or atrioventricular block),
- myocardial stunning,
- transient ventricular dysfunction,
- syncope,
- sudden death.

When myocardial bridging is associated with heart valve disorder or cardiomyopathies, the patients' symptoms can be different.



Diagnosis

- Coronary angiography: The typical angiographic feature of a myocardial bridge is systolic narrowing of an epicardial artery, which is often completely resolved during the diastolic phase of the cardiac cycle.
- Intracoronary Doppler
- Echocardiography
- Electrocardiography
- Stress test with ECG
- Intravascular ultrasound
- Fractional flow reserve
- Cardiac computed tomography (CT) angiography



Prognosis

- Myocardial bridging is generally considered to be a benign condition, it has been proposed as a cause of angina-like chest pain, coronary spasm, myocardial ischemia, acute coronary syndromes, left ventricular dysfunction/stunning, arrhythmias (including supraventricular tachycardia and ventricular tachycardia), and even sudden cardiac death. Serious events are uncommon, and it is still controversial and unclear whether myocardial bridging can be directly attributed as the cause of the events



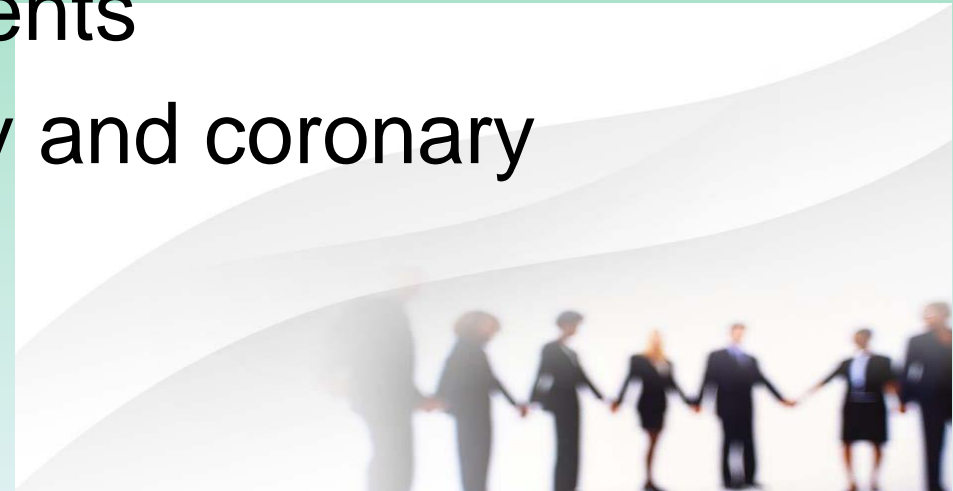Management

- Pharmacologic therapy:

First-line therapy: beta-blockers and non-dihydropyridine calcium-channel blockers (decreased chronotropy and inotropy i.e prolongation of diastole with reductions in heart rate)

–Nitrates are contraindicated in patients

- Surgical treatment: surgical myotomy and coronary stenting



Patient Identifying data

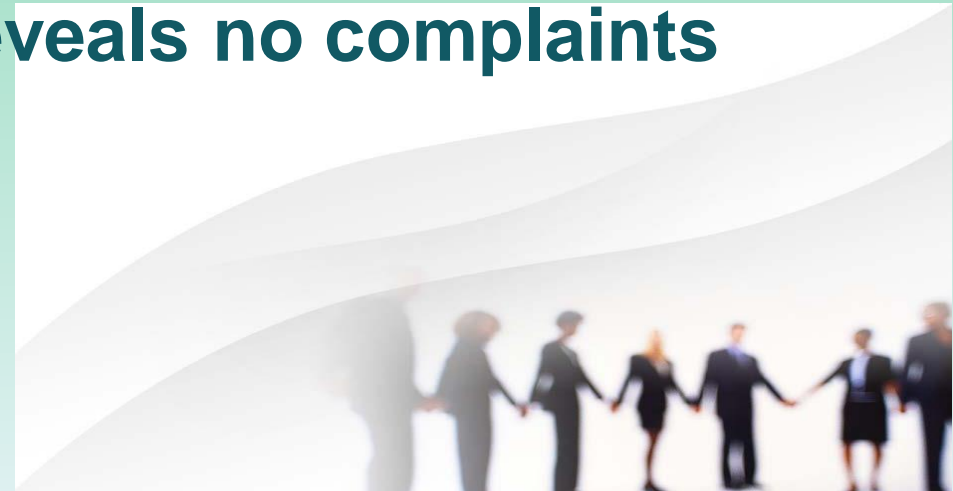- Age: 67 years old
- Sex: Female



Complaints

Main complaints:

- retrosternal pressing pain that occurs either after emotional stress or without clear connection with any provoking factors, relieves in rest
- Unstable blood pressure
- **Review of other organs and systems reveals no complaints**



History of the present disease

- She has been suffering from hypertension since the last 20 years. Maximum BP level (210/100 mmHg) was noticed 4 years ago when patient lost consciousness. The ambulance was called. No significant changes on ECG were revealed. After those incident she periodically hospitalized in CCH and received antihypertensive treatment (ampril 2,5 mg , bisoprolol 5 mg, fisiotens 0,4 mg) «Working» BP 140/80 mmHg,
- Since last year she has been suffering from retrosternal pain that occurs either after emotional stress or without connection with any provoking factors, relieves in rest without taking any medicines. The complaints on retrosternal pain brought patient to the hospital for examination and treatment



Life history

- No previous surgery
- No history of tuberculosis



Physical examination

- No physical abnormalities were detected by clinical examination and blood pressure was 140/80 mmHg (on the background of antihypertensive medication) , HR 61 bpm
- Respiratory rate: no significant changes
- Auscultation: clear vesicular sound
- Accentuated second sound over the aorta
- Abdomen without any changes
- Obesity of 1st degree



Day-night BP monitoring

No	Beginning	HR	Systolic BP	Diastolic BP
1	11:28:00	68	146	78
2	11:59:34	77	163	89
4	12:33:45	66	149	70
12	15:51:09	64	137	78
16	17:00:41	60	149	81
22	19:43:39	70	136	59
26	21:22:16	76	123	52
27	21:53:52	62	122	59
28	22:25:32	51	123	57
32	23:33:07	70	133	69
33	00:33:48	57	114	51
34	01:35:25	49	119	58
37	03:38:52	45	91	44
38	04:40:30	47	115	60
39	05:41:52	51	148	69
40	06:43:20	61	162	76
42	08:17:09	96	141	70

- BP monitoring was done on the background of antihypertensive drugs
- Changes for BP is typical for mild hypertension



Preliminary diagnosis

- Arterial hypertension stage II 3 degree. Hypertensive heart HF 0-1
- IHD.Stable angina
- Obesity 1 degree



Plan of investigation

- Minimum investigation:
 - Complete blood count
 - Urine analysis
 - Blood analysis (glucose, creatinine, lipid profile, total bilirubin, AST, ALT)
 - ECG
 - EchoCG
 - Coronary arteriography
 - Exercise treadmill test



Lipid profile/Blood test

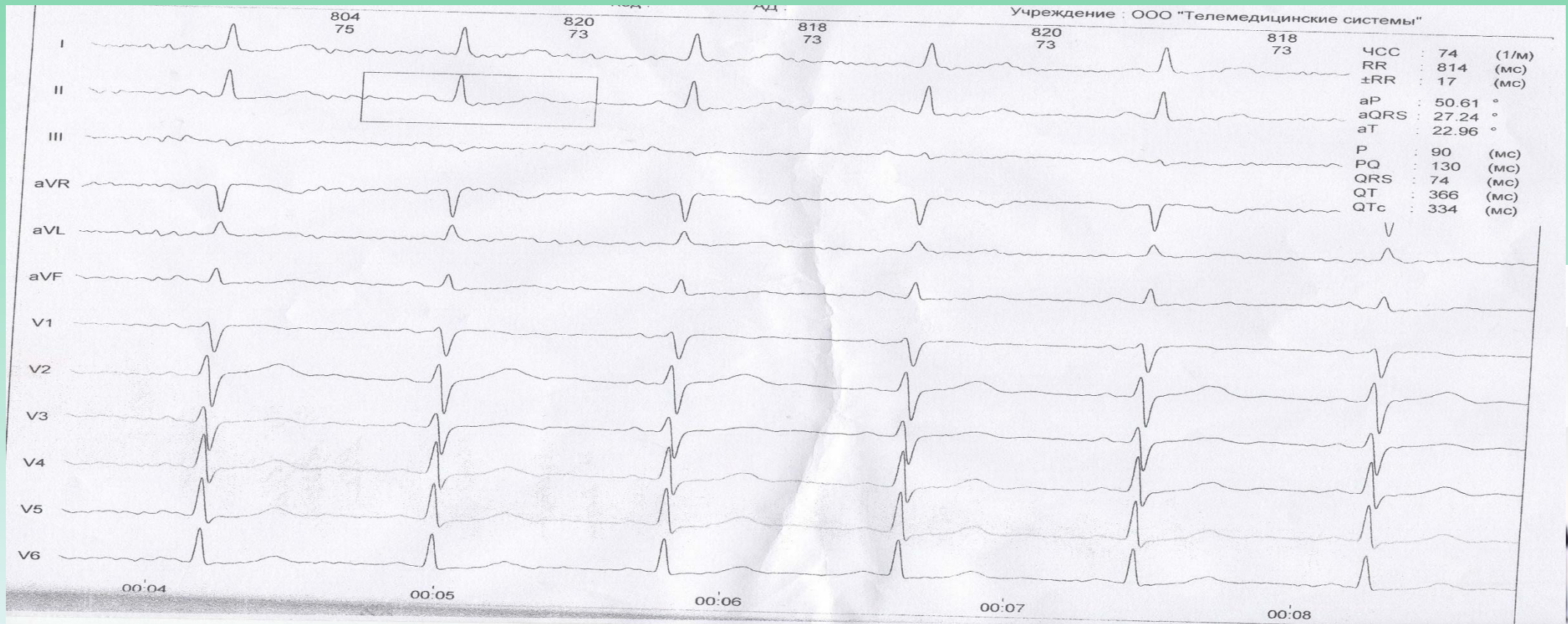
- triglycerides 3.3mmol/L (≤ 2.3)
- high density lipoprotein cholesterol 1.43mmol/L (≥ 0.9), total cholesterol 7.93 mmol/L (< 5.2),
- low density lipoprotein cholesterol 0.77 mmol/L (< 3.5),
- blood glucose 5.5 mmol/L (3.5-5.5)
- Atherogenic coefficient 4.54 (≤ 3)

All other blood tests also were normal



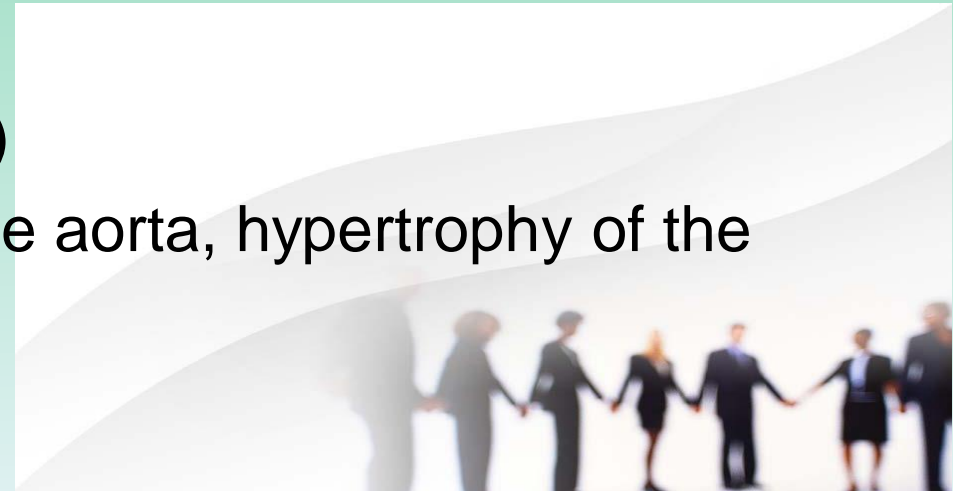ECG

- Conclusion : Sinus rhythm. Signs of left ventricular hypertrophy



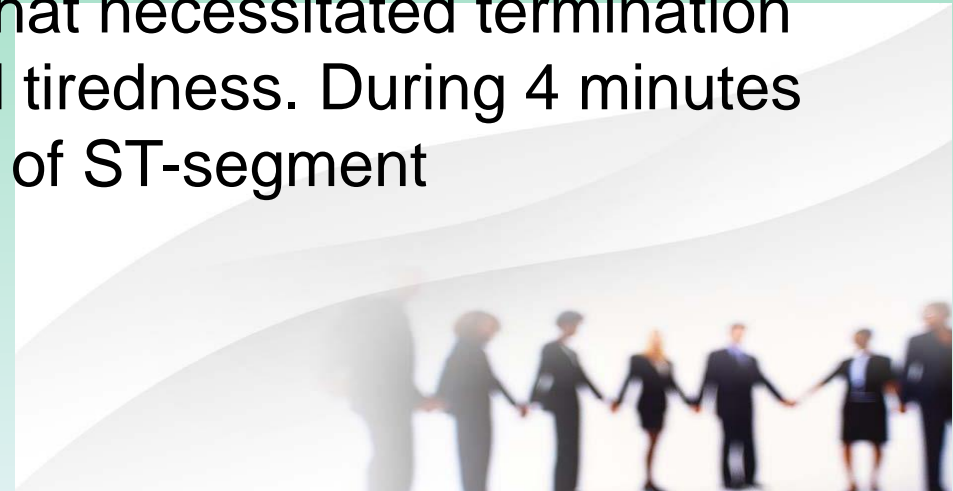
EchoCG

- Diameter of aorta 32mm(20-37mm)
- Mitral valve opening: 29mm(26-35mm)
- Left atrium: 32mm
- Left ventricle, end diastolic diameter: 40mm(35-55), end systolic diameter: 25mm(23-38mm), ejection fraction: 65%(55-78%), systolic fraction 34%(28-44%)
- Interventricular septum: 11.8mm(6-11mm)
- Right atrium:28mm, Right ventricle: 18mm(9-26)
- Thickness of LV posterior wall- 12.7 mm(6-11mm)
- Conclusion: there is atherosclerotic changes of the aorta, hypertrophy of the left ventricle



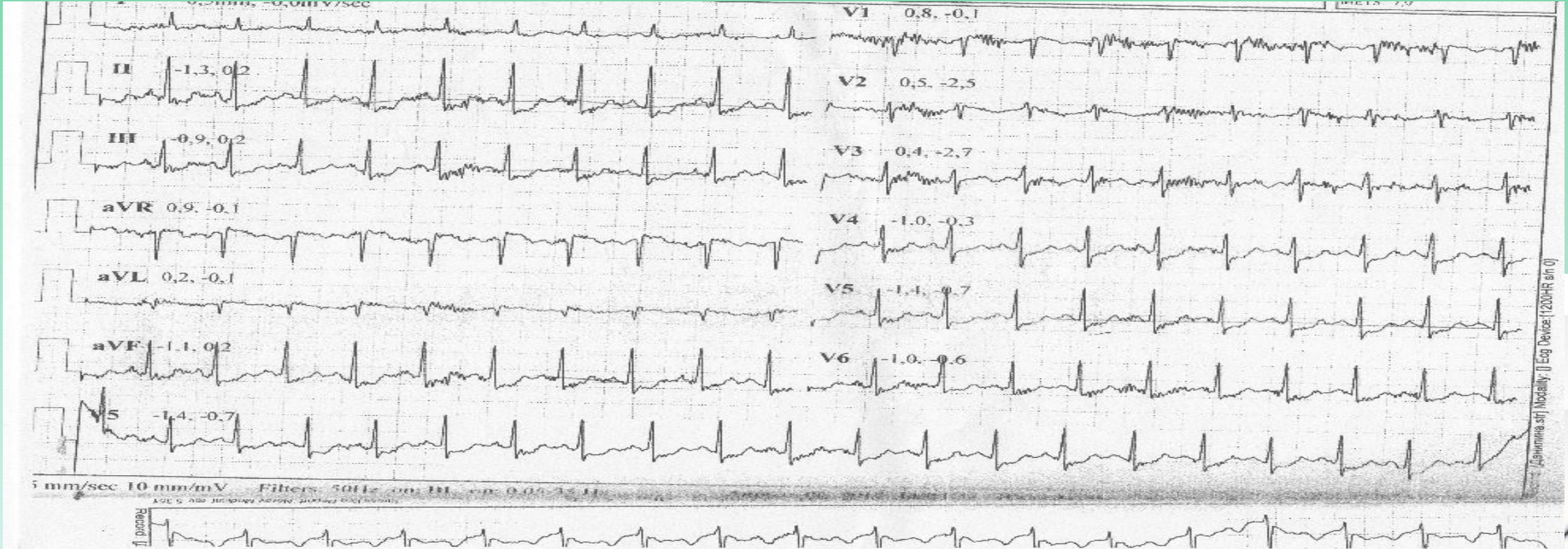
Exercise treadmill test

- While doing exercise treadmill test (protocol Bruce): blood pressure, heart rate and 12-leads ECG were recorded during several steps with increased physical exertions (from 4,6 METs). The ECG and ST-segment were continuously displayed and measured automatically by a computer-assisted system in all 12 leads.
- Max reached BP was 180/100 mmHg, max HR 127 bpm. At heart rate of 127 beat/minute (7,0METs), the ST segment showed progressive depression more then 1,0 mm in leads II, III, avf, V4,V5, V6 that necessitated termination of the test. The patient felt only mild dyspnea and tiredness. During 4 minutes of restitution period there was complete recovery of ST-segment
- Conclusion: test is positive.



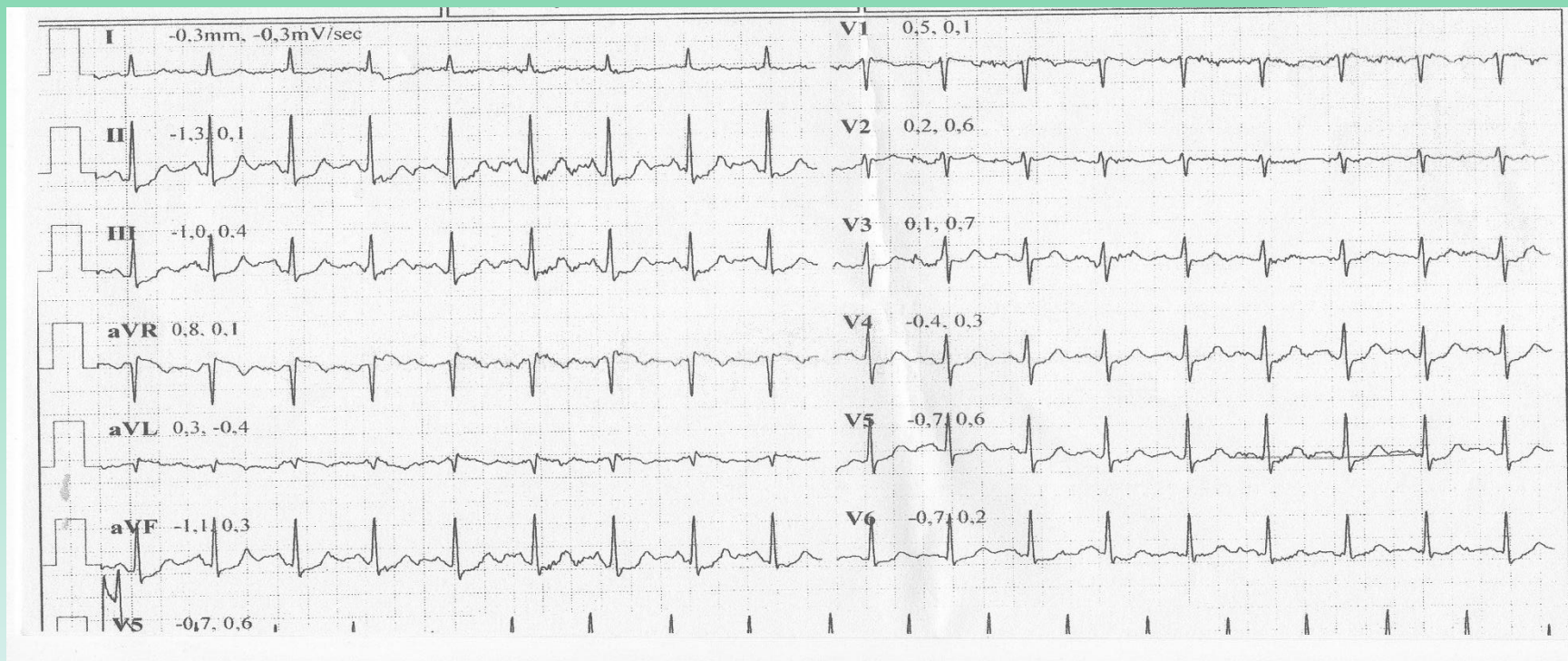
Exercise treadmill test: Maximum Exertion

- ST depression on V4-V6 and on lead II,III and aVF

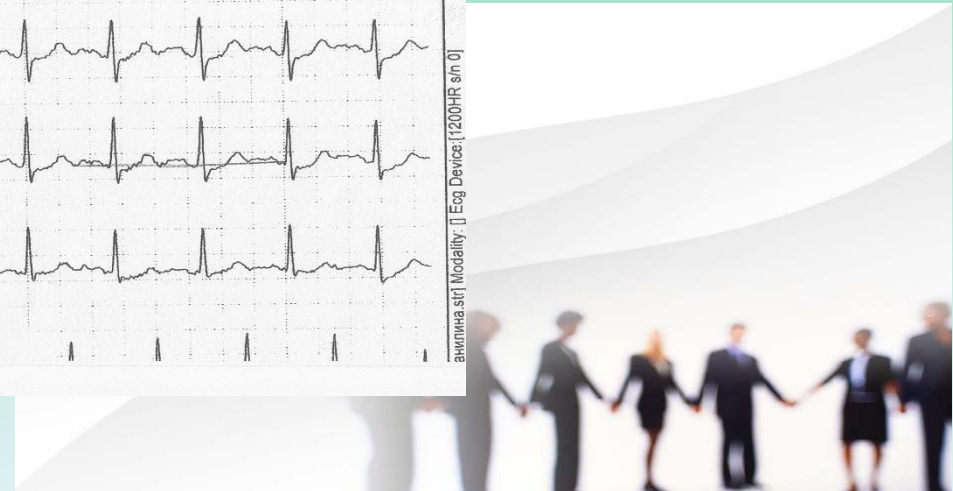

Exercise treadmill test: Recovery phase

- Observed changes were reversed



англ. ECG Device [1200HR sin 0]



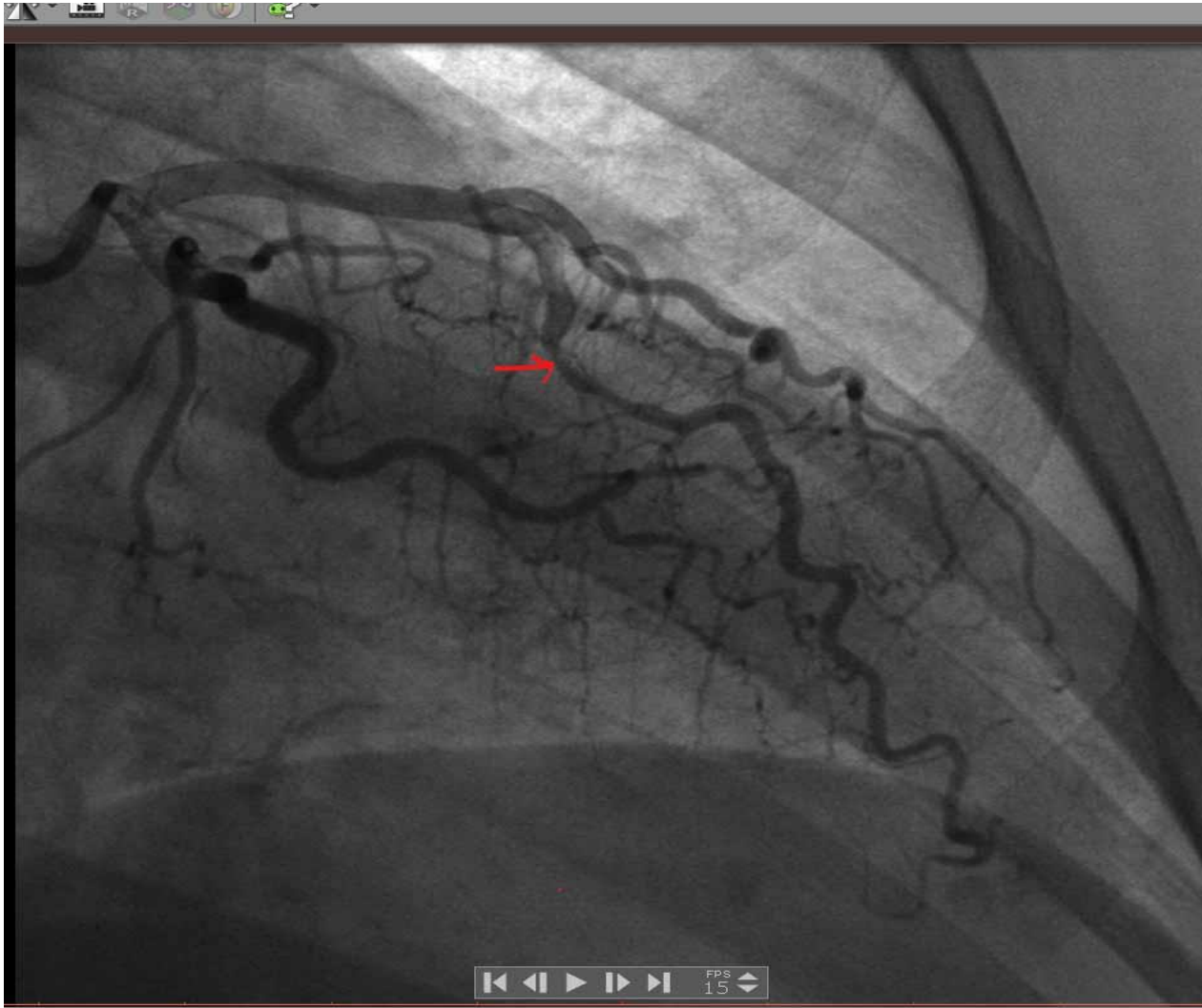Coronary angiography

- The right type of coronary blood supply. Significant coronary tortuosity. Left coronary artery - prolonged myocardium bridging in the middle segment of the left anterior descending coronary artery with systolic compression 90%.
- The circumflex artery branches of the left coronary artery and right coronary artery - with signs of atherosclerotic lesions without hemodynamic significance

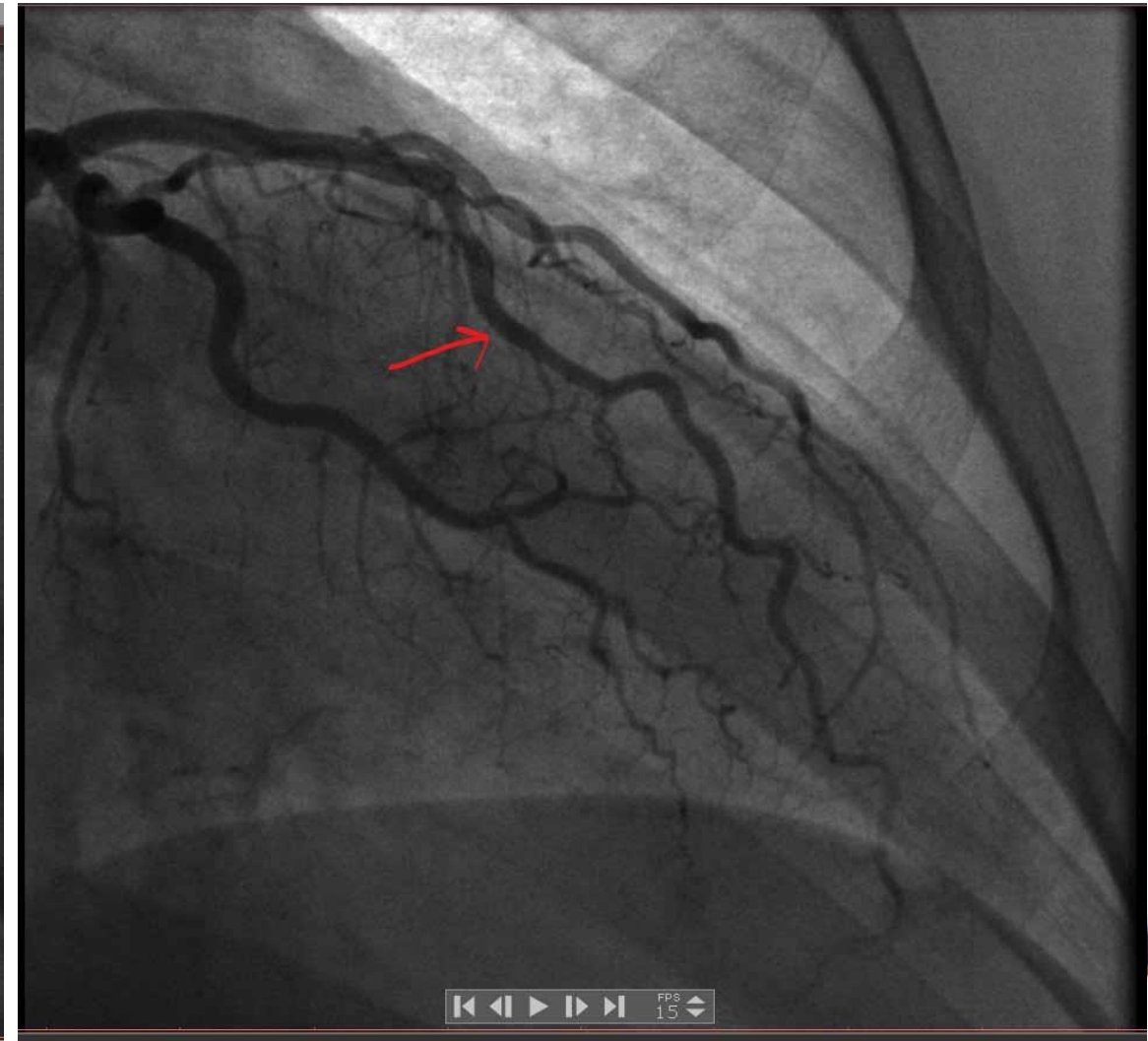


Compression of coronary artery in systole

systole



diastole



Im: 1/59
Se: 4

Danilina N P
166155
29.04.1945 F
CentralClinik Hospital Ukraine Zalznitsi
7.0.37772364

WL: 76 WW: 150 [D]
RAO: 30 CRA: 29

23.11.2012 9:22:08

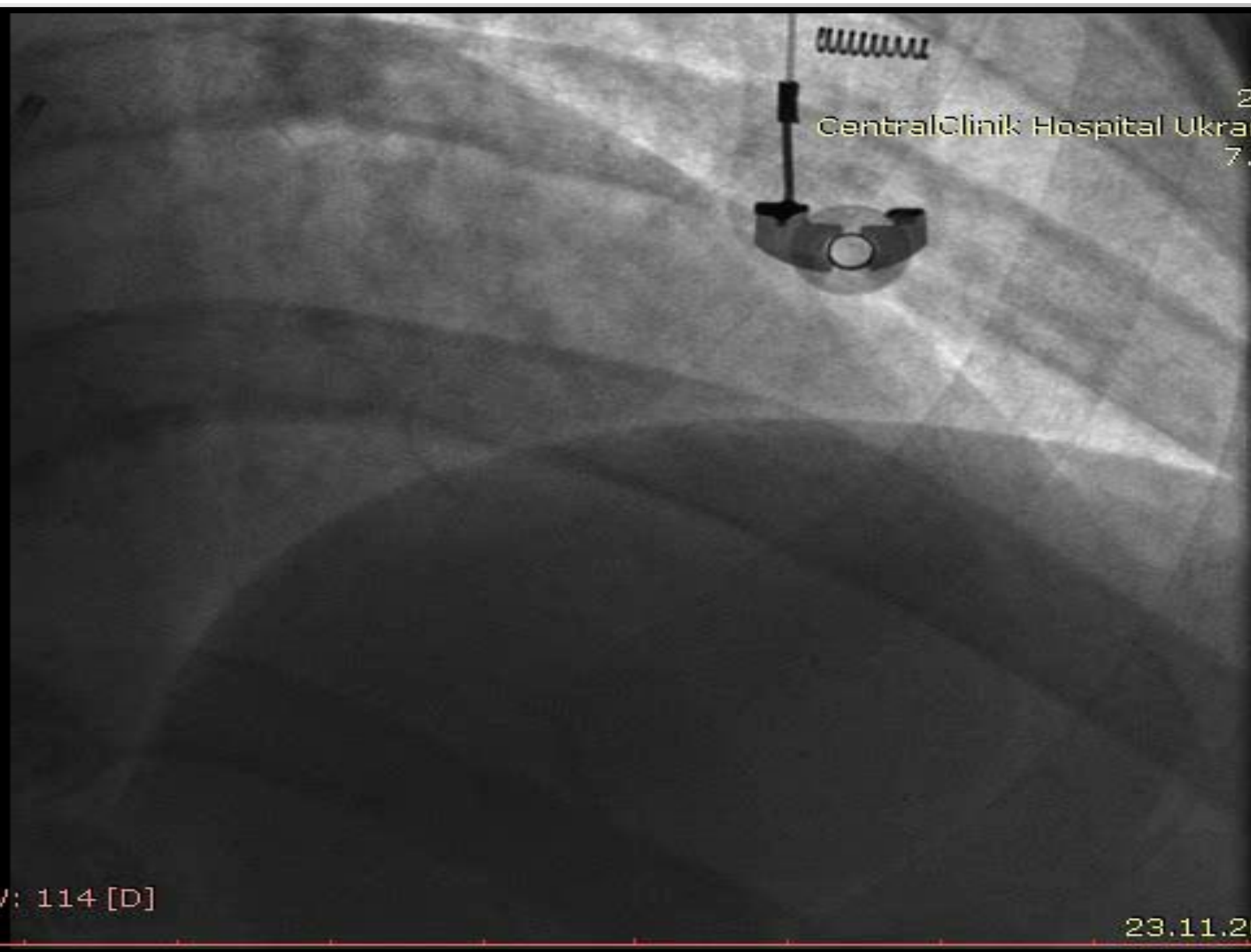

Im: 1/51
Se: 3

Danilina N P
166155
29.04.1945 F
CentralClinik Hospital Ukraine Zalznitsi
7.0.37772364

WL: 58 WW: 114 [D]
CRA: 29

23.11.2012 9:21:34



Clinical Diagnosis

- Main disease: Myocardial bridge of LAD with systolic compression 90%. Coronary stenting of LAD. HF 0-1. High risk.
- Concomitant diseases: Arterial hypertension II st 3degree. Hypertensive heart.

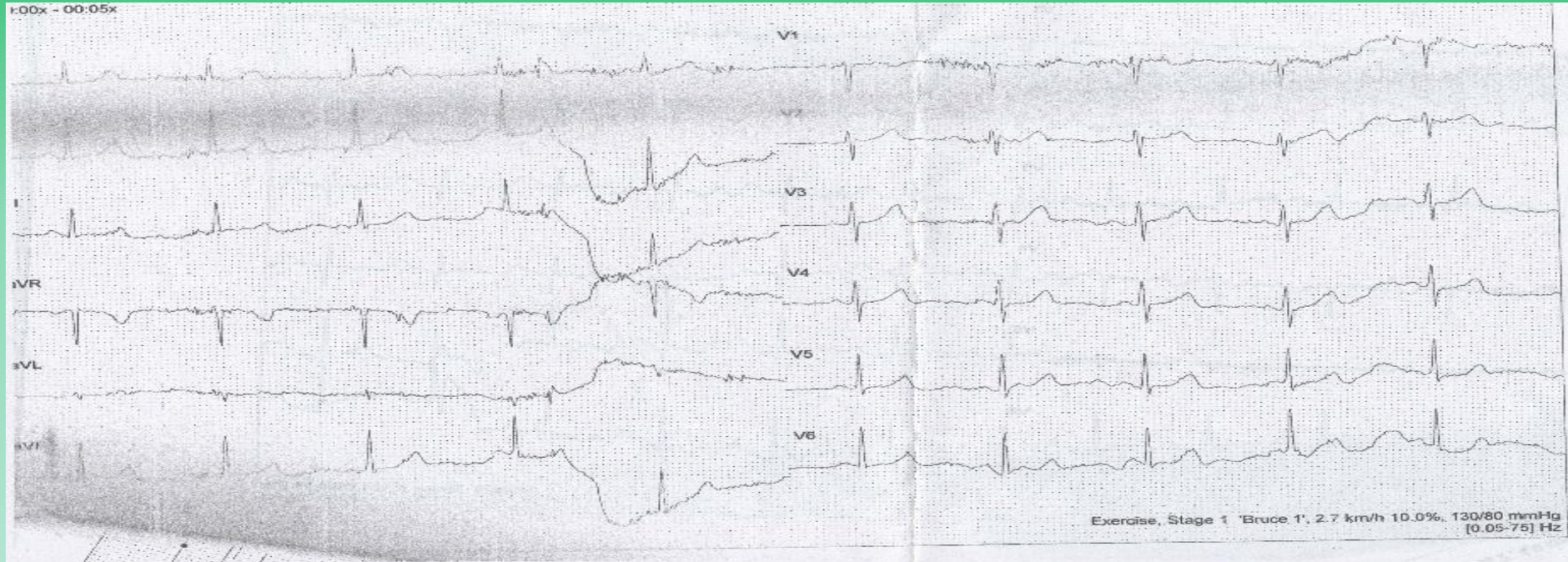


Treatment

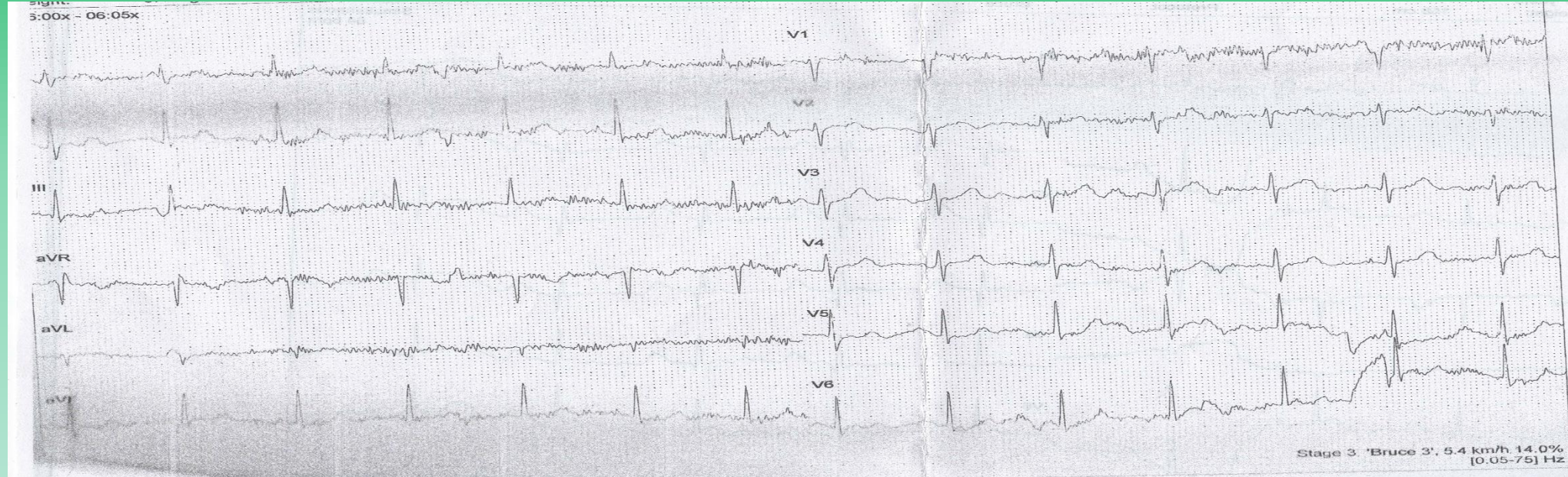
- Pharmacologic treatment before stenting:
ekvartor 20/10mg every evening,
physiotens 0.2mg daily,
amlodipine 5mg every evening,
korvaltab 1tab 2 times daily,
mildronat 10%,
cardiarginin 5.0 plus physiotens
- Surgical treatment: Coronary stenting



Treadmill after stenting(early phase)



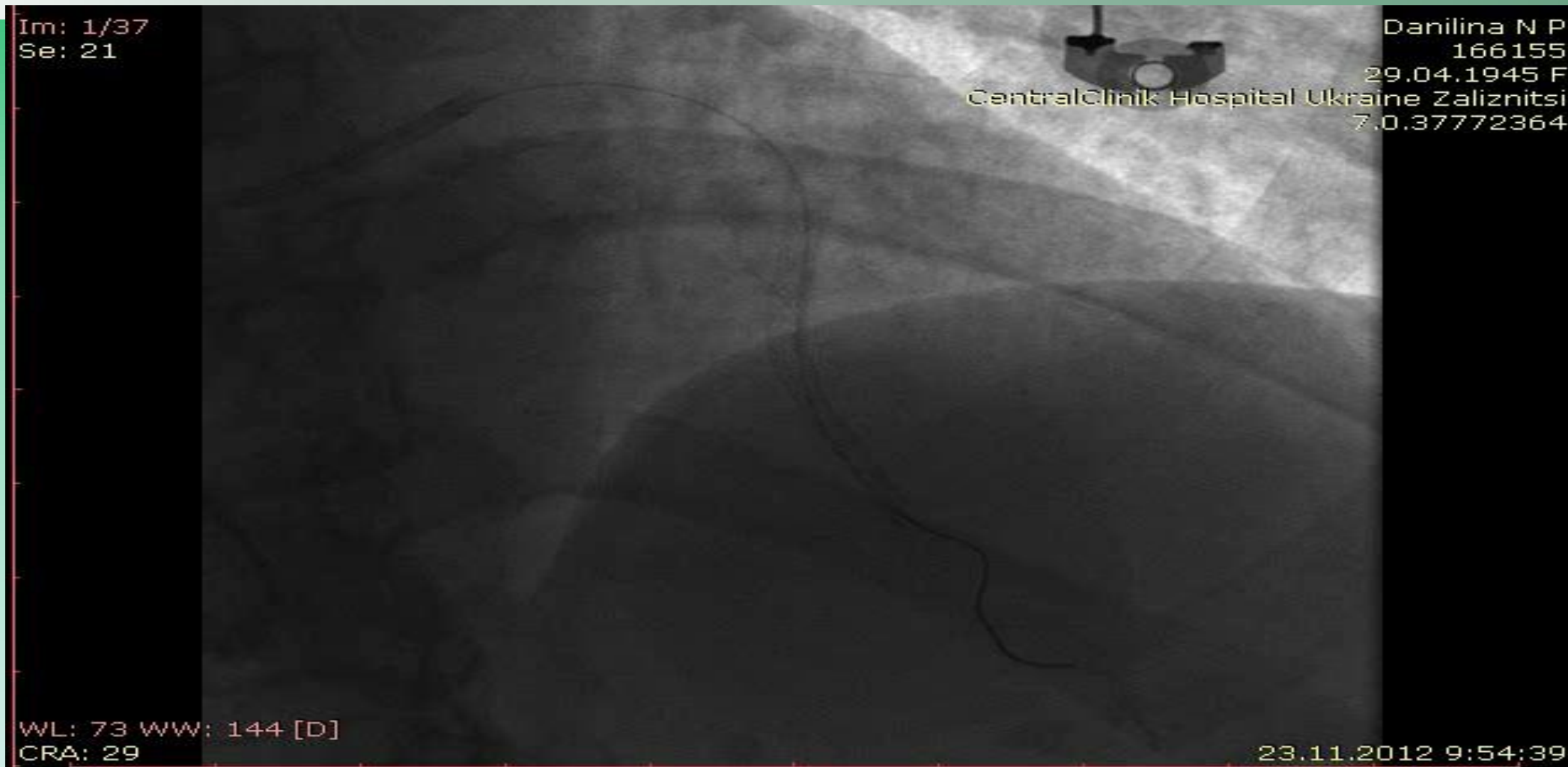
Treadmill after stenting(Maximum exertion)



Treadmill test was negative. No complaint of angina



Coronary Angiography after Stenting



- Blood pressure was unstable after stent



Treatment after stent

- ✓ ecvator 20/10mg in the morning
- ✓ physiotens 0.4mg in the evening
- ✓ Amlodipine 5mg in the evening
- ✓ Krestor 40mg in the evening
- ✓ Plaviks 75mg



- Drug recommendation after stenting
 - ✓ ecvator 20/10mg in the morning,
 - ✓ bisoprolol 5mg daily,
 - ✓ roksera 20mg daily,
 - ✓ physiotens 0.4mg in the evening
 - ✓ Amlodipine 5mg in the evening
 - ✓ Krestor 40mg in the evening
 - ✓ Plaviks 75mg



Thank you



